ANIL AGGRAWAL'S
Internet Journal of Forensic Medicine and Toxicology
The world's first online journal devoted entirely to forensic medicine and toxicology · Published 1 January and 1 July

VOL. 22, NO. 1 · JANUARY – JUNE 2021
Downloaded from www.anilaggrawal.com · ISSN 0972-8074 (Online) · https://www.anilaggrawal.com/ij/vol_022_no_001/papers/paper001.html

Self Draped Saree – A Ligature Material.

Nitin S Barmate[1*], R. K. Singh[2], Prerna Sahare(Barmate)[3]

[1]Assistant professor, Forensic Medicine, Pt. J N M Medical College, Raipur, Chhattisgarh
[2]Professor and Head, Forensic Medicine, Pt. J N M Medical College, Raipur, Chhattisgarh
[3]Dental Surgeon, New Horizon Dental College, Bilaspur India

* Corresponding author: Nitin S Barmate, Assistant professor, Forensic Medicine, Pt. J N M Medical College, Raipur, Chhattisgarh, India 492001 · nitinsforensic@gmail.com

CITE THIS ARTICLE

Barmate NS, Singh RK, Sahare P. Self Draped Saree – A Ligature Material.. *Anil Aggrawal's Internet Journal of Forensic Medicine and Toxicology* [serial online], 2021; Vol. 22, No. 1 (January – June 2021): [about 10 p]. Available from: https://www.anilaggrawal.com/ij/vol_022_no_001/papers/paper001.html

Introduction

Hanging is a form of violent asphyxial death. It produces painless death for the victims so that it is a widely accepted method of suicide. The rate of suicidal hanging cases is increasing day by day. Hanging is a mechanical form of asphyxia which is caused by suspension of body by a ligature which encircle the neck, the constricting force being the weight of body.[1]

The usual material utilized for committing the act were those that were readily available nearby which includes rope and cloth based materials like saree, dhoti, lungi etc.[2].

A saree is a South Asian female garment that is typically wrapped around the waist. There are more than 80 recorded ways to wear a sari.[3]. But till date not single case reported in literature as best of our knowledge in which the person committed suicidal hanging by saree as ligature material which was worn by person itself. Herein we report such case.

Case

History

A 28year female committed suicidal hanging in her home by saree. Her socioeconomic status was poor and lower strata. She had history of love marriage with family conflict. Her dead body was found suspended to the ceiling hook (point of suspension) in her home in an early morning of the day of incident.

Autopsy findings

On the same day of incident the deceased was brought for medicolegal autopsy at our hospital. The victim was dressed with black color flower design saree, black blouse, white bra, black petticoat, black underwear. Black color flower design saree which was worn by deceased used as ligature material(Fig-1) used for hanging, had running knot at right side of neck beneath mastoid tip(Fig-2).

On external examination- The deceased was average built with well developed rigor mortis in the whole body. Gloves and stoking type of postmortem lividty and fixed. Nail bed cyanosed. Ligature mark obliquely present around neck, brownish, parchmentised.

On internal examination – No bony injuries were seen. Brain oedematous with multiple petechae. Lung congested and oedematous with petechae. Heart contain dar fluid blood. Other visceral organs congested and were unremarkable. Stomach contained about 80 ml of brownish fluid having no abnormal smell perceived, mucosa normal. Toxicological analysis was negative for any poisonous or inebriant substance. Histopatholgical examination of neck tissue revel constriction band necrosis in muscle and intimal tear of carotid artery.

Discussion

The deceased was young adult female of 28years old in the present case, maximum percentage of violent asphyxial death found in age group 21-30 yrs account for 45.94%. As it is the most active period in one's life and there are great fluctuations of emotions in this age group. Young people get frustration due to various reasons such as unemployment, family acceptance, poverty and love failure etc so most of the cases were in this age group. All these causes form the motivational factors to terminate their lives.[1] According to National crime record beuro incidence of suicide during year 2013 was 11 per one lakh population of which family problem responsible for 24%, love affairs account for 3.3% and poverty leads to 1.4%. of suicidal death.[4] In the present case deceased had love marriage with poor financial and socioeconomic condition with frequent family conflict.

On the basis of the suspension of body, complete hanging was seen in 67.7% cases and partial (incomplete) hanging in 32.3% cases. However, depending on the position of knot, typical hanging was noted in only 10.2% hanging and atypical in 89.8% cases.[5]

In the present case, there was partial (incomplete) hanging in which body suspended on ceiling hook with toes rest on the stool.

Most of the times, the ligature material is not available during the forensic examination of hanging. Either it was brought separately along with the body or sent later on for the examination if required by the investigating officer. The relatives tried to rescue the victim by removing the ligature around the neck. Hence, the ligature material was usually not examined; and its features are not submitted for systematic analysis. But, the ligature material, type and position of knot play an important role in the mechanism of death and autopsy findings in hanging. According to Ambade et al nylon rope was the commonest type of ligature material used for hanging in 63% cases followed by odhni (10.2%), and sari account for 5.5% of cases.[5]**.** But in all previous literature saree was used as separate ligature material beside wearing apparel.

Saree is South Asian female garment, consist of a drape varying in length and breadth, typically wrapped around the waist, with one end draped over the shoulder baring the midriff. There are

more than 80 recorded ways to wear saee.[3] In the present case the deceased person worn black color flower design saree, which was wrapped around waist and one end draped over the shoulder which form loop around neck with running (slip) knot beneath right mastoid tip(Fig-2) and free portion of draped end of saree suspend over ceiling hook as a point of suspension. Ambade et al found in 24.4% of cases knot situated on right side of neck (left mastoid)[5].

The hanging mark usually being single and lying above the thyroid cartilage has been reported in many literature.[5] We found single hanging ligature mark above the thyroid cartilage. Likewise most of the literature, we found tissue under ligature mark were dry, white and glistening, other visceral organs congested with dark fluidity of blood. Hyoid bone and thyroid cartilage intact.[6] Histopathological examination of neck tissue revel constriction band necrosis in muscle (Fig-3) with intimal tear in carotid artery (Fig-4). Histo-pathological examination findings of skin and carotid artery indicated vital Reactions signifying ante-mortem hanging. Compression of skin layers and disruption of intima of carotid artery signifies the effect of pressure on the layers of carotid artery by the ligature material during the act of hanging.[2]





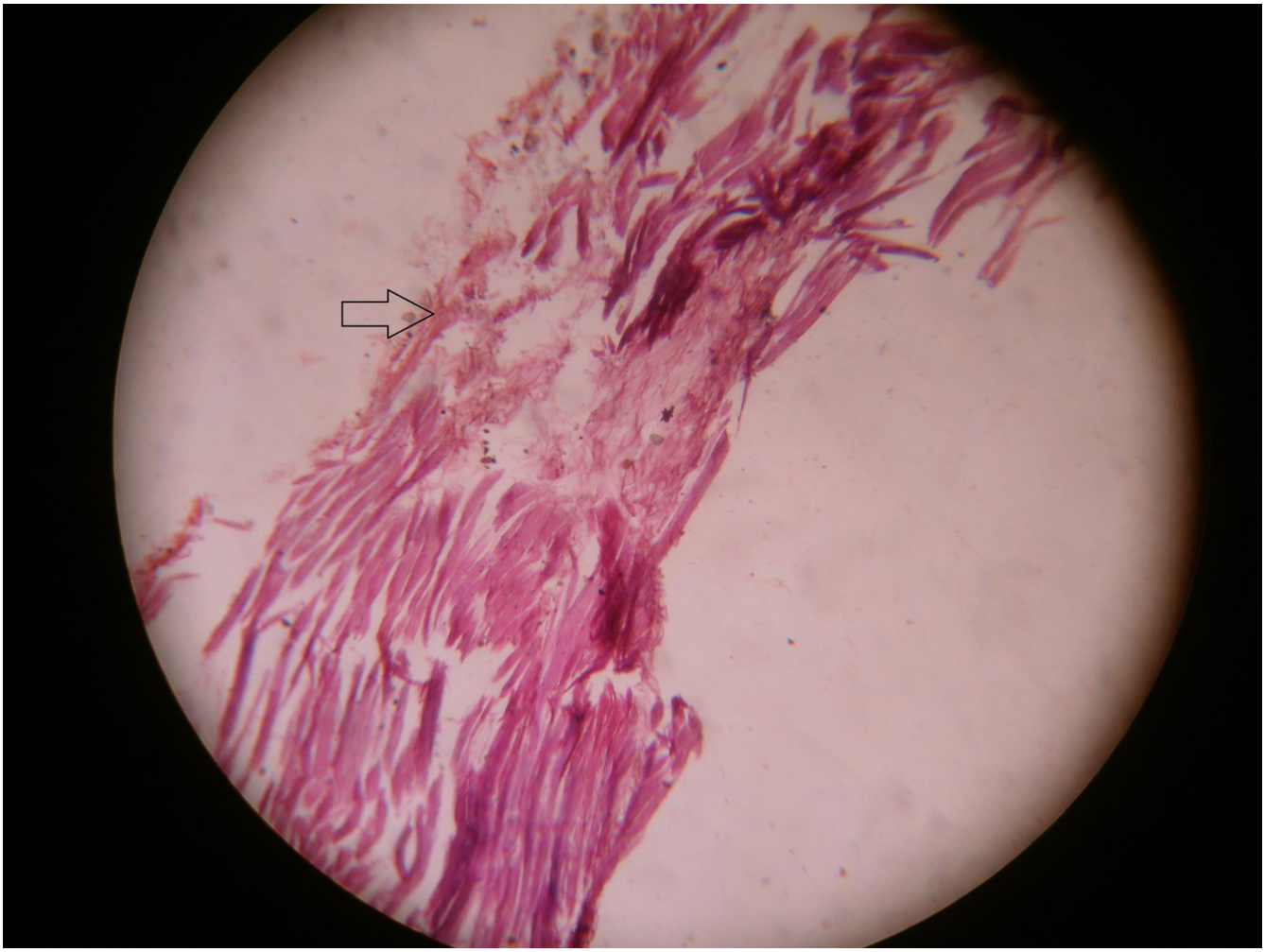

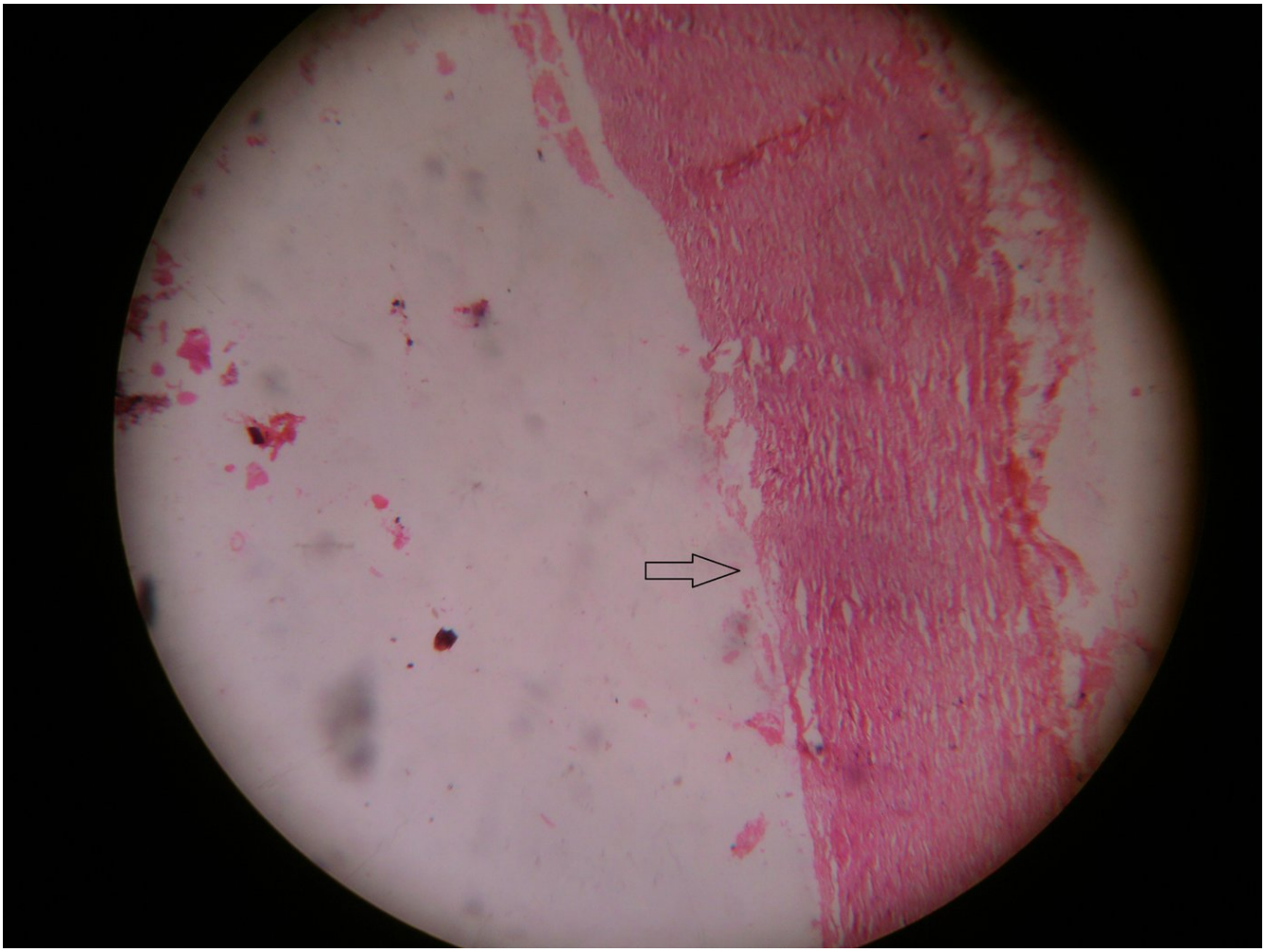

References

1. Mohammed Ziyauddin G Saiyed, Kamesh A Modi. Retrospective Study of Postmortem Cases of 'Hanging – A Method Of Suicide' NHL Journal of Medical Sciences/July 2013/Vol.2/Issue 2.
2. Ashok Kumar Samanta, Soumya Ranjan Nayak. Original Research Paper Newer Trends in Hanging Death. Indian Acad Forensic Med. Jan- March 2012, Vol. 34, No. 1 ISSN 0971-0973 37.
3. Wikipedia. en.wikipedia.org/wiki/Sari
4. National Crime Records Bureau Ministry of Home Affairs Government of India. Web site- http://ncrb.gov.in
5. Vipul Namdeorao Ambade, Nilesh Tumram, Satin Meshram, Jaydeo Borkar Ligature material in hanging deaths: The neglected area in forensic examination Egyptian Journal of Forensic Sciences (2014)
6. Krishan Vij. Text Book Of Forensic Medicine And Toxicology. 4th Edition; 2008; 162 - 168