ANIL AGGRAWAL'S
Internet Journal of Forensic Medicine and Toxicology
The world's first online journal devoted entirely to forensic medicine and toxicology · Published 1 January and 1 July

VOL. 22, NO. 1 · JANUARY – JUNE 2021
Downloaded from www.anilaggrawal.com · ISSN 0972-8074 (Online) · https://www.anilaggrawal.com/ij/vol_022_no_001/others/editorial.html

Forensic Odontology: Its Role And Application In Human Identification

Gurpreet Singh

Aesthetic Dental Surgeon, F-5/3 Model Town-II, Delhi-110009, India

Contact: Gurpreet Singh · drgurpreetsingh7@gmail.com

CITE THIS ARTICLE

Singh G. Forensic Odontology: Its Role And Application In Human Identification. *Anil Aggrawal's Internet Journal of Forensic Medicine and Toxicology* [serial online], 2021; Vol. 22, No. 1 (January – June 2021): []. Available from: https://www.anilaggrawal.com/ij/vol_022_no_001/others/editorial.html

Introduction

Our society is faced with new challenges everyday in every area possible. Crime still exists in all aspects of our daily lives in spite of advancement in modern technology and medical breakthroughs. Aggressive and horrific activities occur daily that ruin the lives of victims, their families and friends. Although little can be done to repair such irreversible and incalculable damage, it is vital to maintain law and order through apprehension and subsequent prosecution of the perpetrators. Forensic Odontology / Forensic Dentistry plays an important role in this process by providing scientific methods and techniques to assist in identification of victims related to crime or accident.[1] Dentists need to be cognizant of the importance of maintaining current, accurate, specific, detailed and legible dental records for their use in application of Forensic Dentistry, thereby giving assistance to crime investigation team for obtaining criminal justice and related law enforcement objectives such as arresting fugitives, locating and identifying missing persons, locating and returning stolen property.[2] There is an extensive documented history of ways dental records have proven to be crucial in identifying victims of criminal acts or murder investigations (to convict murderers), mass fatalities, missing persons or situations wherein victim's body was burnt, mutilated or decomposed grossly disabling facial / visual recognition by their family or friends.[2,3]

Historical Account on Forensic Odontology

The first forensic dentist in the United States was Paul Revere who was known for the identification of Dr. Joseph Warren who suffered a severe head trauma and died during the war of Bunker Hill in 1775. This was considered the first case of identification by a dentist and was presented as a case by Luntz L and Luntz P in 1972. His body was buried in a mass grave by the British army. When British

forces were gone a year after that incident, the people of Massachusetts (Boston) wanted to give a proper burial to Dr. Warren but they could not identify his body as all the bodies in that mass grave had decomposed completely. Later it was identified by the small ivory denture that Paul Revere had designed for him during his life. Through this identification, it was made possible for Dr. Warren to be buried properly with full military honours.[4]

The countess of Salisbury was burnt at Hatfield house in 1835 and her body was charred beyond recognition. Therefore, she could not be identified visually. Later on, she was identified by her gold denture that was recovered from the site.[5]

Dr. George Parkman was a respected professor at Harvard University who also dealt with real estate and lending money. John Webster, a colleague of his at Harvard, was a chemist and owed Dr. Parkman a considerable amount of money. Dr. Parkman failed to return home one evening from dinner on November 23, 1849. John Webster's laboratory was searched and a tea chest was found that contained human remains. In the furnace, the maxillary jaw fragments were discovered. At the trial of John Webster, Dr. Nathan Cooley Keep, Dr. Parkman's dentist, identified the teeth as part of the maxillary and mandibular dentures that he fabricated three years ago for the victim when he was alive. This was the first time dental evidence was used and accepted by law to convict a murderer.[2]

After the shooting of President Abraham Lincoln on April 14, 1865, John Wilkes Booth escaped and hid in a barn on a farm in Virginia. The United States Cavalry found him there on April 26, 1865 and burned the barn. He came out of the barn because of fire and was shot dead. However, a rumor was there that Mr. Booth had escaped. Therefore, the body was dug up in 1893 and inspected to determine if it was John Wilkes Booth. The body could not be identified visually by the family, but the family dentist was able to recognize it through his work as well as a distinctive formation of the jaw he had recorded in his dental notes during J.W. Booth's dental visit for the restoration of his tooth.[2]

The first case of dental identification in a mass disaster according to Dr. Oscar Amoedo, regarded as the Father of Forensic Odontology, was the one which occurred in Paris in 1897 in which a huge number of people lost their lives. A fire had broken out in a charity bazaar which led to 126 casualties. Antemortem dental notes were compared with postmortem dental notes for identification of the dead bodies in this case.[6]

Adolf Hitler and his wife Eva Braun had died together in 1945 and their bodies were burned and buried by Russian soldiers. However, after World War II got over, there were rumors that he had escaped with his wife. It was a challenge to dismiss the rumors that they were still alive due to lack of any antemortem and postmortem records. Eventually, fragments of Hitler's mandible were recovered that revealed remnants of a bridge as well as characteristic forms of reconstruction to the mandible with evidence of periodontal disease. His identity was determined when the work matched the dental charts maintained by his dentist, Hugo Johannes Blaschke.[2]

An English author, Michael Eddowes, began raising suspicion some years after the assassination of John F. Kennedy regarding the identification of Lee Harvey Oswald, the assassin. He believed the body buried in 1963 in Oswald's grave was a Russian spy. Therefore, to correct this misapprehension, the body was disinterred and positive identification of Oswald was made on October 4, 1981 with military antemortem dental notes.[2]

Numerous people lost their lives in the terrorist attack on world trade center in the U.S. on September 11, 2001. Many victims could not be identified visually since the building collapsed crushing their bodies. DNA extracts from toothbrushes of the victims were utilized in identification of some victims.[7]

Significance of Victim's Identity Determination

The verification and confirmation of a victim's identity is required for a number of reasons **(Table 1)**. One of the most important reasons is bringing closure to the immediate family members when tragic or unexpected events occur. Another reason is for legal settlements of property where a death certificate is required which is issued on a confirmation of identity.[2] Apart from this, civilized societies, specifically, realize the need for identity, both during life and at death. Lastly, the living family members have responsibilities for their dead family member (the victim) and need to perform their last rites and rituals.[8]

Table 1: Common Reasons for Identification of Discovered Human Remains.

Criminal	**Positive identification of a victim of a criminal death is a prerequisite for the beginning of a criminal investigation.**
Marriage	Remarriage is not permitted in many religious backgrounds unless the spouse is confirmed dead.
Monetary	Payment of pensions, life insurance and other benefits in victim's name depends upon positive scientific identification and confirmation of death of the victim
Burial	A positive identification and proof of religion is necessary in many religions for the burial in burial grounds.
Closure	Identification of individuals missing for a long time is essential in bringing peace and closure to close family members.

Significance of Dental Identification in Determining Victim's Identity

Dental identification has a significant role in the identification of discovered remains in several different situations, wherein the bodies of the victims are injured and damaged to such an extent that identification by a family member is neither reliable nor desirable, such as violent crimes (where the dead body is mutilated, decomposed, burned, dismembered, or skeletonized), fires, motor vehicle accidents and work place accidents.[1,2] Individuals who have been dead for some time before getting discovered and those extracted from water also pose great challenges as the sight is distressing and their faces or bodies are beyond recognition making visual identification impossible. Identification through recovered dental remains has always proven to be essential in mass tragedies (both natural and man-made), especially the mass fatalities usually associated with aircraft accidents, wherein postmortem changes and traumatic tissue injury occur, thus making facial identification difficult. Dental identification is indispensable in cases where there is no fingerprint database / record, thereby nullifying the use of fingerprinted evidence. Various dental identification techniques are applied in verifying victim's identity in these kind of situations since dental tissues are resilient and persist due to their ability to tolerate extremely high temperatures, humidity and pressure. Therefore, identification through dental evidence is considered one of the most dependable, durable and reliable methods of identification.[2,3]

Durability and Reliability of Dental Evidence in Identity Determination

Dental identifications comprise a considerable percentage of all identifications.[8] For instance, in Lockerbie air crash, identification of up to 90% of all individuals who had died was done through odontological identifications.[9] Dental evidence proves to be reliable since almost everyone has teeth, and those who do not have them usually wear a dental prosthesis and moreover, the possibility of someone having a fingerprint record in the fingerprint database is very low. Even though usual non-restored teeth and their morphology are unique between individuals, the dental treatment procedures like restorations, extractions, implants and prosthesis performed on the dentition render it highly unique.[10] Postmortem dental remains with the presence of dental treatment on them suggest that an antemortem dental record of such treatment exists, which therefore can be located and found, provided the victim's attendance to their dentists was regular as well as the methods of noting and recording the dental treatment procedures performed on the victim were neat and meticulous. However, this is not always the case as even in the antemortem dental records absence, the teeth act as vital reservoirs of information that can be used to put together a postmortem profile of the deceased, highlighting their important aspects, such as age, sex, race and occupation.[1,8] The reason for durability of the dental evidence is the postmortem survival of the human dentition.[8] As enamel is the hardest structure in the human body, it acts as a protective shield to teeth, thereby minimizing the effects of fire, chemical attack, submersion, burial or even severe head and neck trauma, and making the dentition resilient and long-lasting. This defensive armour provided by the enamel and dentine also serves to preserve the molecular information present within the dentinal tubules, pulp and vasculature of the tooth, which can serve to be significant sources of DNA when bone and deep muscle are not suitable or available. Furthermore, dental tissues can be stabilized in cases of severe incineration by applying transparent nail varnish or hair lacquer until they can be assessed in the mortuary. Sometimes, trying to extract the teeth from other postmortem human remains leads to their fracture leaving only the roots, which are also richer sources of data that can be utilized in the dental identification of a deceased.[1,8,10]

Role of Forensic Odontologists

The most common role of the forensic odontologist is the dental identification of deceased victims, which can be done using two main methods. Firstly, the most commonly applied method is a *comparative dental identification,* wherein identification is done through comparison of recovered features from an unknown body (postmortem data) with known features of a missing individual (antemortem data) and the result is used to demonstrate that the remains of a decedent and a person represented by antemortem data are the same individual. Information from the victim's body and circumstantial evidence normally point to hints as to who has died, which in turn help in tracing the victim's antemortem records.[11,12,13] Secondly, a *postmortem dental profiling* is done by the forensic odontologist in cases where antemortem notes are absent, and no hints to the possible identity of the decedent exist. In this method; features of the deceased, such as their oral anatomical structures, dental restorations and dental appliances, are proposed that help in shrinking the search pool and streamlining the search for locating and finding the antemortem data. Therefore, the more the information or features are recorded from the postmortem examination, the greater the likelihood of succeeding in verifying and confirming the identity of the decedent.[2,11,12]

Methods and Techniques Applied in Forensic Odontology to Determine Victim's Identity

Forensic Odontology starts with dental professionals, therefore it is imperative that they document information in the antemortem dental record / patient's dental chart clearly, correctly, and specifically using universal abbreviations wherever and whenever needed along with detailed description about the treatment procedures conducted on patients. An individual's dentition changes throughout life and the combination of decayed, restored and missing teeth is measurable and comparable at any fixed point in time. Therefore, accurate dental charting and quality oral radiographs are the first and foremost steps in providing a positive identification.[2]

The methods and techniques applied in forensic odontology for victim's dental identification are:

- *Comparative Dental Identification* (most common)
- *Postmortem Dental Profiling* (most common)
- *Facial Superimposition*
- *DNA - Deoxyribonucleic Acid*

Comparative Dental Identification

The teeth not only act as a suitable repository of distinctive and characteristic identifying features, but they can also withstand most postmortem assaults that can disfigure, disrupt or change other body tissues (skin, muscles, bones etc.).[1,8] Based on this, the main principle of this method of odontological identification is that the dental features or data obtained from *postmortem dental remains* (of an unknown person) are compared to *antemortem dental data* (of a known person); that is their dental charts (including written notes, study casts, radiographs, photographs, and details about treatments performed and communication that occurred in the clinic between the patient and the dentist) **(Fig. 1)**. Circumstantial evidence and details from the victim's body normally give some useful pointers on who has died, thereby helping in tracing the victim's antemortem dental records. Therefore, the identity of the unknown decedent can be confirmed through this examination.[8] Comparison between both the dental records is done under three main categories; the teeth, periodontal tissues, and anatomical features **(Table 2)**. Understandably, identification of individuals with numerous and complex dental treatments is usually convenient and straightforward than those with little or no dental / restorative treatment.[8,14]

DENTAL STATUS OF MISSING PERSON

Date :

Name :	Age :	D.O.B.	M/F
Address : Previous Address :		Dentist School Clinic Hospital	
Occupation :			
Police Reference :		Reference F/O :	

11			21
12			22
13			23
14			24
15			25
16			26
17			27
18			28

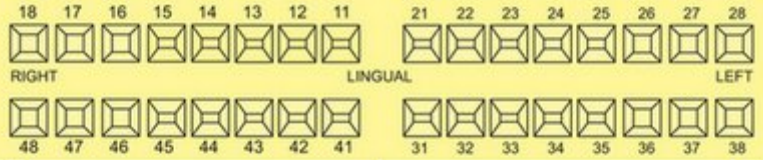

48			38
47			37
46			36
45			35
44			34
43			33
42			32
41			31

Occlusion :		Crowns :		Bridges :	Smoker
DENTURES : P/U F/U P/L F/L MAXILLOFACIAL PROSTHESIS : IMPLANTS :		Material : Marks :	TEETH : CLASPS :	Type : Mould : Shade : Type :	
RADIOGRAPHS : Bw. Pa : Occ. Lat. AP OPG PHOTOGRAPHS : Clinical Portrait					
SPECIAL TREATMENT	Endo.	Perio	Ortho.	Oral Surgery	C. & B.

(form 1)


ANTEMORTEM DENTAL RECORD

NAME: FROST, JACK, R SSN: 333-33-3333 RANK: LT, USN

SEX: M RACE: C AGE: 31 XRAY TYPE & DATE: B/W 10/97 Pano 01/96

EXAMINERS: A.B. SMITH, CAPT, DC, USN P.T. BOATE, CDR, DC, USN

DATE RECONSTRUCTED: 12 DEC 97

RECORD SUPPLIED BY: NDC PENSACOLA FL

RESTORATIONS & MISSING TEETH

DESCRIPTION/COMPUTER CODES

1. U
2. OL-AM, F-AM
3. MO-AM, DO-AM
4. PN
5. O.O-AM
6. F-CO
7. M-CO
8. L-IR, RF
9. CV
10. MI-CO
11. D-AM
12. PN
13. FP-CV, RF-AP
14. FP-X
15. FP-CF
16. X
17. U
18. MODL-C
19. MOD-AM
20. MO-AM
21. DO-AM
22. ML-CO
23. PN
24. CT-RF
25. PN
26. PN
27. PN
28. DOFL-GI
29. RP-X
30. RP-X
31. RP-X
32. MOFL-GI

AM	AMALGAM	CF	CROWN FULL
GI	GOLD INLAY	CP	CROWN PARTIAL
GF	GOLD FOIL	CV	CROWN VENEER
SS	ANY OTHER METAL REST	FP	FIXED PARTIAL
CO	COMPOSITE RESIN	RP	REMOVABLE PARTIAL
JM	JAW FRAGMENT MISSING	CD	COMPETE DENTURE
TA	TRAUMATIC AVULSION	M	MESIAL
FX	FRACTURED CROWN	D	DISTAL
RT	ROOT TIP	O	OCCLUSAL
PN	PRESENT NOT RESTORED	I	INCISAL
RO	ROTATED	F	FACIAL
RF	ROOT CANAL FILLING	L	LINGUAL
AP	APICOECTOMY	C	CARIES
IR	INTERMEDIATE REST	U	UNERUPTED
CT	CROWN TEMPORARY	X	EXTRACTED

REMARKS: BILATERAL MANDIBULAR TORI

Fig. 1: Examples of Antemortem Dental Chart / Odontogram

After a crime or an accident is reported, a request for odontological identification is initiated by the police on recovering postmortem human dental remains. Many a time, a putative identification is handy in the form of a circumstantial evidence, such as a wallet or a driving licence that may be recovered at the site of the crime or accident or found on the body, or the body may be found in a residence, and this permits antemortem data to be located. In other cases, the geographical region or area in which the body is discovered and other physical elements may validate a presumptive identification to be made. Antemortem dental data are then procured from the victim's dentist of record.[1,8] This is achieved through a process wherein a letter of authority is issued by the police that is presented by the police officer to the dentist, which then legalizes the dentist to release

antemortem dental records of the suspected individual (the victim), thereby obliging him / her to serve the police in the identification of one of their patients.[8]

The forensic odontologist prepares the postmortem dental notes by thoroughly charting and writing descriptions of the dental structures, radiographs, restorations and dental appliances of the unknown decedent **(Fig. 2)**. Therefore, to ensure the best possibility of a successful comparison between postmortem and antemortem notes, it is extremely vital to evaluate and document the postmortem data accurately in a detailed fashion. If the antemortem notes are available at the time when the forensic odontologist prepares the postmortem notes, then postmortem radiographs should be taken in such a fashion that they replicate the type and angle of antemortem radiographs that were taken during the victim's life when he/she visited his/her dentist for the treatment. Radiographs should be punched out with a rubber dam punch for one and two holes to mark them as antemortem and postmortem x-rays respectively to prevent confusion.[12]

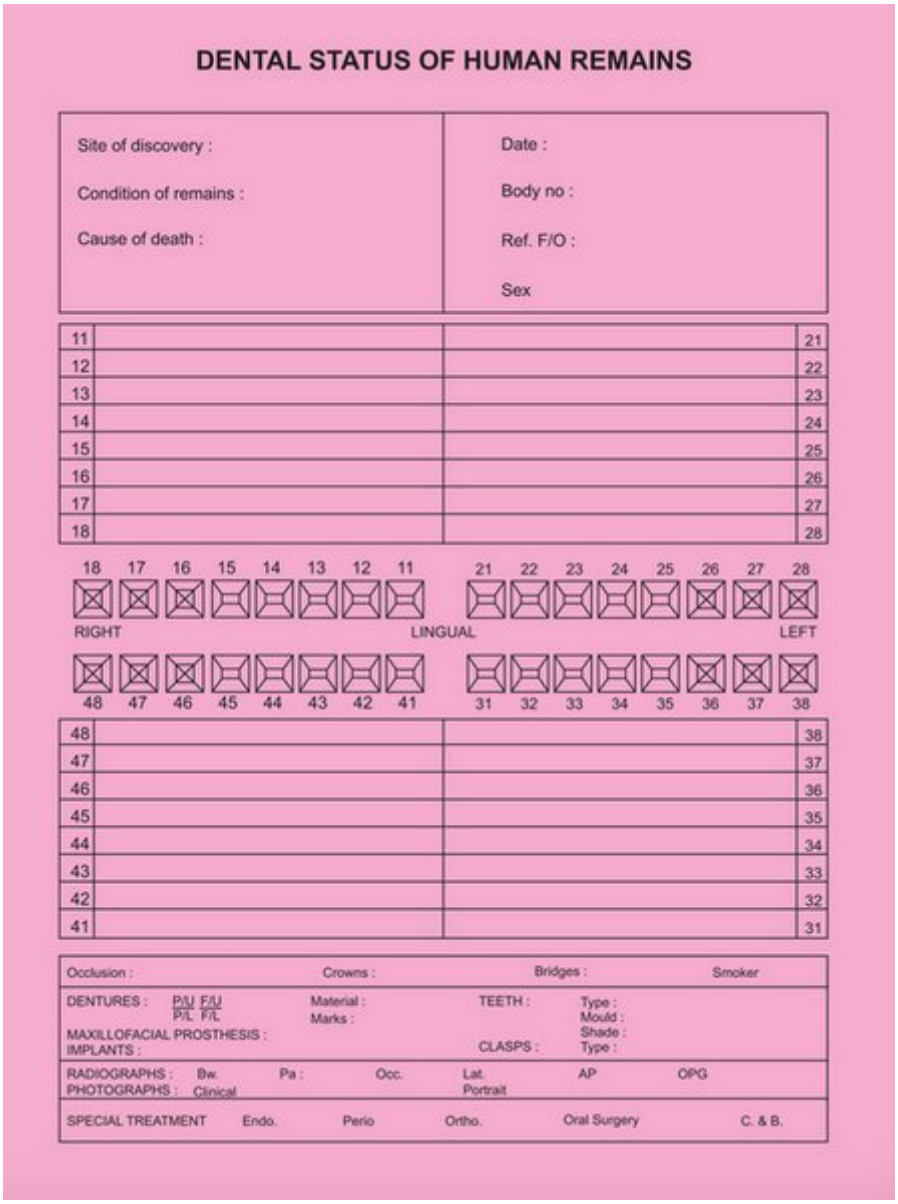

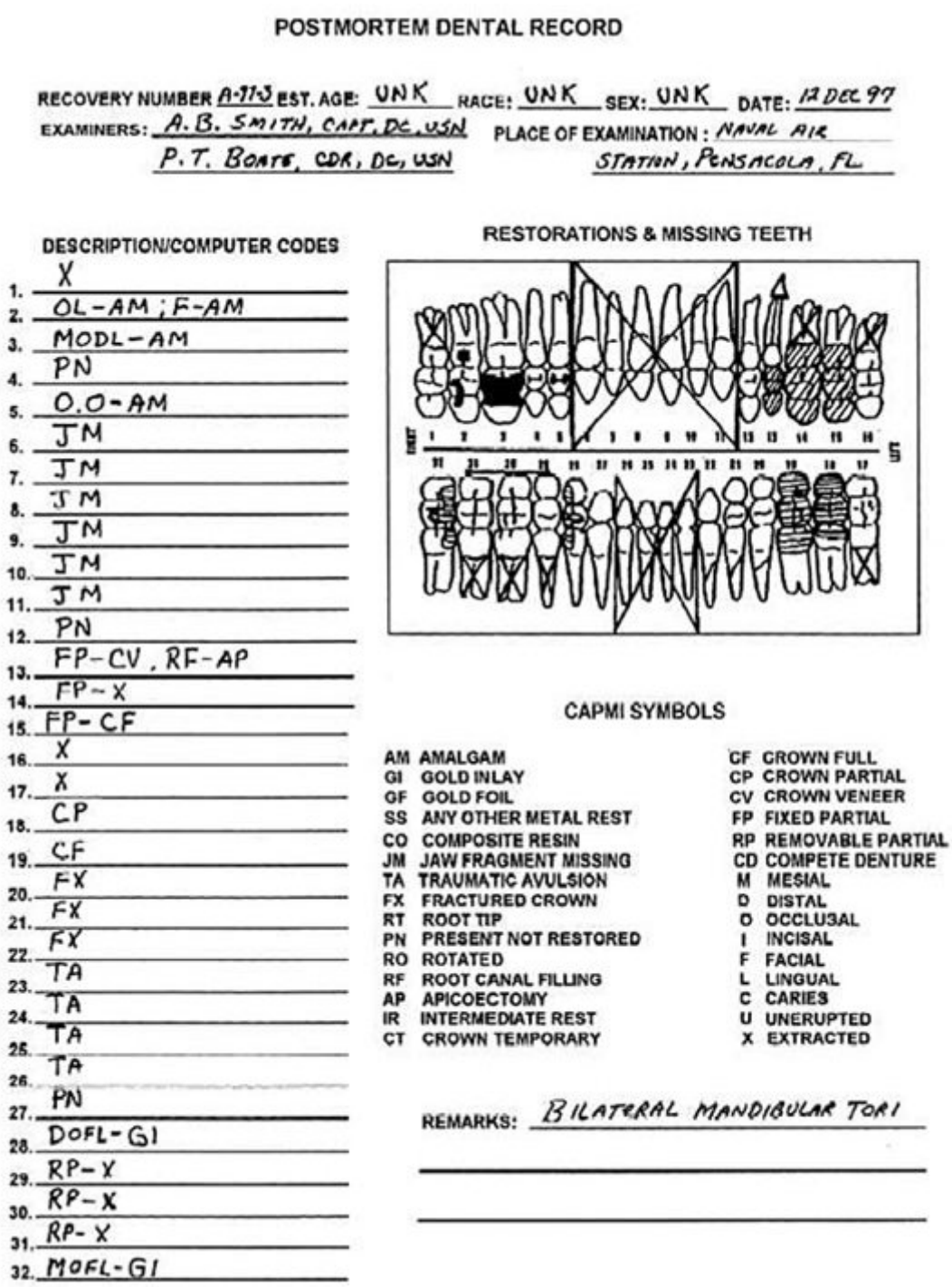
POSTMORTEM DENTAL RECORD

RECOVERY NUMBER A-11-3 EST. AGE: UNK RACE: UNK SEX: UNK DATE: 12 DEC 97

EXAMINERS: A. B. SMITH, CAPT, DC, USN P. T. BOATE, CDR, DC, USN

PLACE OF EXAMINATION: NAVAL AIR STATION, PENSACOLA, FL

DESCRIPTION/COMPUTER CODES

1. X
2. OL-AM ; F-AM
3. MODL-AM
4. PN
5. O.O-AM
6. JM
7. JM
8. JM
9. JM
10. JM
11. JM
12. PN
13. FP-CV , RF-AP
14. FP-X
15. FP-CF
16. X
17. X
18. CP
19. CF
20. FX
21. FX
22. FX
23. TA
24. TA
25. TA
26. TA
27. PN
28. DOFL-GI
29. RP-X
30. RP-X
31. RP-X
32. MOFL-GI

RESTORATIONS & MISSING TEETH

CAPMI SYMBOLS

AM	AMALGAM	CF	CROWN FULL
GI	GOLD INLAY	CP	CROWN PARTIAL
GF	GOLD FOIL	CV	CROWN VENEER
SS	ANY OTHER METAL REST	FP	FIXED PARTIAL
CO	COMPOSITE RESIN	RP	REMOVABLE PARTIAL
JM	JAW FRAGMENT MISSING	CD	COMPETE DENTURE
TA	TRAUMATIC AVULSION	M	MESIAL
FX	FRACTURED CROWN	D	DISTAL
RT	ROOT TIP	O	OCCLUSAL
PN	PRESENT NOT RESTORED	I	INCISAL
RO	ROTATED	F	FACIAL
RF	ROOT CANAL FILLING	L	LINGUAL
AP	APICOECTOMY	C	CARIES
IR	INTERMEDIATE REST	U	UNERUPTED
CT	CROWN TEMPORARY	X	EXTRACTED

REMARKS: BILATERAL MANDIBULAR TORI

Fig. 2: Examples of Postmortem Dental Chart / Odontogram

The things that are essential for a successful postmortem documentation are; *photographs* (digital or film based) which provide the ability to view specific features without having to review the body, *radiographs* (usually a full mouth series to replicate the regions of interest), and a *complete dental record* for postmortem and antemortem comparison.[2]

A comparative examination, which is methodical and systematic, between the two records is conducted to confirm the identity of the unknown victim once the postmortem data is documented. For instance, the comparison of postmortem and antemortem radiographs is carried out wherein each tooth and its surrounding structures are evaluated and assessed assiduously. The pattern,

shapes and sizes of individual dental treatments present in one dental record are compared with similar features, traits and characteristics in the other dental record. Although there are some discrepancies present in this, these are explainable on the basis of the time that elapsed as well as the additional dental treatments performed between examination of both the records **(Fig. 3)**. The dental restorations or other dental treatments recorded in the postmortem data hold significant relevance in the identification process as they can be compared and matched easily with the information contained in the antemortem data. Besides this, many other oral tissues and morphological features are also evaluated and assessed **(Table 2)** during the comparison that play a highly instrumental role, especially in those victims who either have lower number of restorations or no dental treatments at all. If the antemortem data contain study casts of any kind, then an impression of the victim's jaws should be taken in the mortuary so that these may be compared.[1,8]

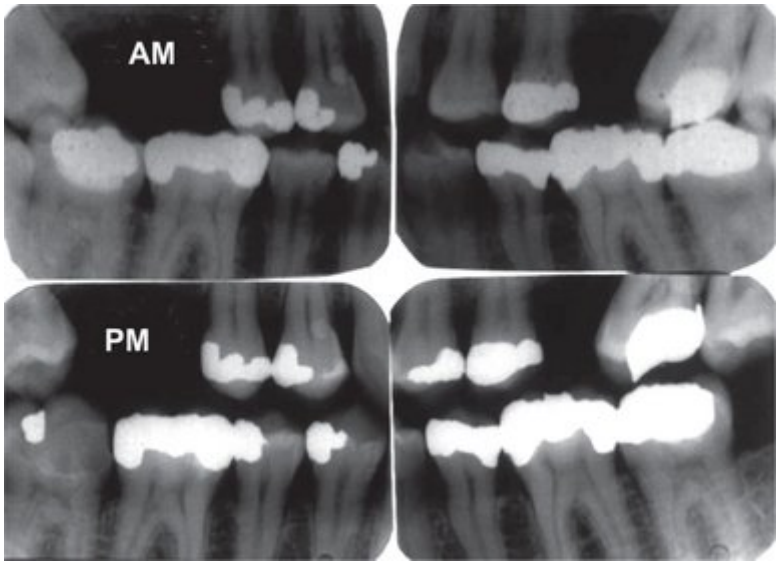

Fig. 3: Comparison between Antemortem (AM) and Postmortem (PM) bitewing radiographs.

The top two images (AM) are taken some years before death and illustrate upper and lower right (quadrants 1 and 4), and upper and lower left (quadrants 2 and 3) regions. The bottom two radiographs were shot intentionally to replicate angulations of the AM radiographs. There are differences between AM and PM radiographs with respect to number of restorations, however that can be explained on account of additional treatment the patient must have had received in the interval between AM and PM analysis. Several explainable discrepancies that exist in the above image are: (i) A restoration has been dislodged and fractured in tooth 47 (lower right 2nd molar) in PM radiograph, possibly due to trauma around the time of death; (ii) the difference in tooth 24 (upper left first premolar) is due to a restoration that must have been performed on the patient several years after the AM radiograph was taken but before the death of the same patient.

Table 2: Oral features examined during the Comparative Dental Identification. (Pretty, 2001)[1]

Teeth

Teeth present
a. Erupted
b. Unerupted
c. Impacted

Missing teeth
a. Congenitally
b. Lost antemortem
c. Lost postmortem

Tooth type
a. Permanent
b. Deciduous
c. Mixed
d. Retained primary
e. Supernumerary

Tooth position
a. Malposition

Crown morphology
a. Size and shape
b. Enamel thickness
c. Contact points
d. Racial variations

Crown pathology
a. Caries
b. Attrition, abrasion, erosion
c. Atypical variations, enamel pearls, peg laterals, etc.
d. Dentigerous cyst

Root morphology
a. Size
b. Shape
c. Number
d. Divergence of roots

Root morphology
a. Dilaceration
b. Root fracture
c. Hypercementosis
d. Root resorption
e. Root hemisections

Pulp chamber/root canal morphology
a. Size, shape and number
b. Secondary dentine

Pulp chamber/root canal morphology
a. Pulp stones, dystrophic calcification
b. Root canal therapy
c. Retrofills
d. Apicectomy

Periapical pathology
a. Abscess, granuloma or cysts
b. Cementomas
c. Condensing osteitis

Dental restorations
1. Metallic
a. Non-full coverage
b. Full coverage
2. Non-metallic
a. Non-full coverage
b. Laminates
c. Full coverage
3. Dental implants
4. Bridges
5. Partial and full removable prosthesis

Periodontal tissues

Gingival morphology and pathology
a. Contour, recession, focal/diffuse, enlargements, Interproximal craters
b. Colour –inflammatory changes, physiological (racial) or pathological pigmentations
c. Plaque and calculus deposits

Periodontal ligament morphology and pathology
a. Thickness
b. Widening
c. Lateral periodontal cysts and similar

Alveolar process and lamina dura
a. Height, contour, density of crestal bone
b. Thickness of interradicular bone
c. Exostoses, tori
d. Pattern of lamina dura
e. Bone loss (horizontal/vertical)
f. Trabecular bone pattern and bone islands
g. Residual root fragments

Anatomical features

Maxillary sinus
a. Size, shape, cysts
b. Foreign bodies, fistula
c. Relationship to teeth

Anterior nasal spine
a. Incisive canal (size, shape, cyst)
b. Median palatal suture

Mandibular canal
a. Mental foramen
b. Diameter, anomalous
c. Relationship to adjacent structures

Coronoid and condylar processes
a. Size and shape
b. Pathology

Temperomandibular joint
a. Size, shape
b. Hypertrophy/atrophy
c. Ankylosis, fracture
d. Arthritic changes

Other pathologies
a. Developmental cysts
b. Salivary gland pathology
c. Reactive / neoplastic
d. Metabolic bone disease
e. Focal or diffuse radiopacities
f. Evidence of surgery
g. Trauma – wires, surgical pins etc.

Since the discrepancies are inevitable and do exist in the comparison between the two records, they as well as the similarities must be noted down during the process. There are two types of discrepancies; those that are explainable and those that are not. Explainable differences are often associated with the time interval that is present between the fabrication of antemortem and postmortem notes, that is, when the victim was alive and when he/she dies **(Fig. 3)**. For instance, removal of teeth or placement of restorations or expansion of a restoration (a mesio-occlusal; MO amalgam filling involving two surfaces expanded into a mesio-occlusal-distal; MOD amalgam filling involving three surfaces). However, if a discrepancy is unexplainable, such as when a tooth is absent on the antemortem dental note and present on the postmortem dental note or when a mesio-occlusal-distal (MOD) amalgam (in antemortem records) is now a mesio-occlusal (MO) amalgam (in postmortem records), then an exclusion is made.[15] Therefore, it is extremely crucial to

take charting errors or incorrectly orientated radiographic films into account when such 'unexplainable discrepancies' are reviewed.[8]

Several inferences can be drawn from the comparative data obtained on the basis of which conclusions can be made while outlining a dental identification. The *American Board of Forensic Odontology (ABFO)* endorses that these be restricted to the following four conclusions:[16]

• *Positive identification*: when the antemortem and postmortem dental records match in sufficient detail, with no unexplainable differences, to demonstrate that they are from the same individual.

• *Possible identification*: when the antemortem dental records are consistent with the postmortem dental records, however it is not possible to establish a positive identification with certainty, owing to the poor quality of either the postmortem dental remains or the antemortem dental evidence.

• *Insufficient evidence*: when the information obtained from the antemortem and postmortem dental records are inadequate and therefore not sufficient to draw any conclusion.

• *Exclusion*: when the information obtained from the antemortem and postmortem dental records do not match and are therefore vividly inconsistent.

One important thing to be kept in mind while drawing inferences and conclusions is that there are no defined set of minimum number of features or concordant points that are required to match to make a positive identification. For instance, a single tooth with sufficient distinct characteristics may be of huge help in demonstrating a positive identification in many cases, whereas in others, a series of full mouth radiographs may not be of any use if they do not disclose sufficient information.[16] The discretion of identification lies with the forensic dentist who must be ready to justify the conclusions that he has drawn in court.[1]

Postmortem Dental Profiling

When the tentative identity of the victim is not available or comparative and other methods of identification are insufficient or unavailable or not possible, the forensic odontologist can help in shrinking the population pool to which the victim probably belongs, thereby narrowing down the search and increasing the chances of locating antemortem dental records, which in turn, aid in establishing the identity of the victim. This process is known as postmortem dental profiling.[1]

This method is employed in situations wherein the body of the victim cannot be recognized, such as when it is grossly degraded, decomposed, mutilated, disfigured or only skeletal remains are left in locations that are not related to their place of residence.[13]

A postmortem dental profile provides a valuable information about the victim, such as their race, sex, age, occupation, dietary habits, habitual behaviours, socio-economic status, and dental or systemic diseases, through careful inspection and examination of the victim or their postmortem human remains at the site of disaster.[1,7]

Race: The ancestry background or race can be determined to some extent through skull appearance; shape and form of the skull along with some additional dental features like cusps of Carabelli, shovel-shaped incisors and multi-cusped premolars. Forensic odontologists can categorize the unknown individual into one out of three major racial groups from these features: Caucasoid, Mongoloid and Negroid **(Table 3)**.[1]

Table 3: Dental features indicating a particular Race / Ancestral background

Race / Ancestral Background	Dental Feature
Negroid and Caucasoid	Incisors: Chisel/Blade
Mongoloid	Shovel-shaped incisors (scoop shaped) **[Fig. 4]**
Mongoloid	Premolar: Occlusal enamel tubercle/pearl
Caucasoid	Maxillary molar Carabelli Cusp (on mesio-palatal aspect of the first maxillary molar) **[Fig. 5]**
Mongoloid, Native American	Supernumerary distolingual root (third root on mandibular molars)
Negroid	Fourth molars (distal to third molar) **[Fig. 6]**
Caucasoid	Macrodonts (Central Incisors)

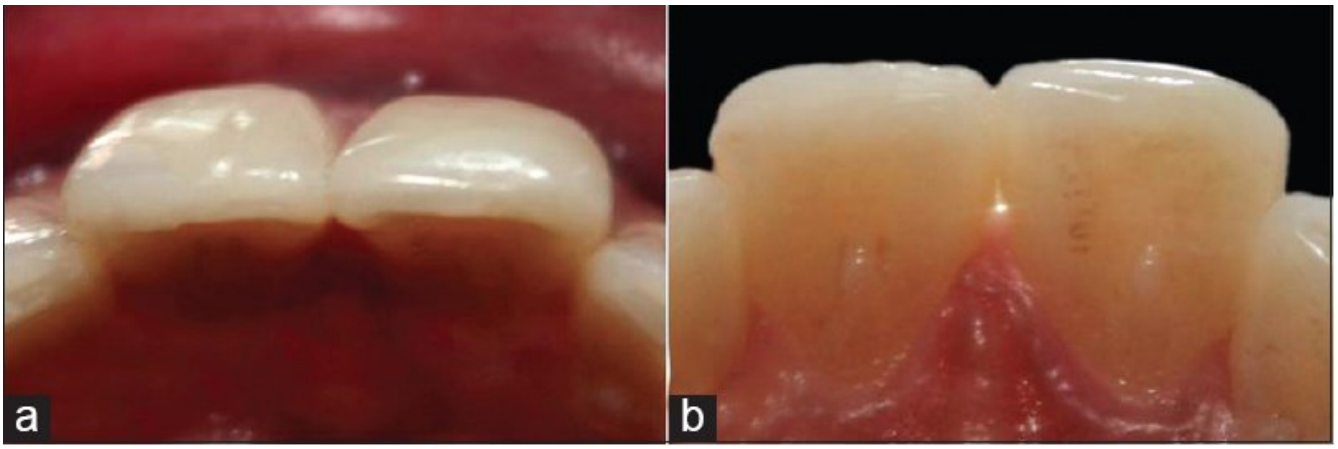

Fig. 4: Mongoloid: *Incisal shoveling in maxillary central incisors*

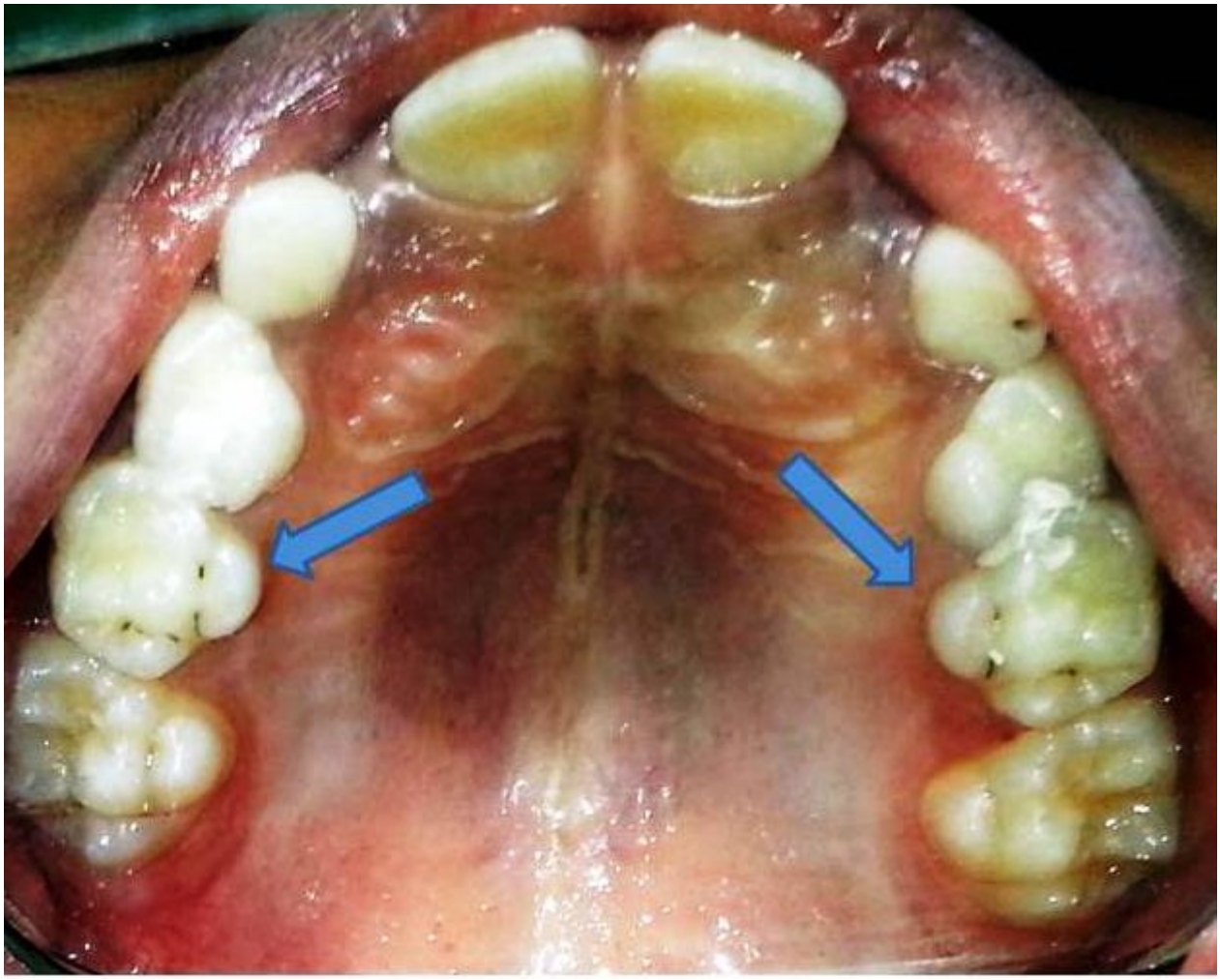

Fig. 5: Caucasoid: *Cusp of Carabelli on mesio-palatal cusp of Maxillary First Molar*



Fig. 6: Negroid: *The presence of fourth molar (distally to third molar)*

Sex: Sex of the deceased can be usually found out through diligent examination of the cranium and its appearance, as no sex differences are can be pointed out through the teeth morphology. Microscopic examination of teeth for the presence or absence of Y-chromatin and DNA analysis can also help in determining sex.[1]

Age: Individual's age can be confirmed through careful examination of teeth and its surrounding structures since dental structures can prove to be useful markers of the individual's chronological age. The development of dentition follows a consistent developmental sequence of teeth starting from 4 months in utero until the emergence of third molars, which is around second to third decade of life. Therefore, careful analysis of tooth development and subsequent comparison with developmental charts can help in finding out the age of children including foetuses and neonates. Results are usually established with an accuracy of ± 1.5 years to the actual chronological age of the child through this method. Developmental Charts such as those made by Ubelaker demonstrate the dentition development graphically from 5 months in utero to 35 years after birth, showing the deciduous, mixed and permanent dentitions.[1,12,17]

When determining sub-adult ages, eruption dates of the teeth are highly variable and therefore in this case, it is vital to note that the actual developmental stages of the teeth are more accurate. Some forensic odontologists use third molar development to determine the age of young adults, although accuracy of this technique can be questioned due to variability of these teeth development and eruption. Those who recommend third molar use claim an age accuracy of ± 4 years, however the range of age should be within 16 – 22 years only.[18,19]

Middle-aged and older adults are difficult to identify. Progression of periodontal disease, highly worn out surfaces, multiple and complex restorations, extractions, bone pathosis may suggest an older individual. Accuracy is in the range of ±10–12 years utilizing these highly-variable markers.[1]

Visual age assessment can sometimes be misleading and should not be relied upon, based on aspects such as worn out tooth surfaces, therefore in cases like these, dentine translucency has shown to be beneficial. Dentine becomes sclerotic or translucent with age due to rise in mineral content within it. This process begins at the tooth apex and spreads coronally throughout life. Therefore, age can be determined by measuring the thickness of translucent dentine.[20,21] However, some factors like, racial origin and difficulty in determining the boundary between sclerotic and non-sclerotic dentine, need to be taken into account while applying this method as these can influence the accuracy of ageing.[22]

Some forensic odontologists recommend the use of aspartic acid racemization method for age determination, claiming an accuracy of ±4 years.[23] Other methods include the use of SEM-EDXA, a technique which includes dentine examination in relation to age determination. Examination of root length of developing permanent tooth can also be used for estimating age in paediatric cases.[24]

Occupation and Dietary Habits: Most occupational hazards can lead to the dental hard tissues loss or staining of tooth. Occupational loss of tooth substance can take place through three main mechanisms – abrasion, erosion and by caries or tooth decay.[13]

Abrasion of tooth structure is most frequently found in individuals working in dusty or particulate environments or factories, such as flour millers, miners, stone grinders, saw mill workers and cement workers due to the grinding of teeth onto hard abrasive dusty particles. This kind of tooth loss is most commonly found on the biting surfaces (occlusal and incisal) of the teeth. So this information can prove to be vital and may help in the identification, if a factory of this type is located in the vicinity of the area where the body of the unknown victim is found.[13]

Erosions with smooth polished surfaces can occur most frequently on labial aspects of teeth in individuals like chemical workers or battery factory workers, involving use of chemical acids, due to their continuous exposure to acidic fumes leading to decalcification of enamel and dentine. It can also occur due to many other reasons such as excessive alcohol intake, excessive consumption of carbonated beverages or eating disorders like anorexia nervosa or bulimia nervosa. Some habits like aggressive mastication or tooth brushing or using a tooth brush with hard bristles can also lead to loss of tooth substance.[7,13]

Caries on the labial and buccal surfaces of the teeth are seen most commonly in individuals such as sugar refiners, bakers or candy makers due to deposition of sugar dust onto labial or buccal surfaces of the teeth.[13]

Staining on teeth may point to smoking, use of tetracycline, betel nut and chewing of smokeless tobacco or even dental fluorosis as well. The colour of the stains can tell us volumes about the kind of factory the individual used to work in or the activities they used to indulge themselves in. For instance, individual working in copper and nickel metal factory will show green staining of their teeth, iron metal workers will demonstrate fine black lines on their teeth, tin metal workers will suggest yellow staining on their dentition, individuals working in battery factories will show yellow or gold-brown stains on labial aspects of their teeth due to exposure to cadmium. All this happens due to inhalation of dust and fumes of metal, which in turn leads to their deposition on the teeth, thereby causing extrinsic staining. Coffee, tea, red wine drinkers will present themselves with brown or black staining on labial, lingual and palatal surfaces of their teeth, and betel nut chewers show red to black stains on buccal surfaces of their dentition unilaterally. All this occurs due to extrinsic staining.[7,13] So this information can prove to be crucial in the identification, if a factory of

this type is located in the vicinity of the area where the body of the unknown victim with stained teeth is found.

Habitual Behaviour: Incisal edge notching (single or multiple) may indicate habitual placement of nails in between the teeth which is usually done by carpenters and cobblers, opening of bobby pins, cutting of threads or holding needles between teeth by tailors or it may occur because of positioning pipe stems, cigarette holders, hair pins etc. between the teeth. The dentition with unusual wear pattern may demonstrate previous orthodontic treatment as well.[25]

Socio-economic status: The dental treatment presence or absence, which gives knowledge on the attitude and dental awareness of an individual, furthermore the quality and quantity of dental treatment, such as type of restoration, prostheses or appliance, may give a useful pointer to the socio-economic status as well as region or country of residence of the individual.[26]

Dental or Systemic Diseases: Some systemic diseases like *hiatus hernia, gastric ulcers and gastro-esophageal reflux disease (GERD)* can cause marked erosion of the palatal surfaces of the maxillary incisors and premolars due to regurgitation or vomiting of gastric contents, especially gastric acid. Teeth affected by *Congenital porphyria* present a pinkish-brown discoloration that fluoresces red under UV light. It is an autosomal recessive disease caused by circulating porphyrins in the blood that are deposited in the dental hard tissues, hence the discolouration. A classic pathognomonic sign of Hutchinson's incisors or Mulberry molars can aid in confirming *Congenital Syphilis* which is caused due to *Treponema pallidum.*[13]

Therefore, in a nutshell, a forensic odontologist in postmortem dental profiling looks for all the possible methods and examines the tiniest of details to shortlist the identity of the unknown victim, thereby authorizing search for the antemortem notes / records.

Facial Superimposition

If the postmortem dental profiling fails to draw out the tentative identity of the decedent, then it is of primary importance to reproduce and reconstruct the appearance of the individual during life when they were alive. This aids in identification and is done by the forensic artists with the help of the dental profile. The goal of reconstructing the face and its features is achieved by utilizing suitable antemortem photographs (one with full face and the other showing lateral profile) of the individual showing teeth and then superimposing these photographs on skeletal or teeth fractures of the victim, to allow facial approximation.[8,27]

However, the approximation of a photographic face (antemortem photograph) over a skull (victim's postmortem profile) can usually lead to an image that shows 'consistency' based on the commonality of skeletal structures. Therefore, it is necessary that angulation difficulties and magnification are taken into account in order to lower the possibility of false positives.[28]

DNA - Deoxyribonucleic Acid

This method is used when the body of the victim is burnt, degraded or decomposed and no tissues like bone or muscle (which are traditional sources of DNA) are left, except the teeth. The teeth persist due to ability of their resilient hard tissues (enamel and dentine) to withstand environmental insults, such as immersion, trauma, mutilation, incineration and decomposition, and ensure that they constitute an excellent reservoir of DNA material. Therefore, when conventional methods of dental identification fail, this biological method can be applied to provide the essential connection of the victim to crime scenes to prove the identity of the deceased.[29,30]

The DNA can be extracted from teeth through cryogenic grinding method (useful in both; normal tooth with pulp as well as root canal treated tooth without pulp tissue) and then amplified through PCR (Polymerase Chain Reaction). This DNA then can be compared to the DNA obtained from the antemortem samples of the suspected individual, such as hairbrush, toothbrush, clothing, blood sample, cervical smear or any other personal belonging of the individual or to the DNA of their parent or siblings.[29,31,32]

The genomic DNA of the unknown victim can be obtained from the nucleus of cells of the calcified dental tissues i.e. enamel (ameloblasts) and dentine (odontoblasts). When this DNA cannot be examined (because of its degradation) or is inadequate to establish any conclusion about the identity of the victim, then mitochondrial DNA (mtDNA) can be utilized, which is maternally inherited and is present in high concentration in each cell due to high number of mitochondria in most cells. This mtDNA can be derived from dentine powder and can prove to be beneficial (especially in cases where antemortem samples of the suspected individual are not available for comparison) owing to its maternal inheritance pattern that can confer the same mitochondrial DNA sequence upon the siblings of the suspected individual, which then can be compared to the mitochondrial DNA sequence of the victim.[29,31,33]

Other Novel and Innovative methods / techniques used in dental identification

In many situations, some other novel methods / techniques of forensic odontology, apart from the most commonly utilized comparative dental identification or postmortem dental profiling, are applied for dental identification. These newer methods can easily aid in tracking down the victim's dentist or securing their antemortem dental notes and thereby limiting the population pool for searching the identity of the deceased.[7] These methods consist of:

Labelled Prosthesis: The prosthesis such as dentures or dental appliances like removable orthodontic appliances or braces can be labelled with patient's name alone or along with their other details such as social security number, unique ID number or driving licence number. This can be done either by marking their full name on a substrate such as paper or metal and sealing it in the surface of the denture through various processes or by engraving them onto the appliance. This can prove to be extremely significant in cases of identifying the victim of a mass disaster or the one caught in accidental fire. Therefore, the concerned dental authorities across the globe should insist that dentists get their patients identity marked or labelled in their respective prosthesis or appliances.[10,34,35,36]

Dental Techniques and Materials: Tentative estimation can be made about the place of residence, dentist or dental clinic, based on the techniques used in dental treatment, the quality of dental work and dental materials that have been used to treat the victim's dentition. Dental techniques and the materials available to perform them vary widely, and are usually influenced by the affluence of the country. Moreover, dental training is also highly variable, and in many countries there is little or no formal dental training. Therefore, an assumption can be made about the country or geographical region in which the individual had gotten their dental treatment. For instance, dentistry in Russia can often be recognized by the use of non-precious metals along with acrylic instead of porcelain crowns. Non-precious metals usage on the anterior teeth is considered a substandard quality work in the West. It is imperative to note that good or poor quality of dental treatment and shoddy dental techniques can be performed in any country. However, unusual dental work or gross departures from the normal should always be considered potentially

significant since this may indicate the possibility that either the individual may belong to or have spent time in a foreign country where they might have gotten that kind of dental treatment performed on them.[13] Therefore, all this can assist in achieving the final goal of establishing the identity of the unknown individual.

Palatal Rugae: Palatal rugae are asymmetric and irregular ridges on the anterior part of the palatal mucosa behind the incisive papilla, on each side of the mid-palatine raphae. These are well protected by the lips, cheek, tongue, buccal pad of fat and teeth in incidents of fire, and high-impact trauma and can also resist decomposition to an extent. Rugae pattern, like teeth, are considered unique to an individual and rarely transform shape with age, and reappear after trauma or surgical procedures. Therefore, this method of examining the *palatal rugae pattern*, which can be straight, curved, wavy, circular, branched, unified, cross-linked, annular or papillary, is useful in identifying *edentulous* individuals **(Fig. 7)**. The rugae pattern on the victim's maxilla or maxillary denture may be compared to old dentures that may be recovered from the victim's residence, or maxillary cast / plaster models that may be available with their treating dentist.[37]

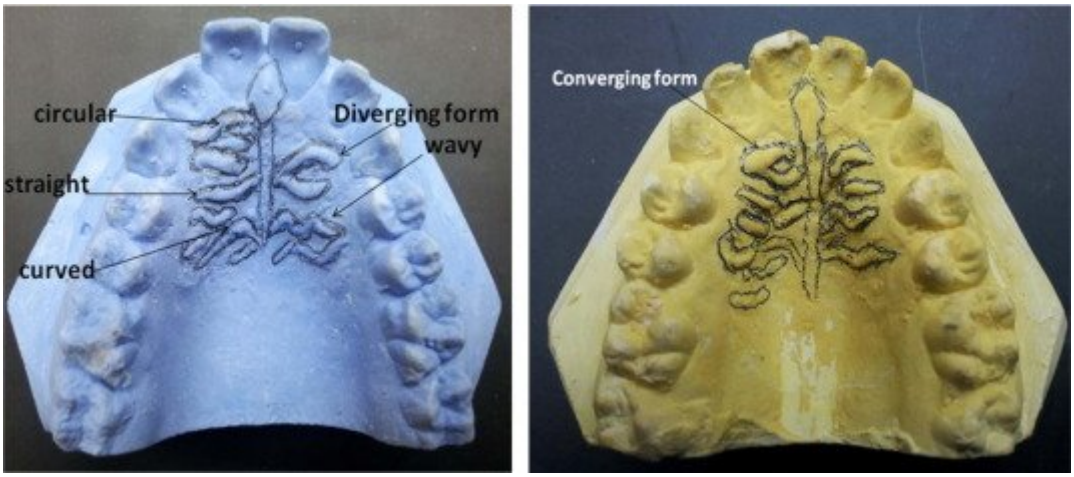

Fig. 7: Palatal Rugae patterns

Conclusion

Forensic Odontology has played a key role throughout history in identifying individuals who cannot be recognized visually and when all the other forensic measures have failed. Along with circumstantial evidence, it can help in locating antemortem notes and providing important information for forensic artists' utilization, thereby aiding in identifying unknown individuals or confirming the identity of victims of a mass disaster or an accident, such as earthquakes, flood, cyclones, epidemic diseases, terrorist acts, wars, railway and aviation accidents. Apart from catastrophic tragedies, this branch of dentistry also assists in identifying decomposed or charred bodies which are far beyond recognition as well as solving medico-legal cases to obtain criminal justice.[13,38] This article describes the importance and durability of dental evidence in determining the identity of an individual, especially in cases of traumatic tissue injury and lack of fingerprint records which preclude the utilization of visual and fingerprint matching methods of identification respectively.[17] Forensic odontologists can help in shrinking the pool of search, thereby providing a more focused, more efficient and expeditious process of establishing the positive identification through the use of conventional as well as other supplemental novel and innovative techniques.[8] Various such methods and techniques have been described in this article comprehensively that can

be employed for postmortem identification. The distinct characteristics of the dental anatomy, the kind of restorations along with correct and precise application of these techniques can ensure accuracy. Forensic odontologists hold a key responsibility since scientific confirmation is required for identification.[7,8,13] It is of utmost importance that dentists keep quality records of each patient and maintain past dental records meticulously to play a key role in forensic sciences. Furthermore, forensic dentists must note everything, even the minuscule details of oral cavity while performing an extraoral and intraoral examination. This information will prove to be crucial to victim's identification or an investigation of a crime. Therefore, all dental professionals do take part and play a major role in one way or another in forensic odontology.[2]

References

1. Pretty IA, Sweet D. A look at forensic dentistry – Part 1: The role of teeth in the determination of human identity. Br Dent J 2001; 190(7): 359–366.
2. www.dentalcare.com/en-us/professional-education/ce-courses/ce401/toc - Forensic Dentistry
3. Waleed P, Baba F, Alsulami S, Tarakji B. Importance of Dental Records in Forensic Dental Identification. Acta Inform Med 2015 Feb; 23(1): 49–52.
4. Devore DT. Radiology and photography in forensic dentistry. Dent Clin North Am 1977; 21: 69-84.
5. Fixot RH. How to become involved in forensic odontology. Dent Clin North Am 2001; 45: 417-26.
6. Barsley RE. Forensic and legal issues in oral diagnosis. Dent Clin North Am 1993; 37: 133-56.
7. Shekar BRC, Reddy CVK. Role of dentist in person identification. Indian J Dent Res 2009; 20(3): 356-360.
8. Pretty IA. Forensic dentistry: 1. Identification of human remains. Dent Update 2007 Dec; 34(10): 621-634.
9. Moody GH, Busuttil A. Identification in the Lockerbie air disaster. Am J Forensic Med Pathol 1994; 15(1): 63–69.
10. Marella GL, Rossi P. An approach to person identification by means of dental prostheses in a burnt corpse. J Forensic Odontostomatol 1999; 17(1): 16–19.
11. Jones D G. Odontology often is final piece to grim puzzle. J Calif Dent Assoc 1998; 26: 650- 651.
12. Sweet D, DiZinno J A. Personal identification through dental evidence-tooth fragments to DNA. J Calif Dent Assoc 1996; 24: 35-42.
13. Pramod JB, Marya A, Sharma V. Role of forensic odontologist in post mortem person identification. Dent Res J (Isfahan) 2012 Sep-Oct; 9(5): 522–530.
14. Tohnak S, Mehnert AJ, Mahoney M, et al. Synthesizing dental radiographs for human identification. J Dent Res 2007; Nov; 86(11): 1057-62.
15. McGivney J, Fixott RH. Computer-assisted dental identification. Dent Clin North Am 2001; 45(2): 309–325.
16. American Board of Forensic Odontology. Body identification guidelines. J Am Dent Assoc 1994; 125: 1244-1254.
17. Kumaraswamy J, Naidu J, Nagarajachar RB, Reddy MBS. Truth from untruth: Dental pulp and its role in forensic odontology – A Retrospective Review. Int J Forensic Odontol 2017; 2(1): 30-33.
18. Mincer H H, Harris F, Berryman H E. The ABFO study of third-molar development and its use as an estimator of chronological age. J Forensic Sci 1993; 38: 379-390.
19. Hongwei S, Jingtao J, Cameron J M. Age determination of the molars. Med Sci Law 1991; 31: 65-68.

20. Lorentsen M, Solheim T. Age assessment based on translucent dentine. J Forensic Odontostomatol 1989; 7(2): 3–9.
21. Maat GJ. Diet and age-at-death determinations from molar attrition. A review related to the low countries. J Forensic Odontostomatol 2001; 19(1): 18–21.
22. Whittaker DK, Bakri MM. Racial variations in the extent of tooth root translucency in ageing individuals. Arch Oral Biol 1996; 41(1): 15–19.
23. Ogino T, Ogino H, Nagy B. Application of aspartic acid racemization to forensic odontology: post mortem designation of age at death. Forensic Sci Int 1985; 29: 259-267.
24. Liversidge H M, Molleson T I. Developing permanent tooth length as an estimate of age. J Forensic Sci 1999; 44: 917-920.
25. Gupta B N. Occupational diseases of teeth. J Soc Occup Med 1990; 40: 149-152.
26. Maupome G, MacEntee M I. Prosthodontic profiles relating to economic status, social network, and social support in an elderly population living independently in Canada. J Prosthet Dent 1998; 80: 598-604.
27. Austin-Smith D, Maples WR. The reliability of skull / photograph superimposition in individual identification. J Forensic Sci 1994; 39(2): 446–455.
28. Dorion RB. Photographic superimposition. J Forensic Sci 1983; 28(3): 724–734.
29. Sweet D, Hildebrand D. Recovery of DNA from human teeth by cryogenic grinding. J Forensic Sci 1998; 43(6): 1199–1202.
30. Sweet DJ, Sweet CH. DNA analysis of dental pulp to link incinerated remains of homicide victim to crime scene. J Forensic Sci 1995; 40(2): 310–314.
31. Shiroma CY, Fielding CG, Lewis JA, Jr, Gleisner MR, Dunn KN. A minimally destructive technique for sampling dentin powder for mitochondrial DNA testing. J Forensic Sci 2004; 49(4): 791–795.
32. Sweet D, Hildebrand D, Phillips D. Identification of a skeleton using DNA from teeth and a PAP smear. J Forensic Sci 1999; 44(3): 630–633.
33. Hutchison C A, Newbold J E, Potter S S, Edgell M H. Maternal inheritance of mammalian mitochondrial DNA. Nature 1980; 251: 536-538.
34. Borrman H I, DiZinno J A, Wasen J, Rene N. On denture marking. J Forensic Odontostomatol 1999; 17: 20-26.
35. Whittaker D K. A Colour Atlas of Forensic Dentistry. Saint-Louis: Harcourt, 1989.
36. Gosavi S, Gosavi S. Forensic Odontology: A prosthodontic view. J Forensic Dent Sci 2012; 4(1): 38-41.
37. www. pocketdentistry.com/21-forensic-odontology.
38. Shanbhag VL. Significance of Dental Records in Personal Identification in Forensic Sciences. J Forensic Sci Med 2016; 2(1): 39-43.