ANIL AGGRAWAL'S
Internet Journal of Forensic Medicine and Toxicology
The world's first online journal devoted entirely to forensic medicine and toxicology · Published 1 January and 1 July

VOL. 15, NO. 2 · JULY – DECEMBER 2014
Downloaded from www.anilaggrawal.com · ISSN 0972-8074 (Online) · https://www.anilaggrawal.com/ij/vol_015_no_002/papers/paper001.html

Histological changes in the Retina in Methanol Toxicity - A case report

Monisha Pradhan[1*], Bajrang K Singh[1], C Behera[2], Garudadhri G V[3], Seema Rao[4]

[1]Assistant Professor, Department of Forensic Medicine, Maulana Azad Medical College, New Delhi-110002, India
[2]Associate Professor, Department of Forensic Medicine, Maulana Azad Medical College, New Delhi-110002, India
[3]Junior Resident, Department of Forensic Medicine, Maulana Azad Medical College, New Delhi-110002, India
[4]Assistant Professor, Department of Pathology, Maulana Azad Medical College, New Delhi-110002, India
Contact: Monisha Pradhan · monishapr@yahoo.com

CITE THIS ARTICLE

Pradhan M, Singh BK, Behera C, Garudhri GV, Rao S. Histological changes in the Retina in Methanol Toxicity - A case report. *Anil Aggrawal's Internet Journal of Forensic Medicine and Toxicology* [serial online], 2014; Vol. 15, No. 2 (July – December 2014): [about 6 p]. Available from: https://www.anilaggrawal.com/ij/vol_015_no_002/papers/paper001.html

ABSTRACT

The tragedies associated with consumption of spurious liquor adulterated with methanol is not uncommon in our country and keeps making headlines time and again. We present a case of methanol ingestion in a 45 year old male resulting in haemorrhage of basal ganglia and pons and toxic changes in optic nerve and retina at autopsy. We have discussed about the various effects of methanol toxicity and histological changes in the retina.

Keywords: Methanol toxicity, Retina, Brain haemorrhage

Introduction

Methanol is a colourless liquid with faint spirituous odour and a burning taste. It is a component of many household products like antifreeze, paint removers, windshield washer fluid, various solvents and cleaners. Also, in developing countries it is a cheap alternative to ethanol hence adulteration of alcohol with methanol is quite common. Therefore, poisoning can be due to accidental or suicidal ingestion. Methanol ingestion has been associated with intra cerebral haemorrhages and visual disturbances due to retro-bulbar neuritis. These effects of methanol are caused by the metabolic products of methanol like formaldehyde and formic acid. At autopsy the gross findings are generally inconclusive except for the brain haemorrhages. The changes in the

retina and optic nerve, if demonstrated, can be valuable in the diagnosis of suspected methanol poisoning.

Case Report

A 45 year old man was brought to the emergency of a private hospital with a history of ingestion of methanol at a local school laboratory. The patient was a chronic alcohol and had been complaining of fever, headache, nausea, blurring of vision, two episodes of seizures and breathlessness since one day.

On arrival he was comatose and in gasping state with Spo2 60% and GCS of 4/15. His vitals were; pulse rate: 77/min, BP: 90/50 mmHg, respiratory rate: 18/min, temperature: 98.4F. Basal crepitations were present on chest auscultation. CNS examination showed grade 4 encepathopathy. Pupils were mid-dilated sluggishly reacting to light, positive dolls eye reflex and mild pallor of optic disc was seen. Patient had severe metabolic acidosis with Ph: 6.8 and HCO3: 4meq with hypokalemia. His blood ethanol levels were 127.33mg/dl. CSF examination showed raised protein (67mg/dl), raised TLC (10cells/cumm), DLC: 75% neutrophils and 25% lymphocytes. His chest X-ray, liver function and kidney function tests were normal. MRI brain with contrast showed symmetrical restricted diffusion with post contrast enhancement in bilateral putamen suggestive of putaminal necrosis consistent with methanol toxicity. Mild leptomeningeal enhancement with hyper intensities in bilateral deep white matter was seen suggestive of meningo-encephalitis. Brainstem and cerebellum appeared normal.

He was electively intubated and started on ventilator management. He was managed on the lines of methanol poisoning with oral ethanol via NG tube, sodium bicarbonate, methanol and dopamine. Dialysis was done a single time. Deceased was shifted to Lok Nayak hospital on the third day. Here he was managed conservatively in the medical ward. His general condition during hospital stay was critical and he had been unconscious throughout. He expired twelve days after the initial insult. The deceased was shifted to the mortuary for post-mortem examination.

Autopsy Findings

At autopsy the deceased was a middle aged male measuring 165 cm in length and weighed 64 kg. Post-mortem staining was present over the back of the body and rigor mortis was developed in all the major joints of the body.

On external examination of the body, there were small minor abrasions over the chest and knees. Small contusions were seen over the left thigh and back of both heels. On internal examination, both the lungs had congestive changes without any other abnormality. The mucosal wall of the respiratory tract was congested. Both kidneys were unremarkable except for congestion. On opening the skull, the dura was intact, the meninges appeared normal and the brain was soft to touch. On cut section, the central and peripheral region of Pons showed hemorrhagic areas, measuring 1.8 cm x 0.9 cm (fig 1, A). The right basal ganglia region showed a hemorrhagic area measuring 1.5cm x1.4 cm x 0.9 cm, with surrounding necrosis of the brain parenchyma (fig 1, B).

Retina and optic nerve were normal on gross examination. The eyeballs were removed including part of the optic nerve after taking consent of the relatives of the deceased. Subsequent histological examination of the retinal tissues revealed the following findings: Detachment of normal appearing renal pigment layer with focal degeneration of ganglion cells in haematoxylin and eosin stain (fig

2); absent retinal pigment layer with sub-epithelial hyaline deposits (fig 3); normal looking ganglion cells but decreased in number and frequency (fig 4) and sub-retinal hyaline deposits (fig 5).

Discussion

Methanol poisoning is a hazardous intoxication characterized by visual impairment and metabolic acidosis. Its toxicity occurs after accidental or suicidal ingestion of industrial solvents or occasionally due to adulterated wine or other alcoholic beverages. The metabolic products mainly formaldehyde and formic acid cause the toxic effects after ingestion. Symptoms are usually observed after 12-24 hr after methanol consumption which may include nausea, vomiting, headache, dizziness, and visual disturbances ranging from blurred vision to permanent blindness. As the metabolic acidosis worsens, respiratory failure and coma ensue. [1,3,7,8]

Mittal B V et al reported a varied range of development of symptoms between 7 1/2 hours to 60 hours. Minimum fatal period was 7 1/2 hours and maximum was 12 days. Blurring of vision was seen in 42.8% and blindness in 10.7% of cases.[7]The deceased in this report developed symptoms few hours after ingestion of methyl alcohol and he survived for a period of 12 days. His symptoms like nausea, vomiting, blurring of vision, and seizures were consistent with methanol poisoning.

Brain haemorrhages, in methanol poisoning, especially in the putamen, have been reported by many authors. [3,5,6,7] It has been suggested that the putamen is at particular risk because of its high metabolic demand and location in an end zone of vascular perfusion.[10]
Other studies have shown shrinkage and degeneration of neurons in the parietal cortex, putaminal degeneration and necrosis haemorrhage and sponginess in the optic chiasma.[7] In this case haemorrhages were seen in the pons and right basal ganglia though the MRI did not reveal any brainstem haemorrhage.

Most of the studies on methanol toxicity pertain to the optic nerve due to the well documented retro-bulbar optic neuritis. There are few studies which demonstrate changes in the retina. The common histological findings in most of the studies included generalized retinal edema, vacuolation in the photoreceptors and retinal pigment epithelium. Demyelinization of the optic nerve, swelling and disruption of the mitochondria in photoreceptor inner segments, optic nerve, and the retinal pigment epithelium.[4,11,12,13]

In our report the following histological findings were seen: (i) detachment of the renal pigment layer (ii) focal degeneration of ganglion cells (iii) sub-epithelial hyaline deposits (iv) decrease in the number and frequency of normal looking ganglion cells. There are some variations in the findings in comparison to older studies. This may be explained by the long duration of survival in this case which could have led to the changes in the retina. Also, most of the studies have been done on rodents and non primates, possibly leading to variable findings. Though the visual symptoms and retinal toxicity of methanol are well known, there are very few human based studies on the histological changes in the retina. As there are no distinct and specific gross findings in the eye in such cases, histological examination is imperative.



Fig 1: Portion of Pons showing haemorrhagic areas (A); Basal ganglia showing haemorrhagic areas (B)

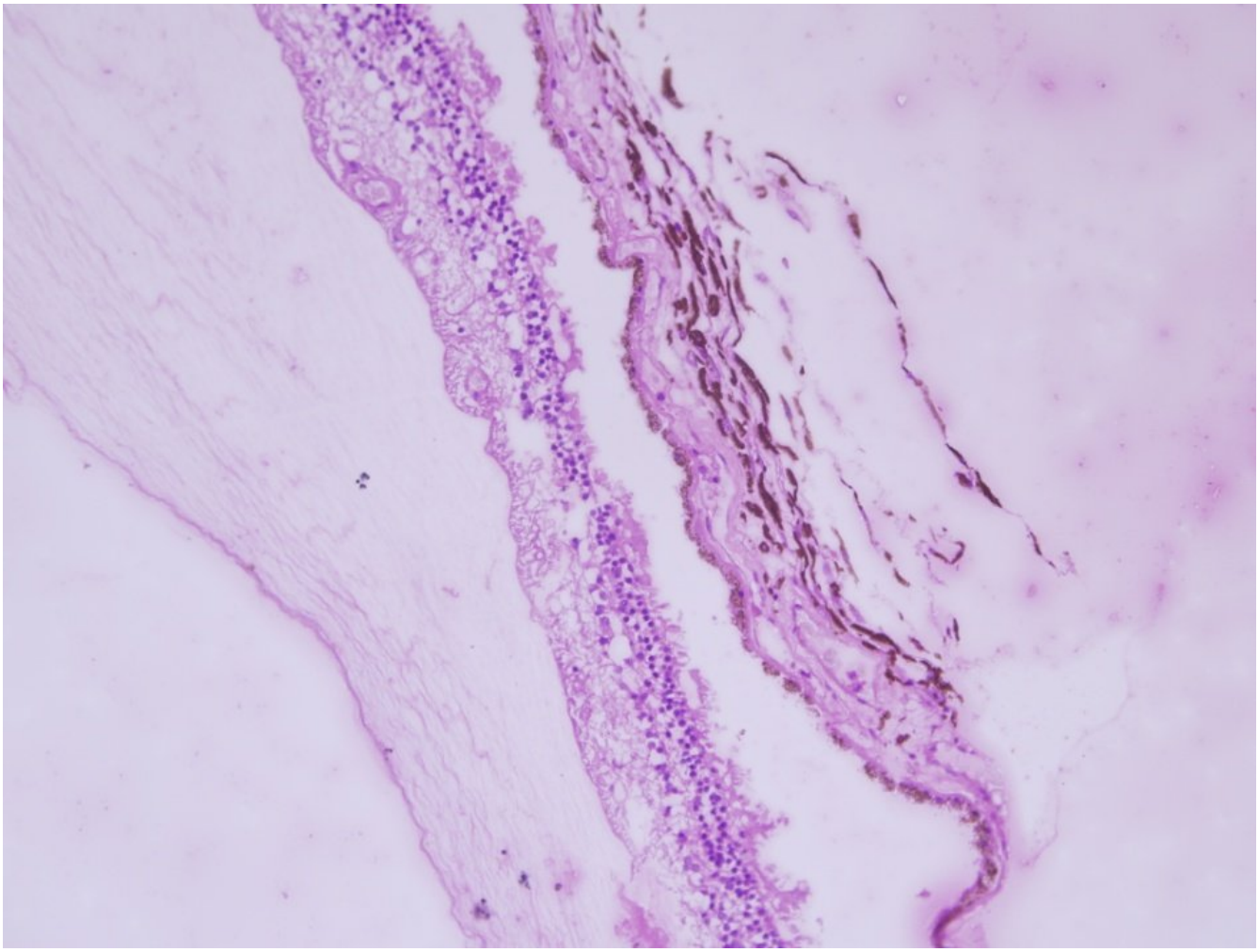

Fig 2: Portion of retina showing detachment of normal appearing renal pigment layer with focal degeneration of ganglion cells. (hematoxylin and eosin, magnification x 20)

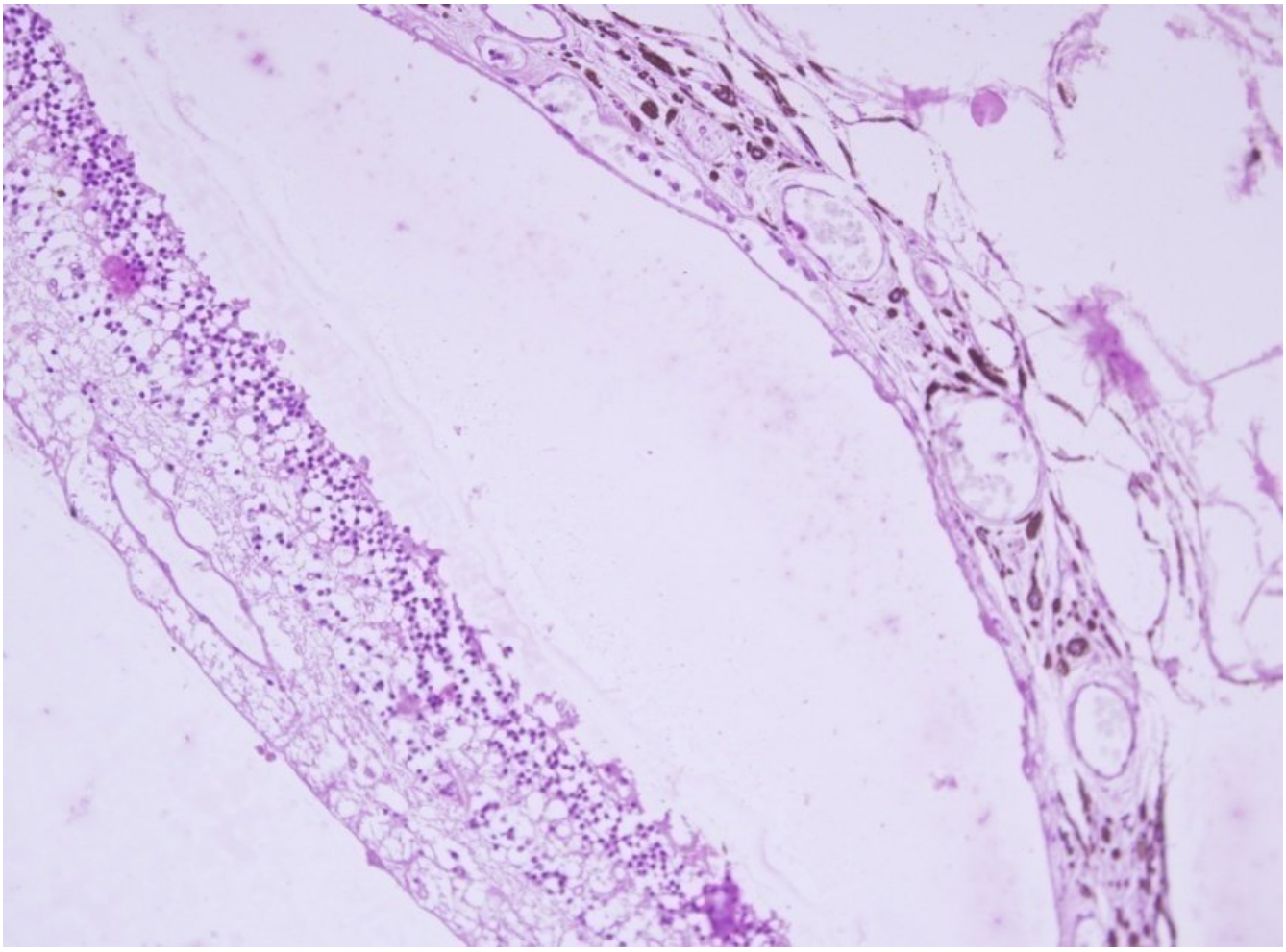

Fig 3: Retina slide showing absent retinal pigment layer with sub-epithelial hyaline deposits (magnification x20)

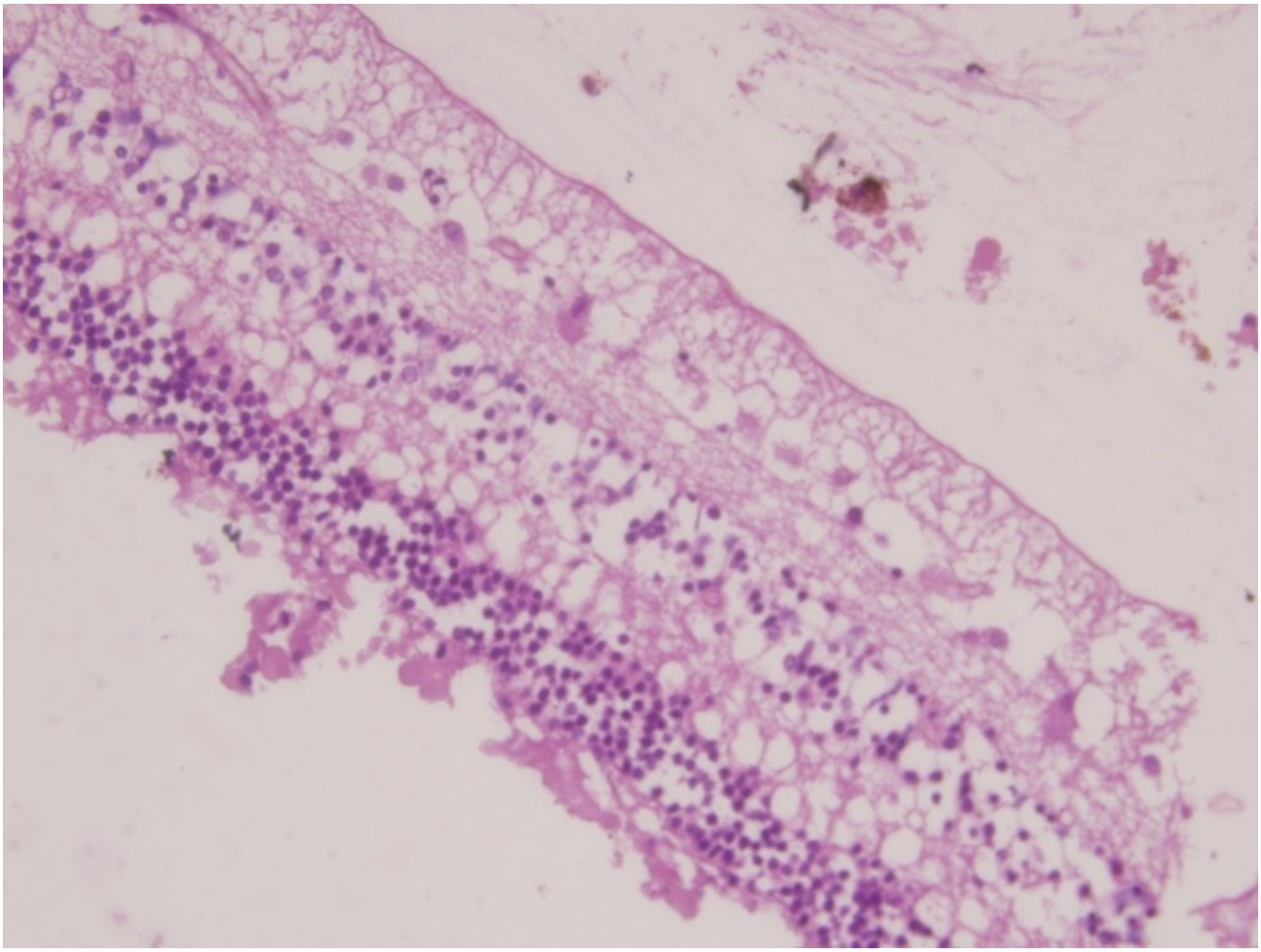

Fig 4: Slide of retinal layers showing normal looking ganglion cells but decreased in number and frequency (magnification x40)

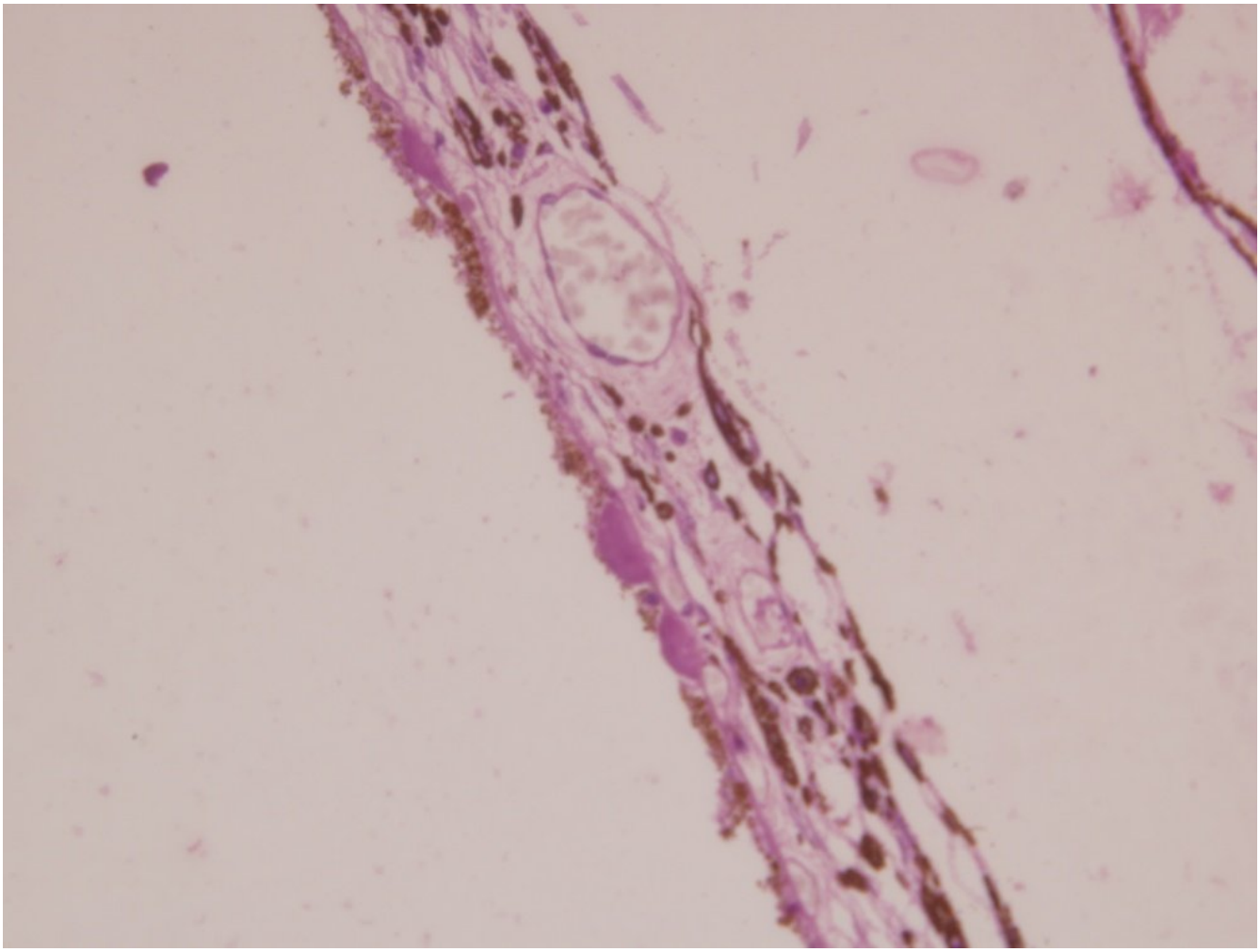

Fig 5: Slide showing sub-retinal hyaline deposits (magnification x40)

References

1. Modi. A Textbook of Medical Jurisprudence & Toxicology, 24th edition, Lexis Nexis Butterworths Wadhwa, Nagpur, 2011.
2. Krishan V. Textbook of forensic medicine and toxicology, 4th edition, Elsevier, 2008.
3. Mark G, Peter D. Necrosis of the Putamen Caused by Methanol Intoxication: MR Findings. AJR160:1105-1106, 1993.
4. Albert M. P. Retinotoxic and Choroidotoxic substances. Investigative Ophthalmology 1(3):290-303, June 1962.
5. Askar A, Al-Suwaida A. Methanol Intoxication with Brain Hemorrhage: Catastrophic outcome of late presentation. Saudi J Kidney Dis Transpl 18:117-22, 2007.
6. Blanco M. R. Casado F. Va´ zquez J.M. Pumar. CT and MR Imaging Findings in Methanol Intoxication. Am J Neuroradiol 27:452– 454, 2006.
7. Mittal BV, Desai AP, Khade KR. Methyl alcohol poisoning: an autopsy study of 28 cases. J Postgrad Med 37:9-13, 1991.
8. Comoğlu S, Ozen B, Ozbakir S. Methanol intoxication with bilateral basal ganglia infarct. Australas Radiol 45(3): 357-8, 2001.
9. Sharpe JA, Hostovsky M, Bilbao JM, Rewcastle NB. Methanol optic neuropathy: a histopathological study. Neurology 32(10):1093-100, 1982.

10. Hsu HH, Chen CY, Chen FH, et al. Optic atrophy and cerebral infarcts caused by methanol intoxication: MRI. Neuroradiology 39:192-4, 1997.
11. Murray TG, Burton TC, Rajani C, Lewandowski MF, Burke JM, Eells JT. Methanol poisoning. A rodent model with structural and functional evidence for retinal involvement. Arch Ophthalmol 109(7): 1012-6, 1991.
12. Eells JT, Salzman MM, Lewandowski MF, Murray TG. Formate-induced alterations in retinal function in methanol-intoxicated rats. Toxicol Appl Pharmacol 140(1):58-69, 1996.
13. Lars M, Ulrich S. An Overview on the Toxic Morphological Changes in the Retinal Pigment Epithelium after Systemic Compound Administration. Toxicol Pathol 35: 252-267, 2007.