ANIL AGGRAWAL'S
Internet Journal of Forensic Medicine and Toxicology
The world's first online journal devoted entirely to forensic medicine and toxicology · Published 1 January and 1 July

VOL. 15, NO. 1 · JANUARY – JUNE 2014
Downloaded from www.anilaggrawal.com · ISSN 0972-8074 (Online) · https://www.anilaggrawal.com/ij/vol_015_no_001/papers/paper007.html

Stabbed, Stabbed,... and Strangulated: Multiple Means of Homicide - A Case Report

Pawan Mittal[1*], Anil Kumar Malik[2], Vijay Pal Khanagwal[3], P.K. Paliwal[4]

[1]Demonstrator, Department of Forensic Medicine, Pt. B.D. Sharma PGIMS, Rohtak, Haryana, India
[2]Resident, Department of Forensic Medicine, Pt. B.D. Sharma PGIMS, Rohtak, Haryana, India
[3]Professor, Department of Forensic Medicine, Pt. B.D. Sharma PGIMS, Rohtak, Haryana, India
[4]Senior Professor and Head, Department of Forensic Medicine, Pt. B.D. Sharma PGIMS, Rohtak, Haryana, India
Contact: Pawan Mittal · drmittalpawan@gmail.com

CITE THIS ARTICLE

Mittal P, Malik AK, Khanagwal VP, Paliwal PK. Stabbed, Stabbed,… and Strangulated: Multiple Means of Homicide - A Case Report. *Anil Aggrawal's Internet Journal of Forensic Medicine and Toxicology* [serial online], 2014; Vol. 15, No. 1 (January – June 2014): [about 10 p]. Available from: https://www.anilaggrawal.com/ij/vol_015_no_001/papers/paper007.html

ABSTRACT

Finding multiple means of homicide in a case is not a very common and frequent finding in routine autopsies. In all cases, where multiple fatal homicidal injuries have been inflicted, the principle cause of death may have to be determined. But in certain cases where marked degree of violence has been used, the autopsy facts emerge themselves with each injury playing a role in causing the death. It becomes one of the prime duties of a forensic expert to find out the cause of death in such cases, especially when multiple means of homicide are involved which indicate multiplicity of the assailants. Here is a case where the victim was murdered by inflicting multiple stab wounds over the chest and abdomen and was violently strangulated along with; all the injuries collectively contributed to the death in this case. The same is described here in the light of the available literature.

Keywords: Homicide, Stab wounds, Strangulation, Decomposition, Asphyxia, Haemorrhage

Introduction

The word homicide is derived from the Latin word *homcidium*. Homo means 'man' & caedere means 'to cut, kill'. Homicide is the act of a human killing another human.[1] It is one of the leading cause of unnatural deaths. A study on homicidal deaths showed gunshot wounds were the most common cause of death (37%), followed by stab wounds (27%), blunt trauma (19%), and asphyxia (13%).[2] The method(s) employed may be single or multiple. Cases involving multiple homicidal

injuries by various methods are rare and constitute one of the most challenging jobs for a forensic expert. Furthermore, the findings are greatly obscured if there is onset of decomposition in the body. But in some cases, like deaths from actual strangulation, the compressed tissue of the ligature mark instead of obliteration, are better preserved than the putrefied skin beyond it.[3] In the similar manner shape of the stab wound may be better appreciated by approximating its margins and by looking at the shape of the wound over internal organs involved, if any. This correlation may be made better even in a decomposed body and the nature of the likely sharp weapon, whether single edged or double edged, can be made out. Though the value of autopsy is progressively reduced as the state of putrefaction advances, no shortcuts should be taken by the pathologist merely because of unpleasant nature of examination.[4] The degree of contribution of an injury to the cause of death can be judged from the extent of the structures involved due to it. Stabbing injuries are generally located at the chest (predominantly left chest), abdomen and neck, and more rarely at the head; the number of stabs varies considerably from one (50% of cases) up to more than 90.[5-9] In cases of multiple injuries, each injury may contribute significantly to the cause of death. The emphasis is laid upon the same with the help of the case described here.

Case history

A decomposed body was referred (in the month of June) to the Deptt. of Forensic Medicine Pt. B.D. Sharma PGIMS, Rohtak. Purportedly the body was recovered from a canal a day before autopsy. The information furnished by the police regarding cause of death in this case was due to sharp object with mentioning of only one sharp injury over the left side of chest. The body was foul smelling with maggots crawling all over, chest & abdomen distended, epidermis peeled off, with post mortem bullae at places with bloated but identifiable facial features. On thorough autopsy a total of 17 injuries including 16 stab wounds plus findings of strangulation (by ligature) were noticed over the body, all injuries damaging the underlying vital structures significantly as follow:

1. A discolored brownish-black ligature mark was present all around the neck transversely situated at the level of thyroid cartilage along with a contusion just below its left side front. On dissection, underlying subcutaneous tissues, lamina of thyroid cartilage, neck muscles including cervical prevertebral muscles & soft tissues were found to be deeply ecchymosed. The trachea was contused.
2. A tear drop shaped stab wound of size 3 x 2 cm was found situated vertically over left front chest wall region with beveling of left margin and undercutting of right margin, at the level of 5th intercostals space, directed front to back, slightly downward & medially piercing muscles, underlying pleura & lower lobe of left lung which was collapsed, putrefied & softened. The left pleural cavity was full of clotted and liquid blood.
3. Multiple tear drop shaped wounds, 4 in number, each of size 1.5x1 cm, all situated transversely, were present over the posterior aspect of right chest wall, directed back to front & slightly medially, piercing the underlying structures including intercostal muscles, pleurae & middle lobe of right lung which was collapsed, putrefied & softened. The right pleural cavity was full of clotted & liquid blood.
4. Multiple tear drop shaped wounds, 11 in no., of size varying between 2-4x1-1.5 cm were present over right posterolateral aspect of abdominal wall, situated in various directions, with some of them with merging margins, all directed from right to left and medially,

piercing abdominal wall structures including soft tissues, muscles, retroperitoneal region approaching right kidney which shows piercing of the capsule and cortex with multiple corresponding wounds over it. Retroperitoneal region was contused and full of liquid blood and fistful of dark red haematoma.

After completion of autopsy it was opined that the cause of death in this case is asphyxia as a result of strangulation coupled with haemorrhage & shock consequent to the stab injuries described via injuries no. 2, 3 & 4. The stab injuries described via injuries no. 2, 3 & 4 have been caused by single edge sharp cutting weapon. All the injuries are antemortem in nature, homicidal in manner & recent in duration. The probable time that elapsed between injuries and death was opined to be immediate and the post mortem interval was opined to be 24 to hours.

Discussion

The cause of death is the disease or injury responsible for starting the sequence of events, which are brief or prolonged and which produce death. Manner of death may be suicidal, homicidal, accidental or of undetermined or unexplained origin.[10] A number of cases have been reported all across the world where multiple methods of homicide have been used to kill a single victim. A case study from Romania indicates that a victim was killed by 3 different mechanisms of asphyxia: smothering with the hand, manual strangulation with the other hand, and traumatic asphyxia by thoracic compression with the knees.[11] The autopsy findings in multiple means of homicide may help in revealing the involvement of more than one assailant that plays an important role in police investigation and trial of the case in the court. While framing the opinion on these points before the Court of Law, the medico-legal expert shall have to justify his remarks based on such findings observed during autopsy.

Conclusion

It is one of the prime duties of a Forensic Expert to decide upon the cause of death in all unnatural deaths including homicidal deaths and it becomes very crucial when more than one method have been employed to kill the victim in homicidal deaths. In such cases the opinion as to the cause and manner of death carries utmost importance as to the nature and manner of infliction of each injury.



Stab wound over left chest wall



Stab wounds over right chest wall

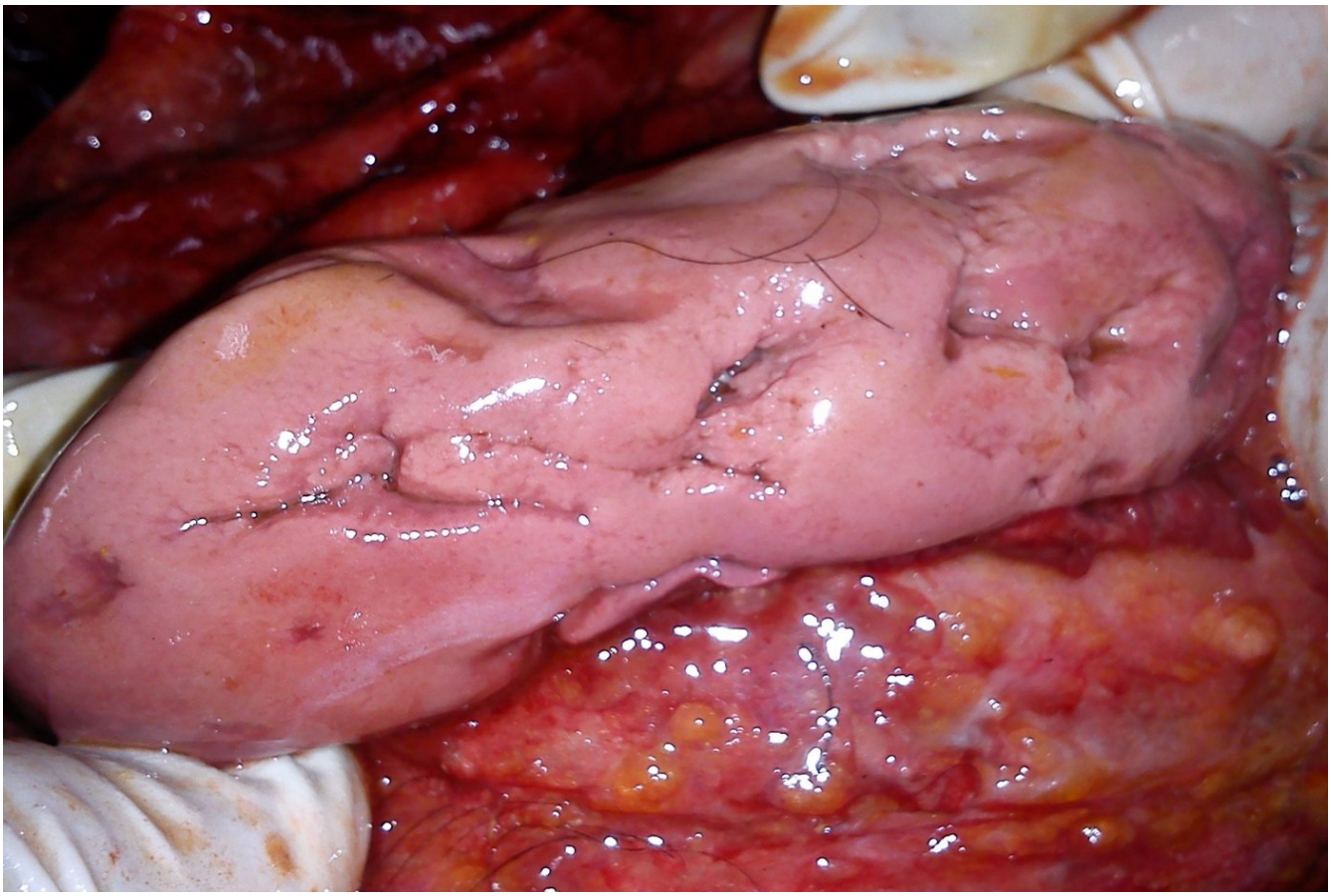

-(i) Stab wounds over right kidney



(ii) Stab wounds over right kidney



Ligature mark along with contusion

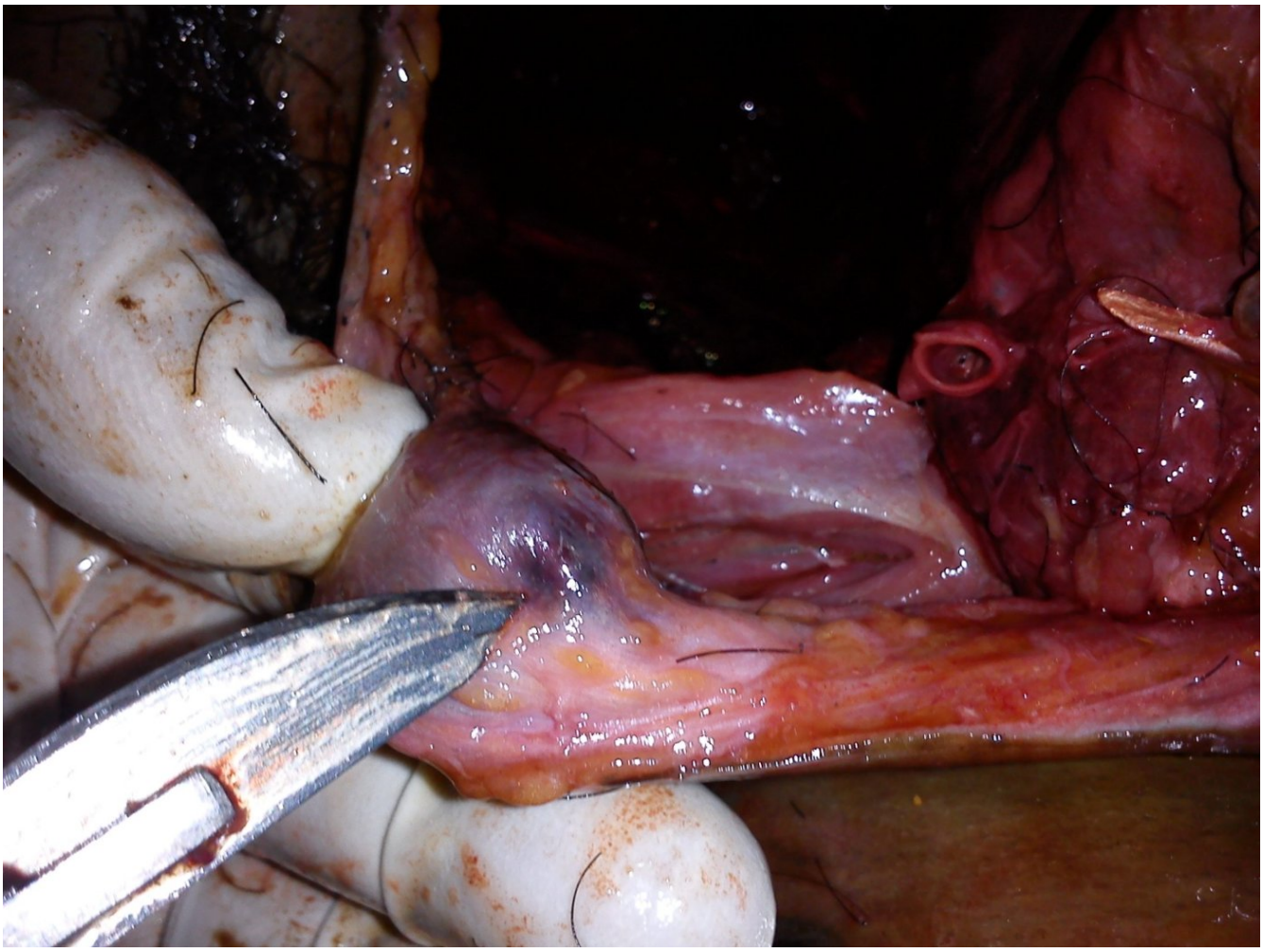

Ecchymosis of subcutaneous tissues under ligature mark

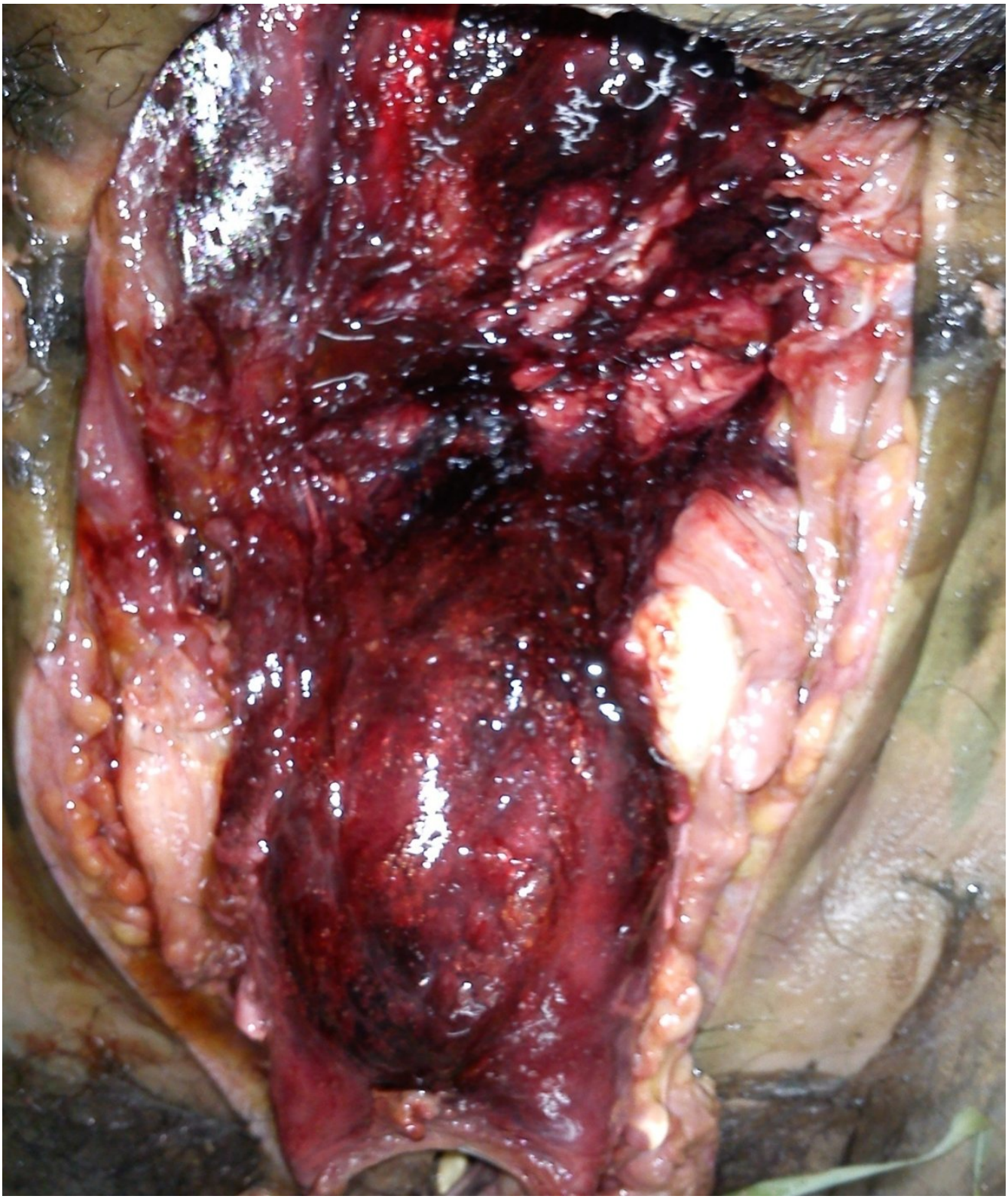

Haemorrhagic infiltration in internal neck structures



Alleged weapon (single sharp edge knife)

References

1. Irving, Shae. Nolo's Plain-English Law Dictionary, Ed. (2009) "homicide". Berkeley: Nolo; pp. 204–5.
2. Cros J, Alvarez JC, Sbidian E, Charlier P, Lorin de la Grandmaison G. Homicidal deaths in the Western suburbs of Paris: a 15-year-study. Am J Forensic Med Pathol. 2012 Dec;33(4):404-9.
3. Karmakar RN. J.B. Mukherjee's Forensic medicine and toxicology.4th ed. Kolkata: Academic Publishers; 2011: p.528.
4. Saukko P, Knight B. Knight's Forensic Pathology. 3rd ed. London: Oxford University Press Inc.; 2004.p.39-40.
5. Herzog M, Hoppe F, Baier G, Dieler R. Injuries of the head and neck in suicidal intention. Laryngorhinootologie 2005;84:176–81.
6. Bernemann D, Arnhold-Schneider M. Mechanisms of injuries of cut and stab wounds of the neck. Laryngol Rhinol Otol (Stuttg) 1988;67:382–4.
7. Chadly A, Marc B, Paraire, Durigon M. Suicidal stab wounds of the throat. Med Sci Law 1991;31:355–6.
8. Scolan V, Telmon N, Blanc A, Allery JP, Charlet D, Rouge D. Homicide-suicide by stabbing study over 10 years in the toulouse region. Am J Forensic Med Pathol 2004;25:33–6.

9. Karger B, Vennemann B. Suicide by more than 90 stab wounds including perforation of the skull. Int J Legal Med 2001;115:167–9.
10. Reddy KSN. The essentials of forensic medicine and toxicology. 31st ed. Hyderabad: Om Sai Graphics; 2010: p. 131.
11. Lupascu C, Lupascu C, Beldiman D, Mechanical asphyxia by three different mechanisms. Legal Med 2003; 5:110 –1.