ANIL AGGRAWAL'S
Internet Journal of Forensic Medicine and Toxicology
The world's first online journal devoted entirely to forensic medicine and toxicology · Published 1 January and 1 July

VOL. 15, NO. 1 · JANUARY – JUNE 2014
Downloaded from www.anilaggrawal.com · ISSN 0972-8074 (Online) · https://www.anilaggrawal.com/ij/vol_015_no_001/papers/paper003.html

Mutilation of Human Dead Body without Mutilating the Cause of Death - Study of two case reports.

Basant Lal Sirohiwal[1*], Hitesh Chawla[2], P. K. Paliwal[3]

[1]Professor, Dept of Forensic Medicine, Pt. BD Sharma University of Health Sciences, Postgraduate Institute of Medical Sciences, Rohtak, Haryana 124001, India
[2]Assistant Professor, Dept of Forensic Medicine, SHKM Government Medical College, Nalhar, Mewat, Haryana 122107, India
[3]Senior Professor & Head, Dept of Forensic Medicine, Pt. BD Sharma University of Health Sciences, Postgraduate Institute of Medical Sciences, Rohtak, Haryana 124001, India
Contact: Basant Lal Sirohiwal · drbasantsri@gmail.com

CITE THIS ARTICLE

Sirohiwal BL, Chawla H, Paliwal PK. Mutilation of Human Dead Body without Mutilating the Cause of Death - Study of two case reports.. *Anil Aggrawal's Internet Journal of Forensic Medicine and Toxicology* [serial online], 2014; Vol. 15, No. 1 (January – June 2014): [about 5 p]. Available from: https://www.anilaggrawal.com/ij/vol_015_no_001/papers/paper003.html

ABSTRACT

Mutilation is an act of physical injury that degrades the appearance or function of any living body, sometimes causing death. Mutilation of a body could be intentional or unintentional during life or after death for mainly destroying the identity. It could be in accidents either in factory while working with machine, road / rail, attack of living beings / animals or manmade and so on. Here we report two dead bodies of young adult male persons with mutilation of head and neck region by animals brought for postmortem examination in which the cause of deaths were ascertained as head injury and strangulation by ligature respectively on subtle & careful examination.

Keywords: Mutilation of head and face, gnawing effects, ante-mortem injuries, head injury, ligature strangulation

Introduction

The investigating agencies are usually silent while completing the inquest papers about the information of the cause of death in mutilated dead bodies and leave all on the autopsy surgeon to give opinion in this regard.

Mutilation of dead body is not always the act of criminals with some motive but the animals such as rats, dogs, jackals and hyenas, mongoose; and the birds such as vultures may also attack the dead

body and mutilate it in a very short time, especially when the body is exposed in an open place. Animal predation is a part of natural food chain. They usually attack the exposed body parts and particularly those soaked with blood or human fluids due to injuries or otherwise; and thus eat away the soft tissues resulting into skeletonization of the body sometimes even in less than 24 hours. The animal activity may even alter ante-mortem injuries. Postmortem predation creates injuries that arouse suspicions of homicide. Large defects on the face, neck, and torso with variable loss of viscera and bony injury are observed following predation by large pets e.g., dog.[2] Examiners should pay careful attention to wound edges, particularly the possibility of animal tooth marks left on cartilage or bone.[1] Animal scavenging creates difficulties with the interpretation of various medico-legal questions such as identity of the victim and cause of death and, as a consequence, criminal charges against the perpetrator cannot be framed or proven.[3]

Case report No. 1

The deceased was a middle aged male laborer. And drinking alcohol was his daily routine. On one day of late January 2011 he went away from his home to some place where he was drunk as usual and then didn't come back. His wife and brother in law searched for him in nearby areas but couldn't locate him. On the next very day, they found people gathering around a park in the neighboring market area of the city. They went to that place and found a dead body lying there on pebbles with his head and perineum mutilated. Along side of the body a pair of sleepers, a blanket and an empty bottle of alcohol was lying. The cloths were torn at places more-so on the area corresponding to perineum (Fig-1/a). The dead body was beyond recognition, but, identified on the basis of belongings; and it was presumed that he had died due to excessive intake of alcohol. Investigating officer also thought of the same as no other appreciable injury was noticed over the body except the mutilation of head and perineum suspecting due to animals –dogs bites etc. The body was taken to a peripheral hospital for post-mortem examination. After observing the mutilation of parts of face, neck, scalp and perineum the board of doctors referred this body to the department of forensic medicine, PGIMS, Rohtak for expert opinion. The post-mortem examination was conducted in our department.



The dead body lying on pebbles in the park the clothes were torn in layers more so on the area of genitals with sleepers and blanket alongside (scene of recovery of dead body) (Fig-1a)

Post-mortem examination

The dead body was of a male wearing a full sleeved sweater & shirt, a warmer, T-shirt underneath, a pantaloon and underwear that were unevenly torn. Rigor mortis was appreciated all over the body. Post-mortem staining was faintly visible over the back. The facial soft tissues and facial bones along with both orbits were gnawed at. The facial features were distorted and were not identifiable. The soft tissues over the neck along with larynx and trachea were missing; the skin was showing superficial bite marks in the lower front of neck and upper aspect of thorax (Fig-1/b). The skin and soft tissues surrounding the perineal area were gnawed at and showing bite marks; the stump of penis and scrotal sac were missing (Fig-1/c). Both the lungs were pale. All abdominal organs were pale (Fig-1/d).



Facial features unidentifiable and Head and neck area gnawed at (Fig-1/b)



External genitals were missing and perineal area showing gnawing effects in the form of bite marks in the surrounding (Fig-1/c)

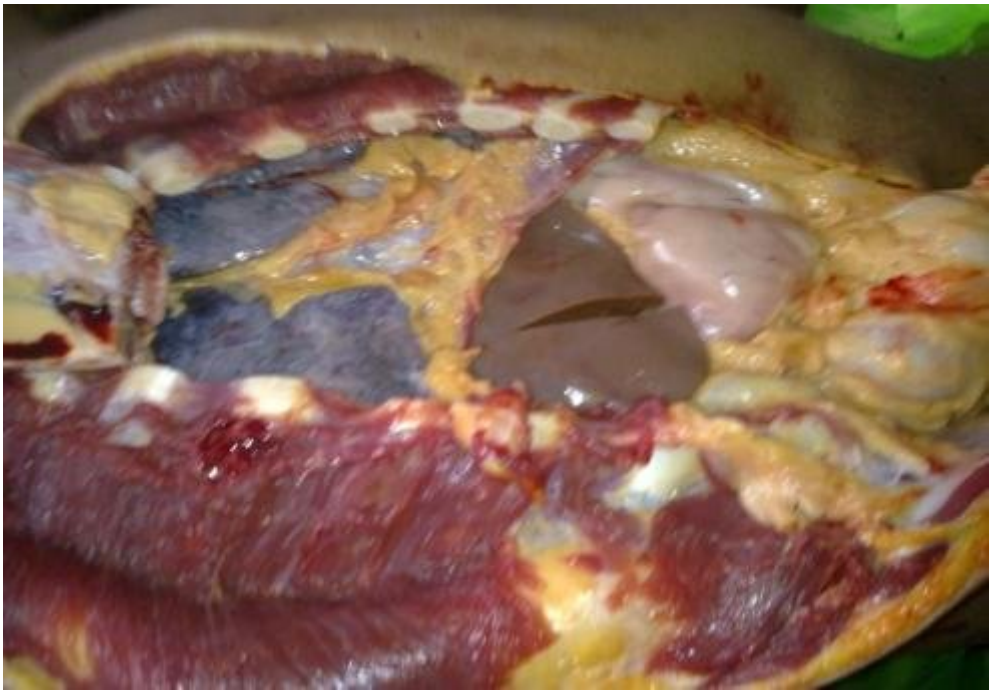

Thoracic and abdominal viscera in situ were pale and healthy look (Fig-1/d).

On dissection, the scalp was found ecchymosed underneath over the left vertex area (Fig-1/f); a linear fracture of 14 cm seen in left fronto-temporo-occipital area, 8 cm away from the midline along with multiple exposed bone pieces (Fig-1/g); and the subdural and subarachnoid hemorrhages were well appreciated over both cerebral hemispheres.



thick clotted blood under the scalp over the back of vertex(Fig-1/f)



Linear fracture over left fronto-temporo-occipital region (Fig-1/g)

After conducting the post-mortem examination on the basis of these findings, we concluded that the cause of death in this case was cranio-cerebral damages as result of ante-mortem head injury consequent upon blunt force / surface impact.

Case report No 2

On one morning of December 2006, a dead body of unknown male person rolled up and jumbled into a sac with head and neck partly exposed, was recovered from the dry canal under a bridge on a busy running road, and later on identified from the belongings. The dead body was mutilated over the head, neck and face beyond identification. The investigating officer made a point in his report that probably the body was thrown in to the canal in the dark of night by the assailants with the intention that it could be moved to a distant place in the running water of the canal and would remain as untraced; and this was also confessed by the accused persons during interrogation. But the water was not released from higher up from the main source so it remained lying there till next morning; and it was noticed by some passers who report about it to the police who took it for postmortem examination to a primary care hospital. A board of autopsy surgeons considering the condition of the body referred it to our department for expert opinion.

Postmortem examination: - the dead body was referred from a primary health centre to this tertiary care hospital for expert opinion considering the mutilatd condition of the body. The body was of a male individual; with mutilated facial, skull and cervical area exposing the bones all around. The exposed part of the skin area was showing the gnawing effects (arrow marks) due to eaten away of soft structures by the animals thus making the facial features distorted and unidentifiable. The sand particles and the twigs were stuck to the denuded parts indicating environ of its disposal. The rigor mortis was in passed off phase but the marbling effect over the upper chest area appreciated (Fig-2A, 2B, 2C). A ligature mark was appreciated on stretching out the mutilated

and gnawed skin in the lower front aspect of the neck (Fig-2D with arrow) the extravasations of the blood was appreciated in and around the lower aspect of esophagus and trachea under the flap of gnawed skin (Fig-2E) whereas the soft structures of the neck were eaten away by the animals including trachea, esophagus and other soft tissues above the level of bitten skin showing gnawing holes at places (Fig-2F). All the internal organs were congested and healthy. The cause of death was pronounced as strangulation by ligature which was ante mortem that was confirmed later on during the investigations.







The skin eaten away by the animals was showing the gnawing effects at places & dry twigs of husk along with dry papery apponeurosis over the skull (fig-2A, 2B, and 2C)



The skin was showing ligature mark on slight stretching and spreading it by holding with fingers (Fig-2D)

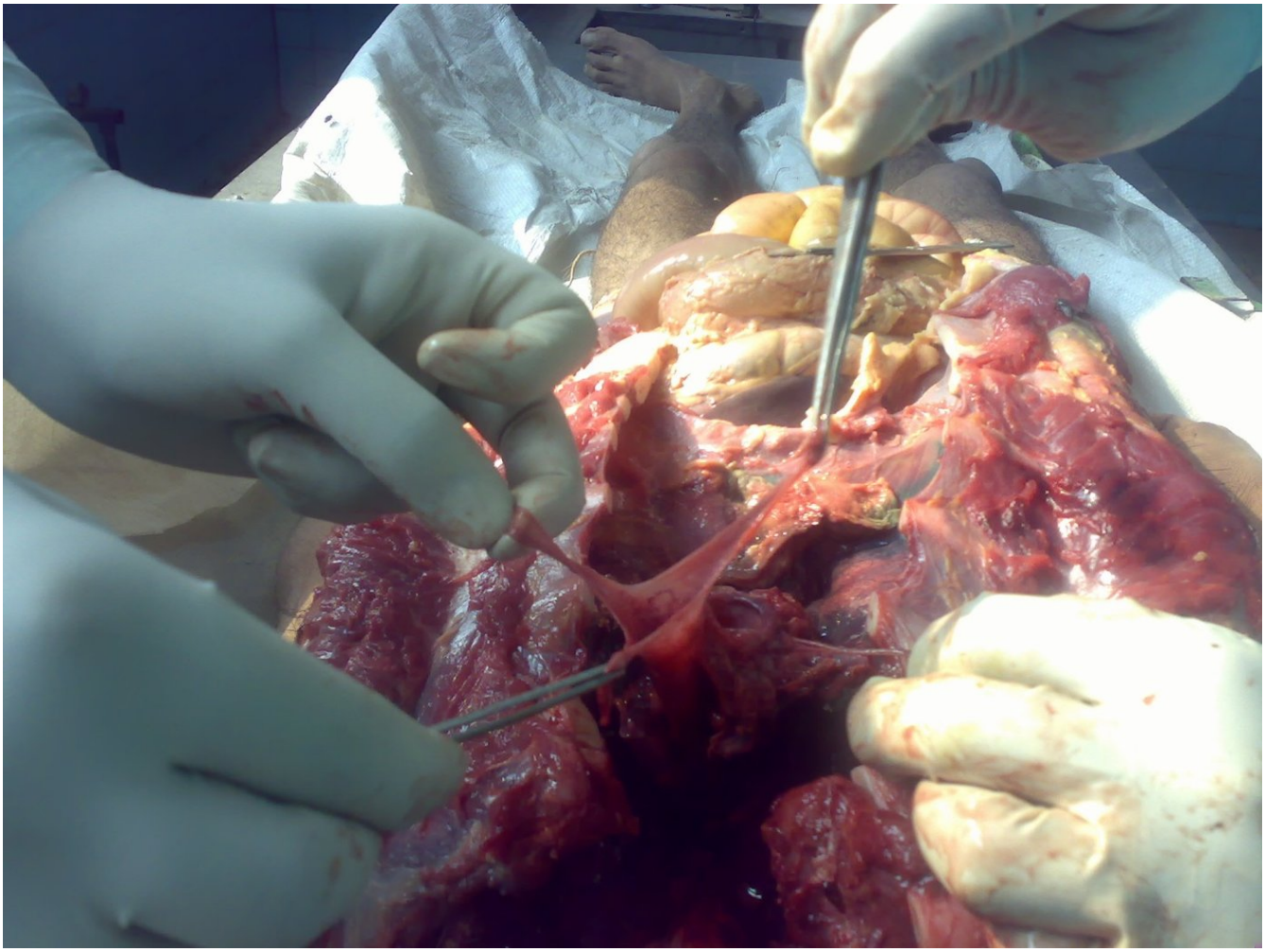

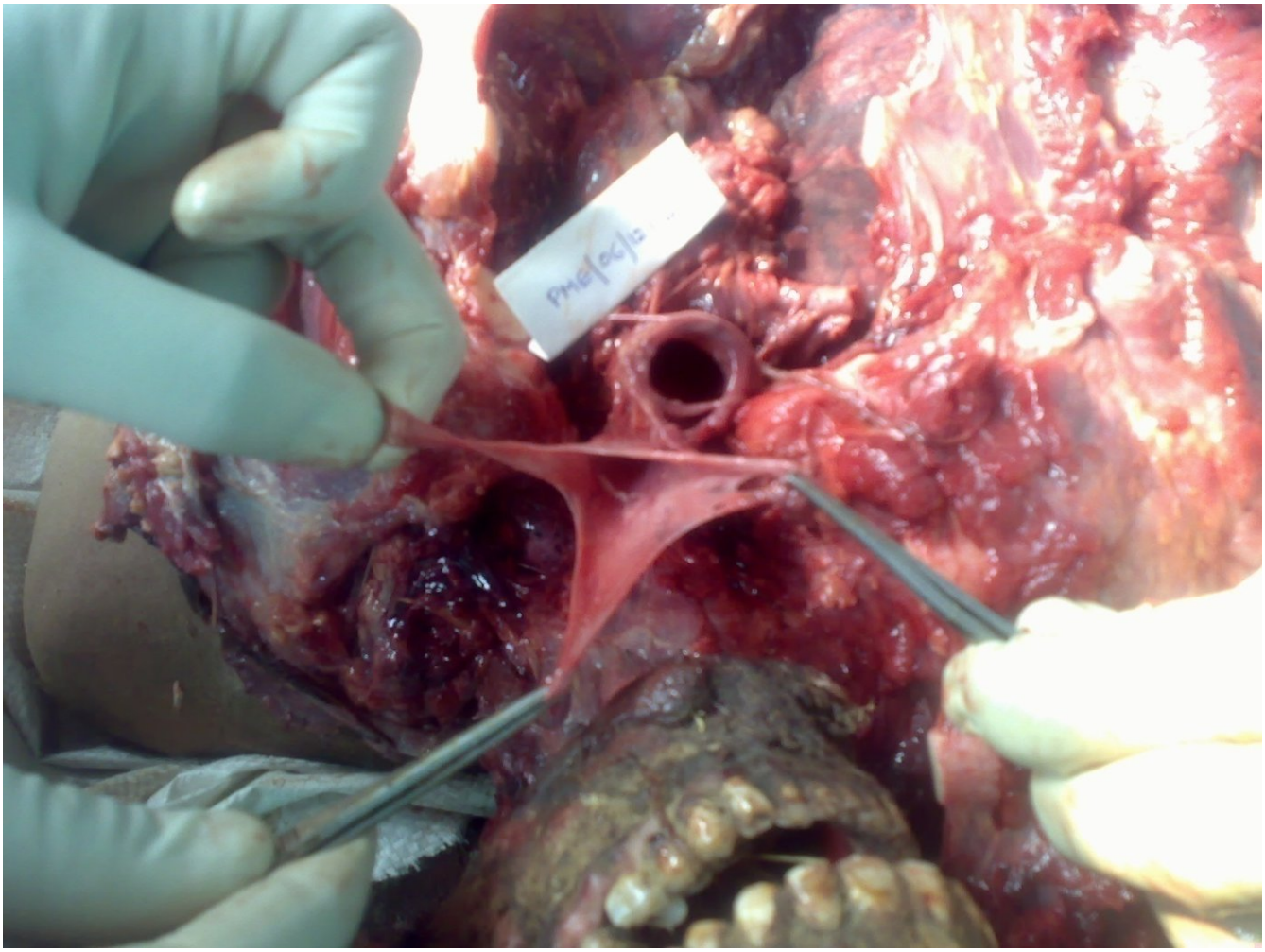

The arrow is indicating hole due to gnawing effect in esophagus behind bitten off trachea part (fig-2F)

Discussion and Conclusion

Mutilation or maiming is an act of physical injury that degrades the appearance or function of any living body, sometimes causing death[6]. It is not uncommon but cumbersome to perform the post-mortem specifically over the decomposed and mutilated dead bodies as compared to fresh bodies. However, any animal attacking the dead body will primarily select those areas where the skin is broken; thus it is not uncommon to find that ante-mortem wounds have been enlarged to a great degree by post-mortem invaders[5]. The cause of death can still be ascertained in mutilated body parts, if there is evidence of injury to some vital organ[4]. Like in the present two freshly looking dead bodies of about 24 hours duration with primarily mutilation of head and neck by animals; after differentiating the gnawing effects from the ante-mortem injuries with meticulous examination of these parts the cause of death were established as ante-mortem cranio-cerebral damage and ligature strangulation respectively and the same were confirmed subsequently during investigation also.

References

1. Forensic Pathology Principles and Practice. Dolinak D, Matshes EW. Lew EO. Elsevier. London. 2005 p. 548-50.

2. Forensic Pathology of Trauma, Shkrum M J., Ramsay DA. Humana Press.Totowa, New Jersey. 2007. P 57-8.
3. An autopsy study on medico-legal evaluation of post-mortem scavenging. Jani CB, Gupta BD. Med Sci Law. 2004 Apr; 44(2):121-6.
4. Mathiharan K, Kannan K. Modi A Text Book of Medical Jurisprudence and Toxicology. 24th ed. Lexis Nexis Butterworths Wadhwa:Nagpur;2012.p.393-94
5. Spitz WU, Fisher RS. Medicolegal investigation of death. Charles C Thomas. Springfield USA. 1973. Second Printing. p. 29
6. (http://en.wikipedia.org/wiki/Mutilation retrieved on 17.9.2012)