ANIL AGGRAWAL'S
Internet Journal of Forensic Medicine and Toxicology
The world's first online journal devoted entirely to forensic medicine and toxicology · Published 1 January and 1 July

VOL. 14, NO. 2 · JULY – DECEMBER 2013
Downloaded from www.anilaggrawal.com · ISSN 0972-8074 (Online) · https://www.anilaggrawal.com/ij/vol_014_no_002/papers/paper001.html

An unusual fatal injury in a locally made plastic recycling machine -An autopsy case

Jatin Bodwal[1], C. Behera[2]

[1]Senior Resident, Department of Forensic Medicine, Maulana Azad Medical College, New Delhi, India
[2]Associate Professor, Department of Forensic Medicine, Maulana Azad Medical College, New Delhi, India
Contact: Jatin Bodwal · jatinbodwal@yahoo.co.in

CITE THIS ARTICLE

Bodwal J, Behera C. An unusual fatal injury in a locally made plastic recycling machine -An autopsy case. *Anil Aggrawal's Internet Journal of Forensic Medicine and Toxicology* [serial online], 2013; Vol. 14, No. 2 (July – December 2013): [about 6 p]. Available from: https://www.anilaggrawal.com/ij/vol_014_no_002/papers/paper001.html

ABSTRACT

A 30 year old average built person was cleaning inside of a locally made grinder machine used for recycling of plastics. Another person came and switched on the power supply of the machine accidentally. He got injured due to high speed rotating blades of the machine. He was immediately taken to private hospital then transferred to Lok Nayak Hospital, where died during the course of treatment after four and half days of survival. Though machinery related deaths are common, but the case described here is rarely reported in forensic literature.

Keywords: Head injury; plastic grinder; machine; recycling

Introduction

In India post consumer scraps are available in huge quantities at a low price, and sometimes for free. So many industries have been set up for recycling of products like plastic etc for economic and environmental reasons. For recycling of plastics a grinder machine is used which crush every kinds of big plastic materials, bottles, plastic waste films etc. The grinder comprises of highly sharpened blades having high rotation speed and strong cutting power. Persons can sustain injuries while working on these machines as it works on high power electricity.

Case report

A 30 year old average built, worker, was cleaning the inner part of a locally made plastic grinding machine in bending position. Another person switched on the power supply of the machine accidentally. He got injured due to rotating blades (used for grinding plastic material) of the

machine. (**Fig.1&2**) He was taken to a private hospital and then transferred to Lok Nayak hospital, where he died during the course of treatment. The size of the machine was 4 ft. height and the diameter 3.5 ft. There were two rotating blades on upper part of the machine measuring 12.6inches and two in lower part measuring 12.4 inches. These rotating blades were made up of iron and having blunt edge. The capacity of motor was 10 hp.





Fig. 1. Plastic grinder machine. **Fig. 2.** Inside of the machine showing blades.

Autopsy report

The dead body was that of a young male wrapped in hospital sheet. Average in built and height was 160 cm. External examination the following injuries were found

1. Multiple abrasions over the face and the front of right arm.
2. Partially healed superficial burns were present over parts of face, neck, front of chest, abdomen and left shoulder.
3. Stitched wound of length 7 cm was present horizontally on the left side of forehead, 2 cm above the mid eyebrow. On removing the stitches, a contused lacerated wound 7 cm x 1 cm x 0.5 cm, was found. **(Fig.4)**
4. Stitched wound of length 7 cm was present horizontally on the left side of forehead, 2 cm above the mid eyebrow. On removing the stitches, a contused lacerated wound 7 cm x 1 cm x 0.5 cm, was found.
5. Stitched wound of length 5.5 cm contused lacerated wound 5.5 cm x 1 cm x 0.5 cm, was present on the left side of forehead involving left eyebrow.
6. Contused lacerated wound 4 cm x 0.3 cm x 0.2 cm, was present on the left cheek, 2 cm below lateral angle of left eye.

7. Contusion 4 cm x 4 cm bluish black in color was present on the back of right ear, on mastoid process.
8. Contusion 4 cm x 3 cm bluish black, upper part of front of left leg with underlying closed fracture of tibia and fibula bone 2cm below knee associated with haematoma.





Fig. 3. Head and facial wounds. **Fig. 4.** Plastic pieces embedded in wound.

At the time of examination of the wound number 3, 4, 5 & 6, multiple pieces of plastic were found in situ.**(Fig.5&6)** On reflection scalp extravasations of blood was seen all over. Multiple fracture present of the left parietal bone with effusion of blood present along the fracture line. **(Fig.7)**Brain weight was 1226 grams, gyri were flattened and sulci were obliterated. Hemorrhagic contusion was present on the basifrontal region of left cerebral hemisphere. Subarachnoid hemorrhage was present all over the brain parenchyma**. (Fig.8)**Cause of death was coma due to cerebral damage as a result of blunt force impact to head.

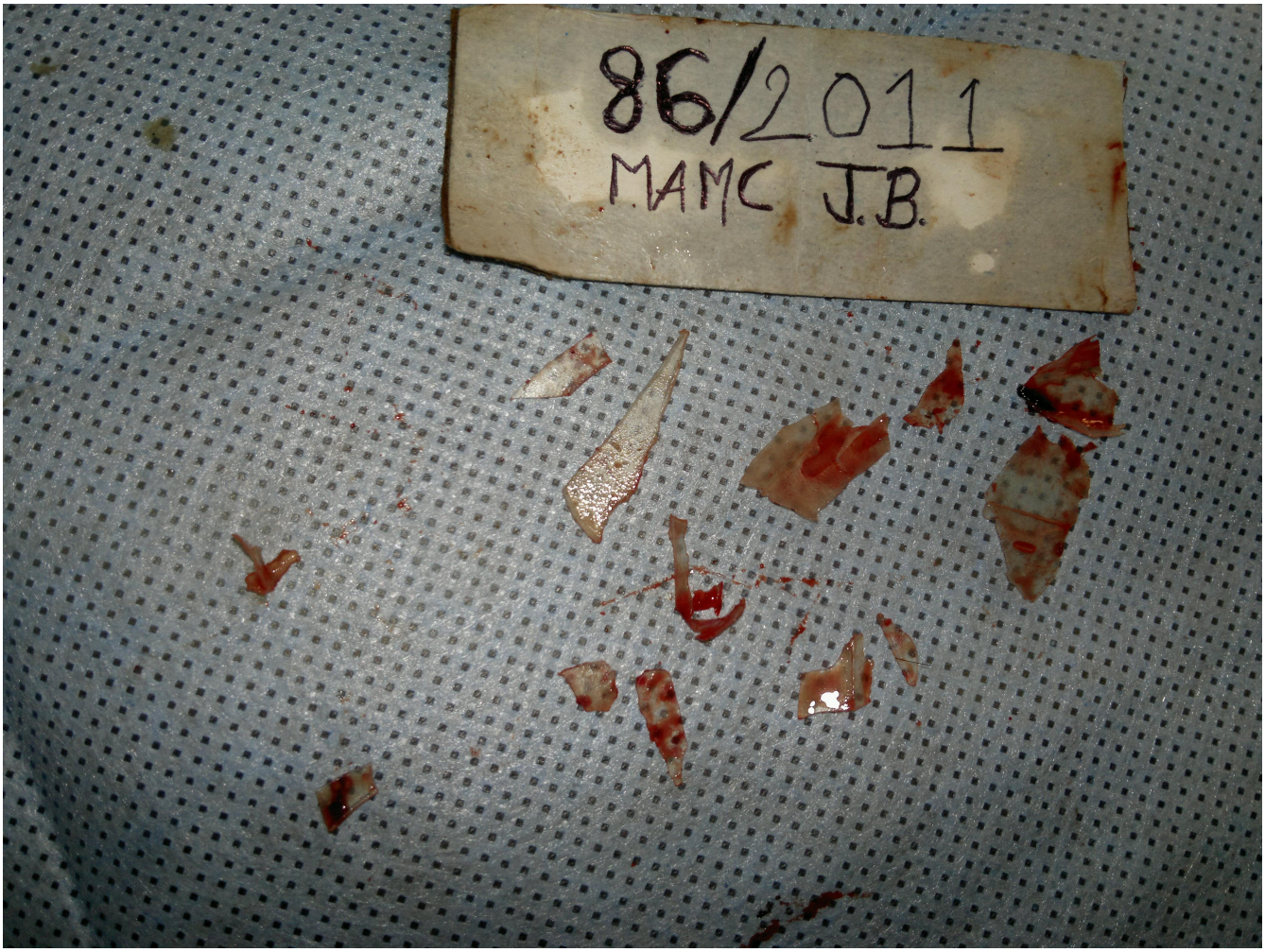
86/2011
MAMC J.B.



Fig. 5. Plastic pieces removed from wound. **Fig. 6.** Multiple Skull fracture.

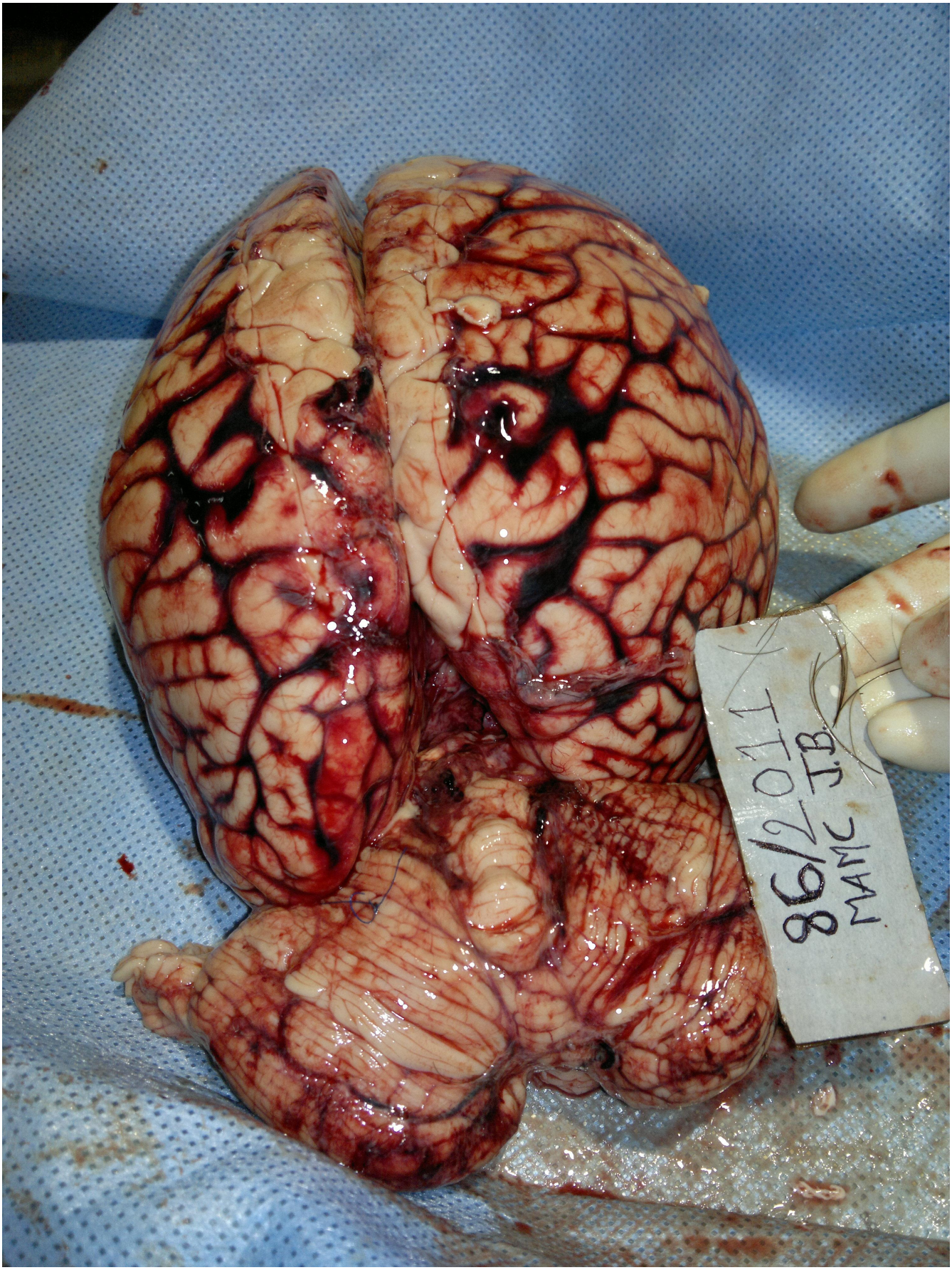

Fig. 7. Subarachnoid haemorrhage.

Discussion

Death due occupational trauma is well known and the common causes are like vehicular accident, falls from a roof, machinery, electrocutions and falling objects. Machinery-related fatalities are one of the leading causes[1]. Out of 153 fatal occupational deaths, machinery-related incidents reported in 5 (3.3%) cases in construction sector of Turkey[2].According to National Crime Record Bureau(NCRB) India report 2009, there were 1044 cases of Factory/Machine Accidents deaths reported, which constituted about 0.3% of all accidental deaths. The report also indicated that the share of causes not attributable to nature like Factory/Machine Accidents deaths increased in comparison to previous year. Death due to machine accidents commonly seen in workplaces such as primary industry, agriculture, construction, forestry, fishing, mining, and transportation/ communications/utilities industries etc.

In our case the plastic grinder machine described was used in a recycling industry. The machine was a locally assembled one. Unaware of the presence of a worker inside the machine, the person switched on the motor. The high speed blades of the fans sustained multiple blunt injuries to the head and lower limb. The fragmented pieces of the plastic material pierced into the body of the deceased which was found in situ at autopsy. The rotating fan blade became hot which caused contact burn injuries. This type of case has been rarely reported in forensic literature. A worker at an upstate New York lumber company was killed when a colleague mistakenly turned on a cutting machine while he was changing the blades on the equipment[3].

Faulty make of the machine and the carelessness of the workers mainly contribute to occurrence of such incident. It does not adhere to the laid down specifications for safety measures. Hence precautions must be taken during work, and installation of safety measures should be placed at workplace.

References

1. Giovanni Cecchetto, Guido Viel, Federica De Lotto, Renzo Manara, Massimo Montisci, Silvano Zancaner,S. Davide Ferrara.Machinery-Related Deaths: Relevance of Workplace Investigation and antemortem Radiological Data in Reconstructing the Fatality. J Forensic Sci, May 2010, Vol. 55, No. 3, page 845-8.
2. Basar Colak, Nilay Etiler, Umit Bicer. **.**Fatal Occupational Injuries in the Construction Sector in Kocaeli, Turkey, 1990–2001. Industrial Health 2004, 42, 424–430.
3. http://www.reuters.com/article/2011/02/07/us-death-lumber-idustre7165lg2011027?feedtype=rss&feedname=domwsticnews

   Note - This paper has been published in "*Anil Aggrawal's Internet Journal of Forensic Medicine and Toxicology*". **URL of journal** - http://anilaggrawal.com/ij/indexpapers.html **URL of Paper** - http://anilaggrawal.com/ij/vol_014_no_002/papers/paper001.html