ANIL AGGRAWAL'S
Internet Journal of Forensic Medicine and Toxicology
The world's first online journal devoted entirely to forensic medicine and toxicology · Published 1 January and 1 July

VOL. 14, NO. 1
Downloaded from www.anilaggrawal.com · ISSN 0972-8074 (Online) · https://www.anilaggrawal.com/ij/vol_014_no_001/poster/poster008.html

Poster Session: Poster 8

CITE THIS ARTICLE
Gupta BD, Desai NJ, Patel JB, Bhanvadia V. Thromboembolism. *Anil Aggrawal's Internet Journal of Forensic Medicine and Toxicology, 2013*; Vol. 14, No. 1 (Jan - June 2013): ; Published: Jan 1, 2013,

Email Dr. B.D.Gupta (the corresponding author) by clicking here

Dr. B.D. Gupta (Click to enlarge)



Thromboembolism

B. D. Gupta*[*], M.B.B.S., M.D., Prof & Head, N.J. Desai[#], M.B.B.S., M.D. Professor, Jignesh B. Patel[*], M.B.B.S., Viral Bhanvadia[#], M.B.B.S., M.D. Assistant Professor
**** Forensic Medicine Department***
 # Pathology Department

M.P.Shah Medical College, Jamnagar
India

Picture 1: thromboembolism as dissected in situ.

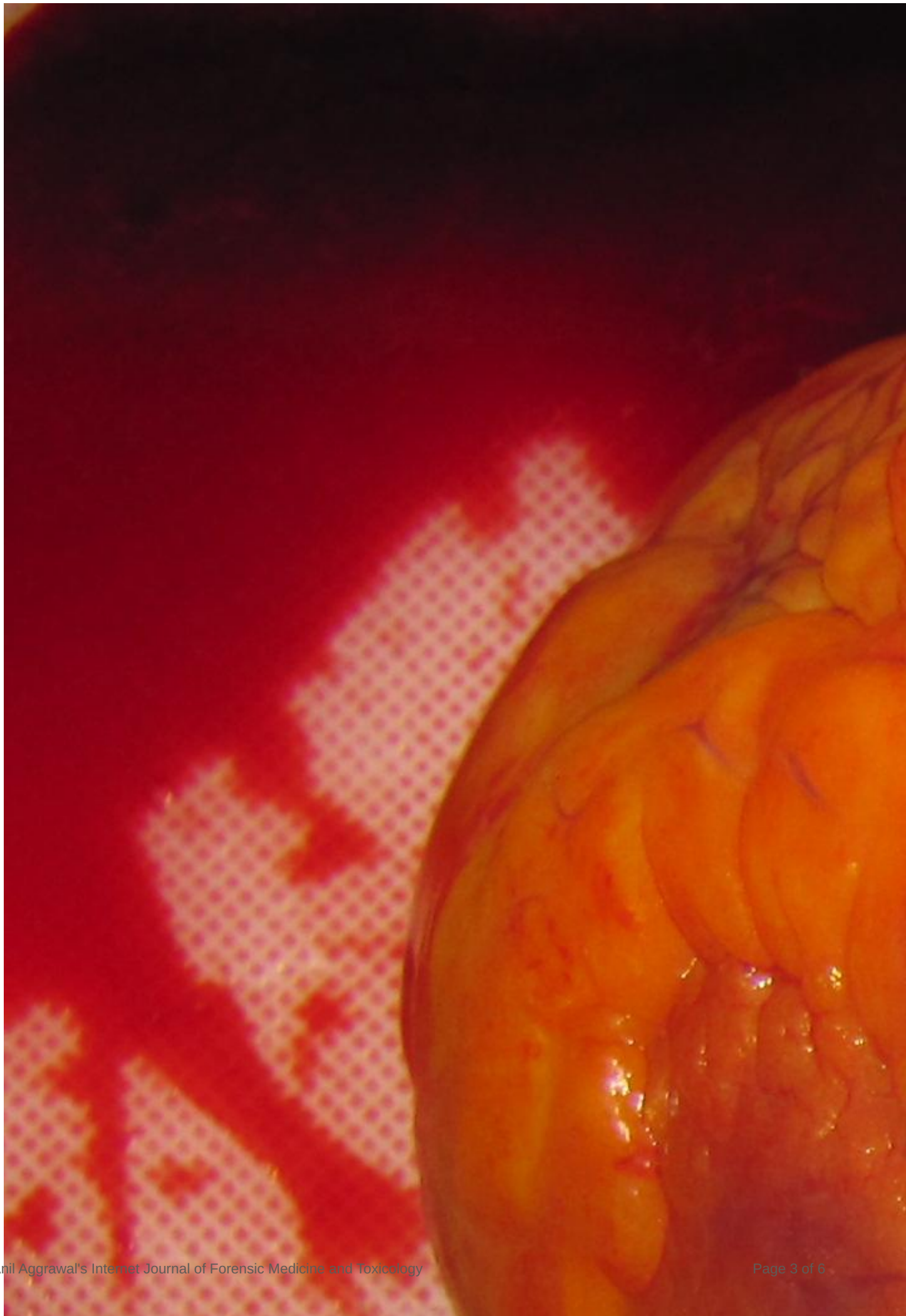

Picture 4: High power view. Photograph is 34% zoomed using Microsoft Picture Manager

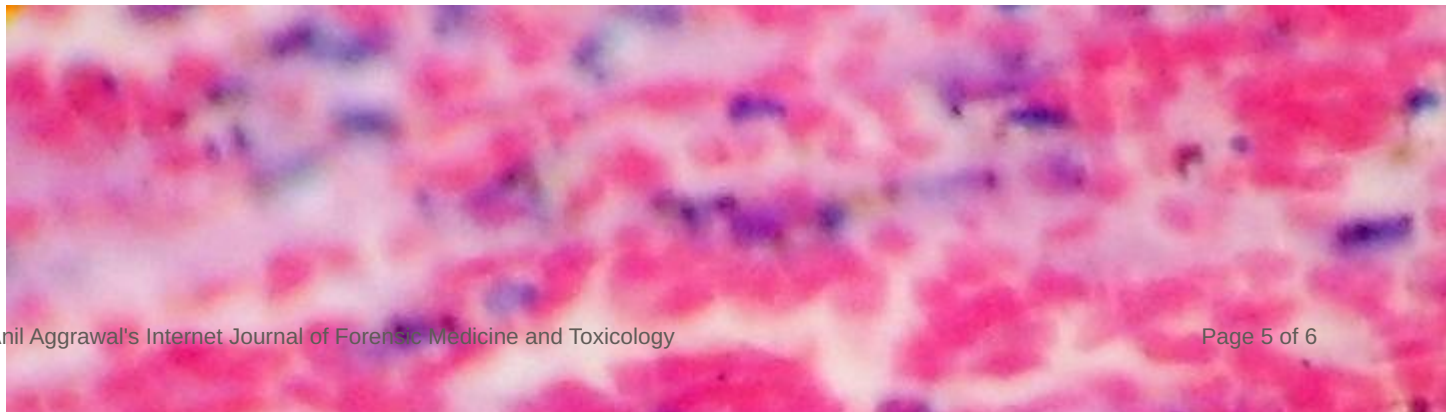

Please click all pics to enlarge

Deceased was female of about 65 years of age. She suffered multiple fractures in a vehicular accident including fractures of bones of left leg. Patient was under treatment for about two weeks. She was operated upon twice. But she died after 8 days of second operation. On postmortem examination we found thromboembolism in pulmonary trunk. Gross and microscopy photographs are presented.

(N.B. Click all pictures to enlarge!)

*Corresponding author and requests for reprints:
B.D. Gupta
Professor of Forensic Medicine
M.P.Shah Medical College
Jamnagar 361008
India

[Poster 1] [Poster 2] [Poster 3] [Poster 4]
[Poster 5] [Poster 6] [Poster 7] [Poster 8]

[Back to Poster Index]

Questions or suggestions ? Please email to anil@anilaggrawal.com