ANIL AGGRAWAL'S

Internet Journal of Forensic Medicine and Toxicology

The world's first online journal devoted entirely to forensic medicine and toxicology · Published 1 January and 1 July

VOL. 14, NO. 1

Downloaded from www.anilaggrawal.com · ISSN 0972-8074 (Online) · https://www.anilaggrawal.com/ij/vol_014_no_001/poster/poster003.html

Poster Session: Poster 3

CITE THIS ARTICLE

Gupta B.D. and Patel J.B. Artefact mimicking injury. *Anil Aggrawal's Internet Journal of Forensic Medicine and Toxicology, 2013*; Vol. 14, No. 1 (Jan - June 2013): ; Published: Jan 1, 2013,

Email Dr. B.D.Gupta (the corresponding author) by clicking here

Dr. B.D. Gupta (Click to enlarge)



Artefact mimicking injury

B. D. Gupta [*] ***and Jignesh B. Patel*** [* *]

**** Prof & Head, **Tutor***

Forensic Medicine Department

M.P.Shah Medical College, Jamnagar
India

Case Report

Picture 1: Long transverse purplish bands on the back, mimicking railway track bruises

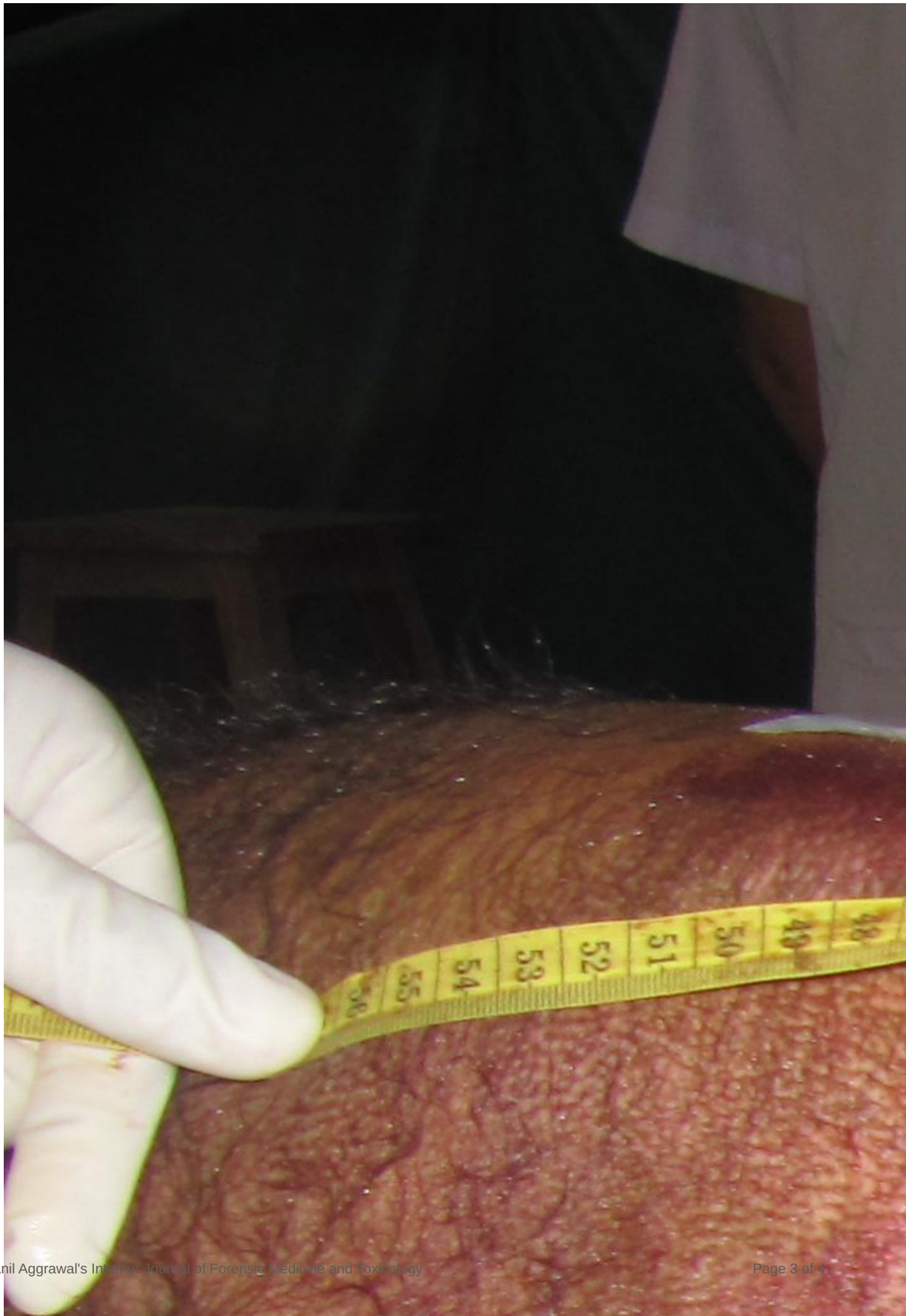
49
50
51
52
53
54
55

Please click all pics to enlarge

It was a case of vehicular accident. There was a collision between bullock cart and tractor. The deceased was on bullock cart. He fell down and the tractor ran over him.

On examination we found that there were injuries consistent with the history of accident and sufficient to cause death. But we found one unusual finding- see photograph-1. Photograph-2 is a closer view of the photograph-1. There were long transverse purplish bands on the back. They were mimicking like patterned bruises. But the cause of these marks was not forth coming. On inquiry we found that body was kept in cold room on one new 'Lungi'.(Lower garment of males, reasonably famous all over India)Photograph-3.

Possible explanation was that due to moisture of cold room the *Kuchha* [color improperly fixed to cloth] color of one of the designs in lungi became moist and because of body weight it got printed on the body. But still there is a twist in the tale. See the purple color design which is in the form of rectangle checks. Still, only transverse bands got imprinted on the body but not the longitudinal ones. Any suggestions?

(N.B. Click all pictures to enlarge!)

*Corresponding author and requests for reprints:
B.D. Gupta
Professor of Forensic Medicine
M.P.Shah Medical College
Jamnagar 361008
India

[Poster 1] [Poster 2] [Poster 3] [Poster 4]
[Poster 5] [Poster 6] [Poster 7] [Poster 8]

[Back to Poster Index]

Questions or suggestions ? Please email to anil@anilaggrawal.com