ANIL AGGRAWAL'S
Internet Journal of Forensic Medicine and Toxicology
The world's first online journal devoted entirely to forensic medicine and toxicology · Published 1 January and 1 July

VOL. 14, NO. 1 · JANUARY – JUNE 2013
Downloaded from www.anilaggrawal.com · ISSN 0972-8074 (Online) · https://www.anilaggrawal.com/ij/vol_014_no_001/papers/paper007.html

Death Due To Spinal Cord Injury Consequent To Accidental Fall-A rare case of SCIWORA

Basant Lal Sirohiwal, P. K. Paliwal, Vijay Pal Khanagwal, Yogesh Kumar, Ishwar Singh

Professor, Department of Forensic Medicine, Pt. BD Sharma, University of Health Sciences, Postgraduate Institute of Medical Sciences, Rohtak, Haryana 124001, India
Senior Professor & Head, Department of Forensic Medicine, Pt. BD Sharma, University of Health Sciences, Postgraduate Institute of Medical Sciences, Rohtak, Haryana 124001, India
Resident, Department of Forensic Medicine, Pt. BD Sharma, University of Health Sciences, Postgraduate Institute of Medical Sciences, Rohtak, Haryana 124001, India
Associate Professor & Head, Department of Neurosurgery, Pt. BD Sharma, University of Health Sciences, Postgraduate Institute of Medical Sciences, Rohtak, Haryana 124001, India
Contact: Basant Lal Sirohiwal · drbasantsri@gmail.com

CITE THIS ARTICLE

Sirohiwal BL, Paliwal PK, Khanagwal VP, Kumar Y, Singh I. Death Due To Spinal Cord Injury Consequent To Accidental Fall-A rare case of SCIWORA. *Anil Aggrawal's Internet Journal of Forensic Medicine and Toxicology* [serial online], 2013; Vol. 14, No. 1 (January – June 2013): [about 6 p]. Available from: https://www.anilaggrawal.com/ij/vol_014_no_001/papers/paper007.html

ABSTRACT

Usually the patients with spinal cord injury are attended mainly by the orthopaedician and neurosurgeon not only for treatment purposes but also for disability certification and a forensic expert is asked to give opinion in criminal cases regarding the nature of such injuries during life and cause of death afterwards. Here we are reporting a case of death of an adult male of spinal cord injury without radiological abnormal findings resulting from fall on his back on a wooden plank while working in his fields as a routine chore and subsequently died during treatment.

Spinal cord injury occurring without concomitant radiological demonstrable trauma to the skeletal elements of the spinal canal rim, or compromise of the spinal canal rim without fracture, is a rare event. Though documented in children, the injury is not very well reported in adults. The physical, personal, financial and social impact of spinal cord injury is such that most patients are lost in follow up or succumb to life-threatening complications associated with spinal cord injury. However, inadequate precautions during transportation can cause further injury to the already compromised spinal cord in spinal injured patients.[1, 2]

Keywords: SCIWORA, Spinal Cord, Blunt trauma due to fall

Brief history – on one evening of mid august of 2011, 40 years old male individual, farmer by occupation, was watering his fields, and as he walked bare foot across the water canal then he slipped backwards and hit his head and neck on a wooden plank (used in the fields to level the earth) lying nearby. After sustaining blunt force impact of wooden plank he became unconscious. He was taken to a private hospital in the nearby town from where he was shifted to a district level neuro-care and trauma research hospital. During the conservative management the patient condition got deteriorated so he was referred from the peripheral hospital to tertiary care hospital at Postgraduate Institute of Medical Sciences, Rohtak, Haryana, India for further management. However, the patient was declared as 'brought dead' at casualty. The post mortem examination was conducted in the department of Forensic Medicine.

Clinical profile: - the patient remained under conservative treatment for 3 days with an orthopaedician at neuro-care and trauma research hospital with the diagnosis of cervical spine injury (SCI) with head injury (HI), seizures and quadriplegia. The biochemistry of the blood was within normal limits.

Radiological investigation:- there was no significant abnormality detected on plain radiograph and CT scan except mild degenerative changes in the cervical spine; However, the MRI revealed the cord oedema at C7 vertebral body level with anterior displacement of C6 over C7 leading to thecal sac compression & cord compression and associated pre-vertebral and para-spinal hematoma.

Post-mortem observations

The post-mortem examination of this young adult male was conducted after about 18 hours of pronouncement of death; rigor mortis was found present all over the body; post-mortem staining was appreciated over the dependent parts of the body except the pressure areas; the eyes were closed and mouth was open with front teeth visible. A tracheostomy wound was present. During autopsy no external injury was appreciated over the back of the neck and thoracic region of the body (Fig-1 & 2). However, on midline dissection of vertebral column of the neck and upper thoracic region extravagation of blood was appreciated around the spines of 4th, 5th, 6th and 7th cervical vertebrae including surrounding muscle tissues. On removal of para-spinous tissues and structure around the 6th and 7th cervical spines, the dislocation of vertebrae between them was observed (Fig-3 & 4). On further removal of spines of cervical vertebrae there was presence of clotted blood outside the dura matter more so around the 5th, 6th and 7th cervical vertebrae region (Fig-5). The spinal cord meninges were looking bluish in colour (Fig-6). On dissection of the layers underneath extravasations of blood was appreciated more so on the upper aspect where the spinal cord was found to be softened around the level of 4th and 5th cervical vertebrae in an area of about 2cm with hemorrhagic spots (Fig-7& 8). This dissected part of the spinal cord was sent for histopathological examination that revealed congestion in it. The quadriplegia as mentioned in the clinical notes was probably consequent upon these internal damages. The internal structures in all other cavities were found to be grossly within normal limits. Medico-legally, the cause of death in this case was defined as spinal cord injuries and their complications that were ante mortem and could be caused in the manner alleged in the history.

Reconstruction of fall: before we consider the fall the various movements of the neck that may prove fatal are to be taken in to knowledge. Thus from the functional point of view, the upper two cervical vertebrae provide most of the rotational movements and the lower five, flexion and extension. Therefore, when this subject had slipped on his back he might have fallen in such a way

that there would have been hyper-flexion and hyper-extension movements of the spinal column resulting into the injury of the spinal cord and consequently death.

Discussion: - Spinal trauma is a common cause of disability, with approximately 50 000 persons suffering from spinal injury in the USA each year. It is predominantly an affliction of the young, with 80% occurring below the age of 40. Spinal injuries are common in multi trauma predominantly from motor vehicle accidents. Cervical spine injury occurs in over 20% of such cases.[3] Whenever a living subject of spinal injury brought to a hospital the radiological investigations are carried out for knowing the lesions. Clinically, in the instant subject no abnormality was detected in the plain radiographs and CT scan examination but the MRI revealed important finding suggestive of mechanical trauma. Such types of lesions have been described as the "spinal cord injury without radiological abnormality (*SCIWORA*). It has been reported as a syndrome of cervical spinal cord trauma, describing post traumatic myelopathy without evidence of vertebral fracture or mal-alignment on plain radiographs or on computed tomography**.** The injury is documented in children, probably due to increased elasticity of the pediatric spine. Inherent elasticity of the vertebral column due to ligamentous laxity, combined with the large head size predisposes the pediatric cervical spine to deforming forces. Pang described four mechanisms of *SCIWORA* viz. flexion, hyperextension, longitudinal distraction and ischemia. [4]

Advent in radiology changed the concept of *SCIWORA*: - *SCIWORA* acronym was coined by Pang and Wilberger in 1982 to denote presence of clinical findings (neurological deficit) in the setting of normal X Rays and Computerized Tomographic (CT) Scan. The advent of Magnetic Resonance Imaging (MRI) has made it possible to accurately characterize the underlying spinal cord injury even when radiographs and CT scan are normal as has been observed in our subject. In view of these advances, Pang reviewed his work in 2004 and advocated that only cases with neural injuries seen on MRI or those with normal MRI findings should be counted as *SCIWORA* and purely extra neural compressive lesions should be excluded from the definition of *SCIWORA*.[5]Adult *SCIWORA* is a rare phenomenon and not much is known about its exact pathophysiology. MRI has helped identify the subtle spinal cord parenchymal abnormalities and ligamentous disruptions. Liao et al described four patterns of parenchymal cord injuries viz. concussion, oedema**,** contusion and transaction.[6]We have observed that in the instant subject cord oedema at C7 vertebral body level with anterior displacement of C6 over C7 leading to thecal sac compression and cord compression and associated pre-vertebral and para-spinal hematoma was detected in MRI; whereas haemorrhages along with softening of the cord was noticed by us during the post-mortem examination and the same was reported in literature as areas of hemorrhagic discolorations on the surface or in the substance of cord, or there may be sub-thecal effusion of blood.[7]

Causes of spinal cord injury: Although the brain and spinal cord seem to be well protected within a bony encasement, they are sensitive organs, highly susceptible to injury. The flexibility of the vertebral column is essential for body movements, but because of this flexibility the spinal cord and spinal nerves are somewhat vulnerable to trauma. Falls or severe blows to the back are a common cause of injury. A skeletal injury, such as a fracture, dislocation, or compression of the vertebrae, usually traumatizes nervous tissue as well. Other frequent causes of trauma to the spinal cord include gunshot wounds, stabbings, herniated discs, and birth injuries.[8] Spinal cord can be injured by penetrating wounds, by fracture and fracture dislocation of vertebrae. The common sites of injury to the cord in order of frequency are: the lower cervical region, the thoraco-lumbar

region, and the upper cervical region. Momentary dislocation of spine may occur especially in the cervical region, causing crushing of cord, followed by self reduction.[7]

The pathophysiology of adult *SCIWORA* is quite different from that of paediatric population. Most cases are due to hyperextension injury to the spine, which may be seen in rear end motor vehicle collisions or direct anterior craniofacial trauma as observed in this subject.

Spinal damage may be caused by compressional, hyper-flexion and hyperextension stress. Hyperextension is more dangerous in causing spinal injury. These are generally accidental occasionally homicidal and rarely suicidal. [9]

Conclusion: - During autopsy the spinal cord is examined whenever there had been clinical indication of the same and not an otherwise routine procedure but when it is examined the complete clinical findings ought to be correlated while registering the cause of death medico-legal point of view; However, to state here that spinal cord injury, which often results in permanent paralysis, is one of the most serious forms of trauma experienced by man [10] and autopsy surgeon rarely open the spinal cord in exceptional cases so this case is being discussed because of its being a rare occurrence.





Fig. 1 and 2. Grossly no injury appreciated over external surface except the extravassation of blood in paraspinal muscle.

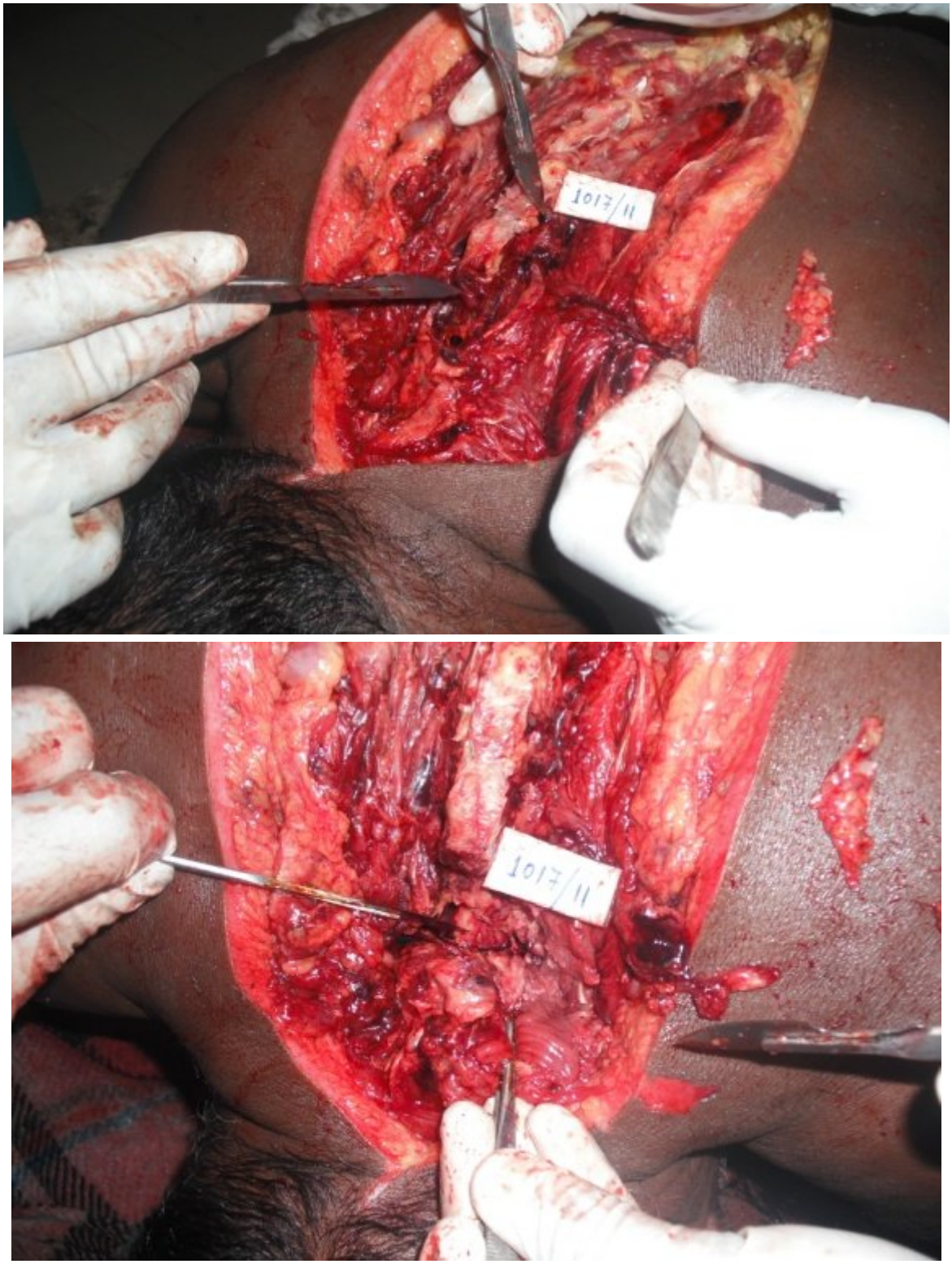

Fig. 3 and 4. Dislocation was found between 6th and 7th cervical vertebrae.

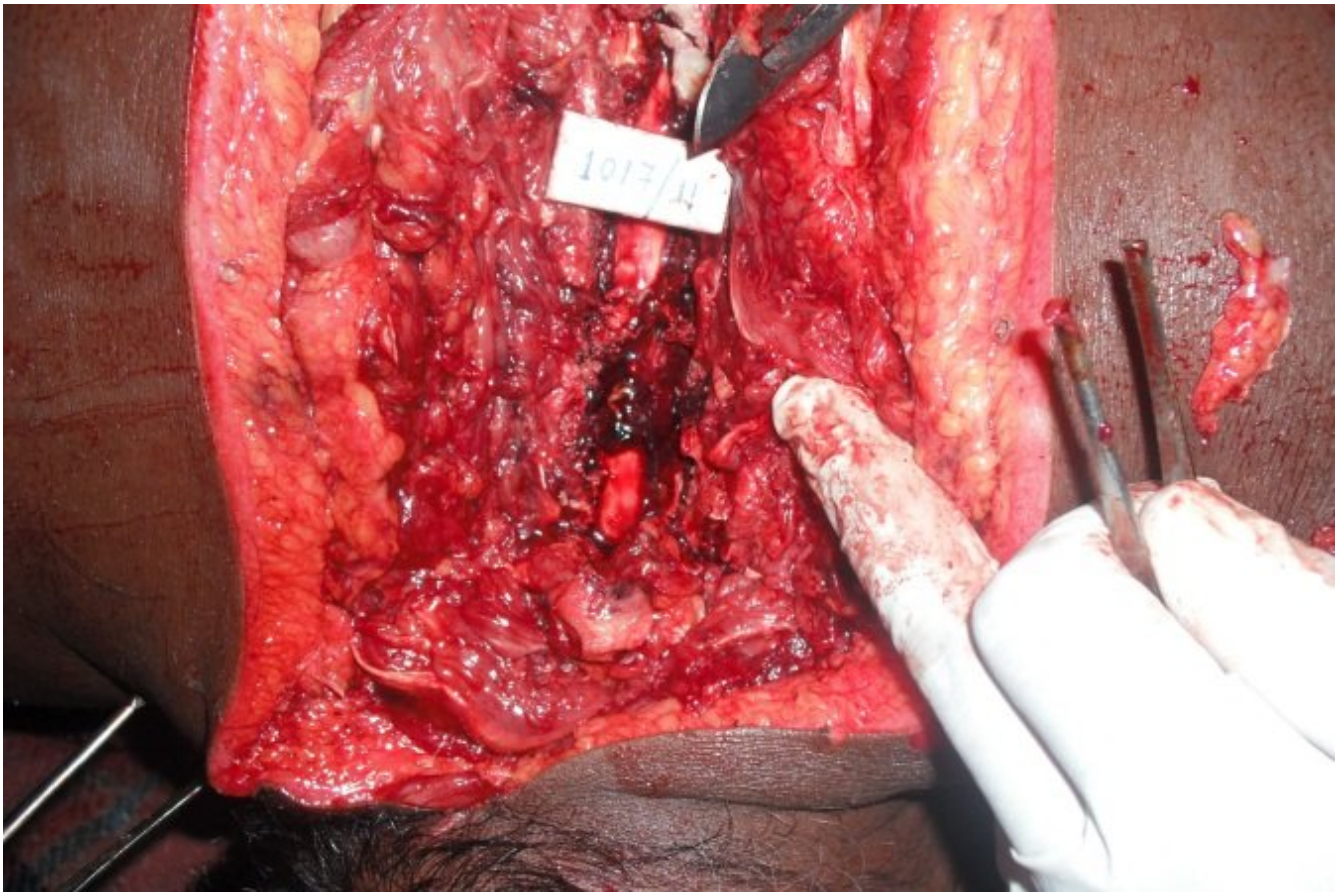

Fig. 5. After removal of the spines the clotted blood was noticed outside the dura-matter at the level of 5th, 6th, 7th cervical vertebrae.

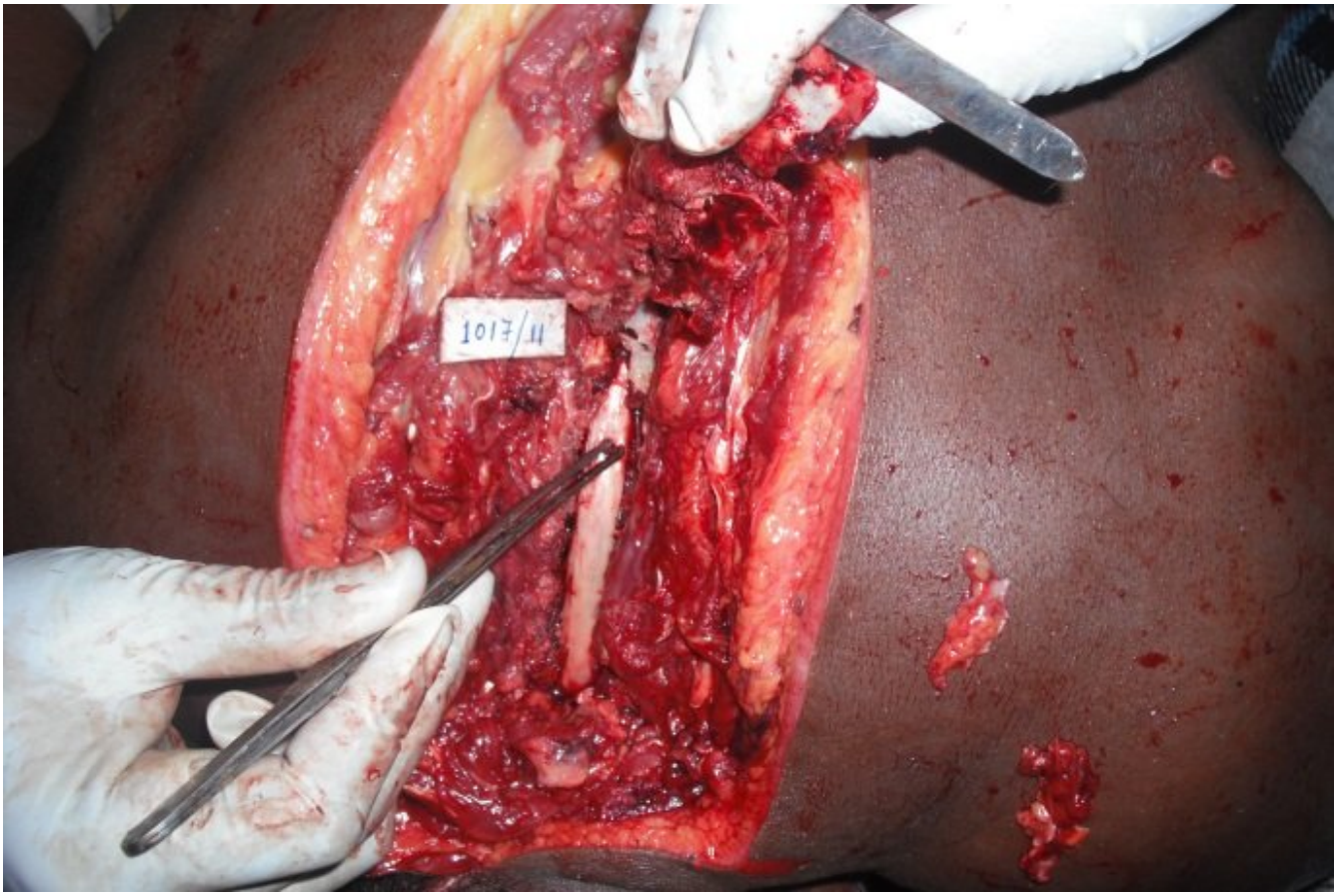

Fig. 6. The meninges were reflecting bluish hue after cleaning the clotted blood.

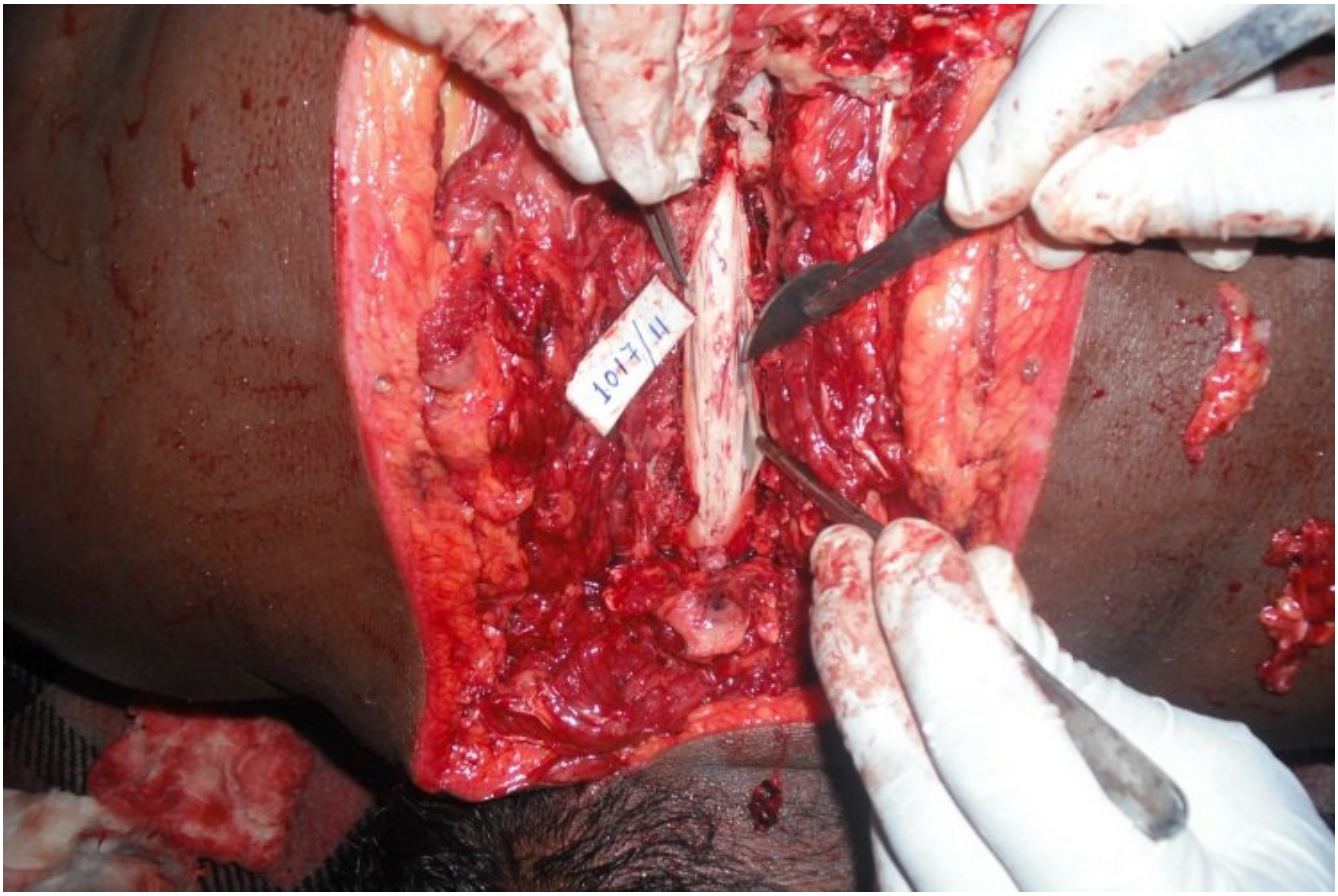

Fig. 7. Haemorrhagic spots were present under the meninges on the spinal cord.



Fig. 8. The dissected part of spinal cord was softened and having haemorrhages internally.

References

1. Transportation of patients with acute traumatic cervical spine injuries. Neurosurgery 2002; 50:S18-20.
2. Burney RE, Waggoner R, Maynard FM. Stabilization of spinal cord injury for early transfer. J Trauma.1989; 29:1497–9.
3. Sutton D. Textbook of radiology and imaging 7th ed Churchill Livingstone: Elsevier Science Ltd; 2003.p. 1391.
4. Pang D, Wilberger JE, Jr. Spinal cord injury without radiographic abnormalities in children. J Neurosurg 1982;57(1):114-129.
5. Pang D. Spinal cord injury without radiographic abnormality in children, 2 decades later. Neurosurgery 2004;55(6):1325-1342;
6. Liao CC, Lui TN, Chen LR, Chuang CC, Huang YC. Spinal cord injury without radiological abnormality in preschool-aged children: correlation of magnetic resonance imaging findings with neurological outcomes. J Neurosurg 2005;103(1 Suppl):17-23.
7. Reddy KSN. The Essentials of Forensic Medicine and Toxicology. 30th ed. Hyderabad: Om Sai Graphics; 2010. p.243.
8. Marshal K, Graaff VD: Human anatomy. 6th ed. Boston : The McGraw–Hill Companies ;2001 .p. 407.
9. Mathiharan K, Kannan K. Modi A Text Book of Medical Jurisprudence and Toxicology. 24th ed. Lexis Nexis Butterworths Wadhwa:Nagpur;2012.p.595
10. Bracken MB, Freeman DH, HallenBrand K. Spinal Cord Injury 1970-77. Am. J. Epidemiol. Vol. 113;June 1981. No.6 .p.615.