ANIL AGGRAWAL'S
Internet Journal of Forensic Medicine and Toxicology
The world's first online journal devoted entirely to forensic medicine and toxicology · Published 1 January and 1 July

VOL. 12, NO. 2 · JULY – DECEMBER 2011
Downloaded from www.anilaggrawal.com · ISSN 0972-8074 (Online) · https://www.anilaggrawal.com/ij/vol_012_no_002/papers/paper001.html

Death – who caused it? Wild boar or Doctor – Case Report

Rajendra Kumar. R[1], Chandru. K[2]

[1]Associate Professor, Department of Forensic Medicine, Sree Siddhartha Medical College, Agalkote, Tumkur - 572107, Karnataka, India

[2]Assistant Professor, Department of Forensic Medicine, Sree Siddhartha Medical College, Agalkote, Tumkur - 572107, Karnataka, India

Contact: Rajendra Kumar. R · brrk72@yahoo.co.in

CITE THIS ARTICLE

Rajendra Kumar R, Chandru K. Death – who caused it? Wild boar or Doctor – Case Report. *Anil Aggrawal's Internet Journal of Forensic Medicine and Toxicology* [serial online], 2011; Vol. 12, No. 2 (July – December 2011): [about 6 p]. Available from: https://www.anilaggrawal.com/ij/vol_012_no_002/papers/paper001.html

ABSTRACT

Man has to work for his livelihood, whatever may be his age and place of work, during which sometimes he suffers injuries as a result of his or others negligence or because of nature. This is a case of a man working in agricultural field near forest area who suffers injuries as a result of unprovoked wild boar attack and taken to hospital for treatment. After investigations and treatment sent home, but came back within 12 hours to die in hospital.

Keywords: injuries; investigations; negligence; wild boar attack

Introduction

People in rural areas near forests live in constant danger of being attacked by wild animals. Man is exposed to such risks everyday during his work in agricultural fields.[1] We present one such case where a man is attacked unprovoked by a wild boar,[2,3] and visits the hospital with the hope that doctors will cure him. The treating doctor & trainee radiologist failed to diagnose properly or give proper advice & treatment which leads to his death.

Case Report

A male aged 78 years was brought to the causality with the history of attack by wild boar, while he was working in the agricultural field near forest area, on 13/07/2009, around 5 PM with the following complaints:

History

A Lacerated wound over right & left thigh, medial aspect due to an attack by wild boar, and pain abdomen.

Local examination

There was a lacerated wound, 6 cm over medial aspect of left thigh and another lacerated wound 5 cm over medial aspect of right thigh.

Abdominal examination

Diffuse tenderness over the abdomen was present.

Investigations

Ultrasonography of abdomen was unremarkable except prostatomegaly.

Treatment and Outcome

Suturing was done. In addition intravenous fluids and tetanus toxoid were given. The patient was sent back. But returned next day in the morning around 7 am with aggravated complaints of severe pain abdomen, acute retention of urine & constipation, and difficulty in respiration. On examination, the patient was conscious & oriented. His blood Pressure was 110/70 mm Hg, pulse was 96/min. On abdominal examination, diffuse tenderness was noted. Around 10:30 am the patient was declared dead. The cause of Death was given as septicemic Shock with peritonitis.

PostMortem Findings

External

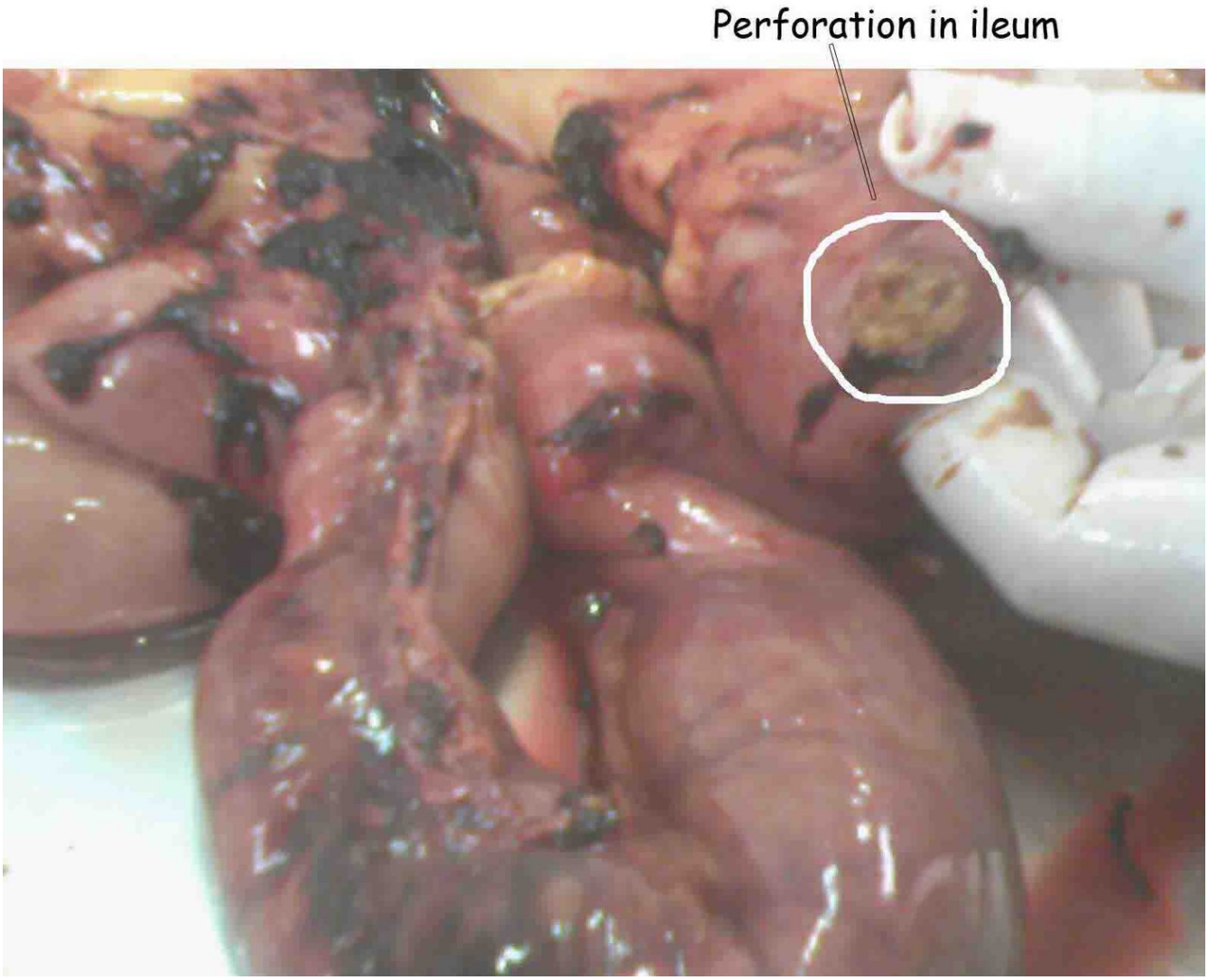

Figure 1. Perforation in ileum.

1. Sutured wound measuring 7cms in length present over lower third of left thigh on its inner side 6cms above left knee joint, on removal of sutures it was a lacerated wound, margins irregular, measuring 7cm x 2cm x muscle depth.

2. Sutured wound measuring 5cms in length present over lower third of right thigh on its inner side 7cms above right knee joint, on removal of sutures it was a lacerated wound, margins irregular, measuring 5cm x 2cm x muscle depth.

3. Impact abrasion over right pubic region measuring 5cm x 2.5cm.

Internal

On reflection of the abdominal wall, extravasation of blood was seen over right side of lower abdominal wall. Peritoneal cavity contains 2500ml of blood & blood clots. Blood extravasation was seen over intestinal walls & mesentery. Other significant findings were:

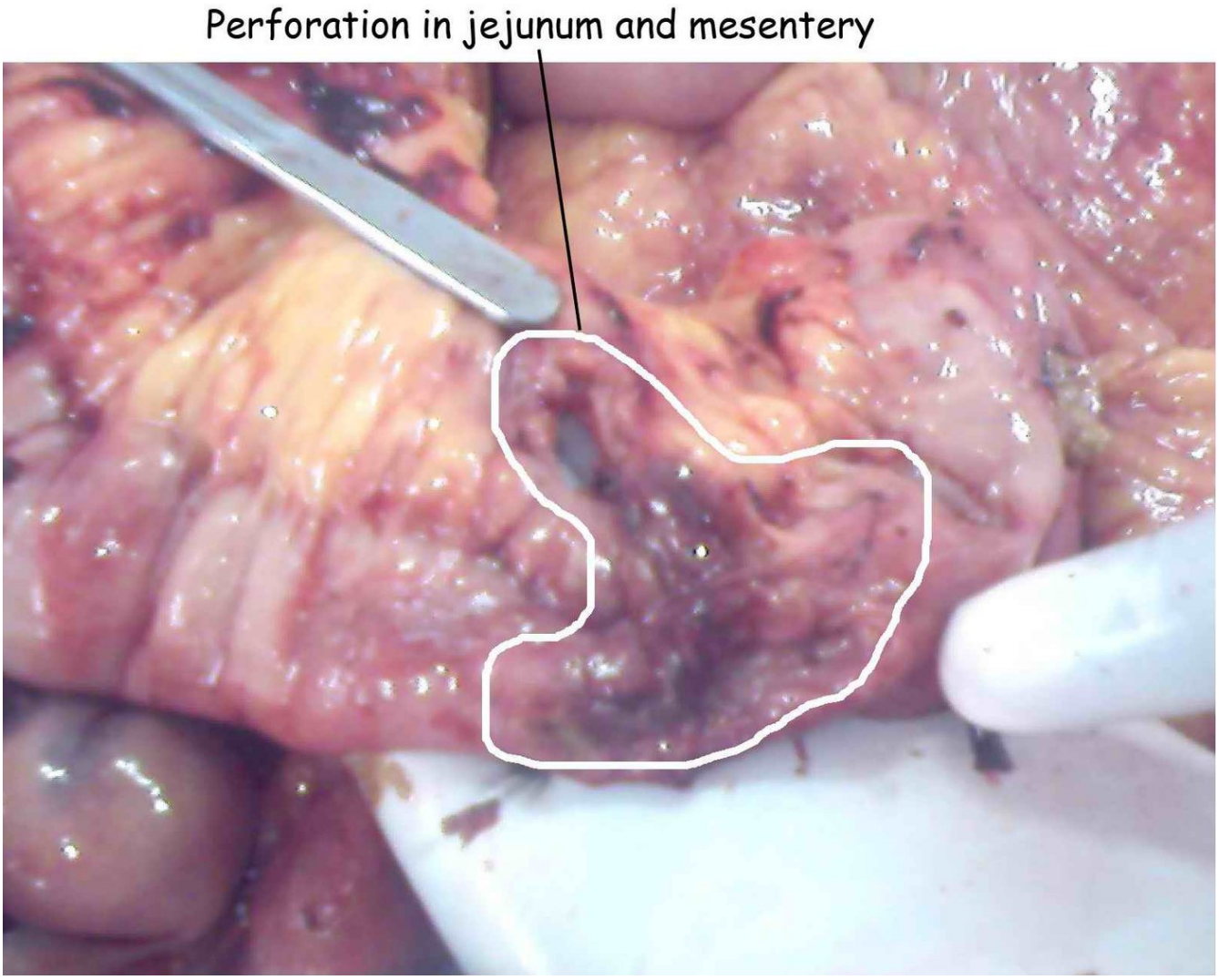

Figure 2. Perforation in jejunum and mesentery

1. Perforation of 1cm x1cm present over ileum situated 20 cms above ileo-ceacal junction.

2. Another perforation of 2cm x 1.5cm present over jejunum 180cm above injury no.1.

3. Another perforation of 1cm x 1cm present over mesentery just 1.5cm to left of injury no. 2.

Discussion

The deceased was attacked by an unprovoked wild boar & such attacks are often associated with penetrating injuries over the lower extremities[1,4] and blunt injury to abdomen.[4,5] In this case, the deceased sustained lacerated injuries over lower extremities[4] and blunt trauma to abdomen[4,5] and was brought for treatment immediately.

Casualty doctor and the trainee radiologist failed to diagnose properly and the patient was treated as usual. This being a medicolegal case, the doctor has failed to note down injuries with proper measurements, which show how casual the doctor was. Even if there was no perforation at the time of initial examination, the patient should have been kept for observation as there are chances of delayed perforation[6] in blunt abdominal trauma. Here the Patient was not kept for observation, but sent home without proper advice. Patient came back within 8 - 10 hours of treatment with aggravated symptoms and died after 3 hours in hospital.

Doctors had got a second chance to treat the patient when he visited the hospital for second time with aggravated symptoms, but the casualty doctor waited, managing conservatively.

At postmortem it was revealed there was small intestinal and mesenteric perforation[5,6] and blood in peritoneal cavity. If emergency laprotomy had been done then patient might have survived.

Conclusion

Even with advances in medical technology and investigations, at times treating doctors fail to diagnose fatal condition in the patients, which can lead to death as seen in this case. Doctors should take necessary care and not be casual while treating patient to avoid negligence on their part.

If doctors know their duties, medical ethics, responsibilities and act accordingly such deaths may be prevented.

The public should be educated via media; of the doctor duties, responsibilities, the consumer protection act and compensation available in such incidents.

References

1. Manipady S, Menezes RG, Bastia BK. Death by attack from a wild boar: *Journal of Clinical Forensic Medicine*. 2006 Feb: 13(2); 89-91.
2. Wild Boar. In: Encyclopedia of the Animal world. Vol 21. London UK: Sydney Bay Book; 1972: 1948 – 49.
3. Wild Boar. Available at: http://en.wikipedia.org/wiki/wild_boar. Accessed on September 13, 2009.
4. Gundaz A, Turedi S, Nuhoqlu I, Kalkan A, Turkmen S. Wild boar attack. *Wilderness Environ Med.* 2007: 18(2); 117-119.
5. Dogan KH, Demirci S, Erkol Z, Sunam GS, Kucukkartallar T. Injuries & death occurring as a result of bull attack. *Journal of Agro Medicine*. 2008 Oct: 13(3); 191-196.
6. Sule AZ, Kidmas AT, Awani K, Uba F, Misauno M. Gastro intestinal perforation fallowing blunt abdominal trauma; *East Afr Med Jour*. 2007 Sep: 84(9); 423 – 433.