ANIL AGGRAWAL'S
Internet Journal of Forensic Medicine and Toxicology
The world's first online journal devoted entirely to forensic medicine and toxicology · Published 1 January and 1 July

VOL. 11, NO. 2 · JULY – DECEMBER 2010
Downloaded from www.anilaggrawal.com · ISSN 0972-8074 (Online) · https://www.anilaggrawal.com/ij/vol_011_no_002/papers/paper002.html

The Venous Sinus Appears To Be a Source of Pulmonary Thrombosis

Katsuji Nishi, Ikuo Sakaguchi, Tokiko Nakagawa, Shiho Naitoh, Naoki Takaka, Ai Hirano, Izumi Takase, Yoshio Yamamoto

Department of Legal Medicine, Shiga University of Medical Science, Setatukinowa-cho, Ohtsu 520-2192, Shiga, Japan

Contact: the corresponding author Katsuji Nishi · nishi@belle.shiga-med.ac.jp

CITE THIS ARTICLE

Nishi K, Sakaguchi I, Nakagawa T, Naitoh S, Takaka N, Hirano A, Takase I, Yamamoto Y. The Venous Sinus Appears To Be a Source of Pulmonary Thrombosis. *Anil Aggrawal's Internet Journal of Forensic Medicine and Toxicology* [serial online], 2010; Vol. 11, No. 2 (July – December 2010): [about 6 p]. Available from: https://www.anilaggrawal.com/ij/vol_011_no_002/papers/paper002.html

ABSTRACT

Pulmonary thrombosis is a common complication caused by venous thrombosis in the deep veins in the legs. In contrast, the occurrence of cerebral venous and pulmonary thrombi without evidence of systemic venous thrombosis is unusual. We performed an autopsy on a 32 year-old man found dead in his living room. The autopsy revealed massive pulmonary thrombi and organized thrombus in the right transverse sinus. We confirmed the absence of any thrombus in the veins of the lower limbs, iliac vein and the inferior vena cava. Histological examination showed that the thrombi in the main pulmonary arteries had recently developed and that the thrombus in the sinus and those in the peripheral pulmonary arteries were organized with recanalisation and blood clotting. We concluded that the pulmonary embolism observed in this case was brought on by a cerebral sinus thrombus, and the cause of death was determined as pulmonary thrombosis.

Keywords: Pulmonary Thrombosis, Cerebral Venous Thrombosis

Introduction



Figure 2. Relatively newly developed thrombi with small amounts of fibrin observed on both pulmonary arteries.

Cerebral venous thrombosis (CVT) was first recognized in the 19th century[1] as an infrequent disease with an often dramatic clinical presentation.[2] The epidemiology of the disease has evolved considerable during recent decades with the current predilection involving primarily young and middle-aged people.[3] Although the clinical presentation, predisposing factors, neuroimaging findings, and outcomes of CVT are extremely diverse and more than 80 percent of patients have a good neurological recovery,[2] the complication of CVT may include coma and/or pulmonary embolism leading to potential sudden death. Diaz et al.[4] reported a fatal case of pulmonary emboli from a complication of superior sagittal sinus thrombosis and described that the pulmonary emboli as a complication due to CVT, Thus, this condition appears to have once been well recognized in the literature but has now been largely forgotten. Therefore, we have chosen to report on the autopsy case of a 32 year-old man of which pulmonary emboli was suspected as the fatal complication brought on by a transverse sinus thrombosis.

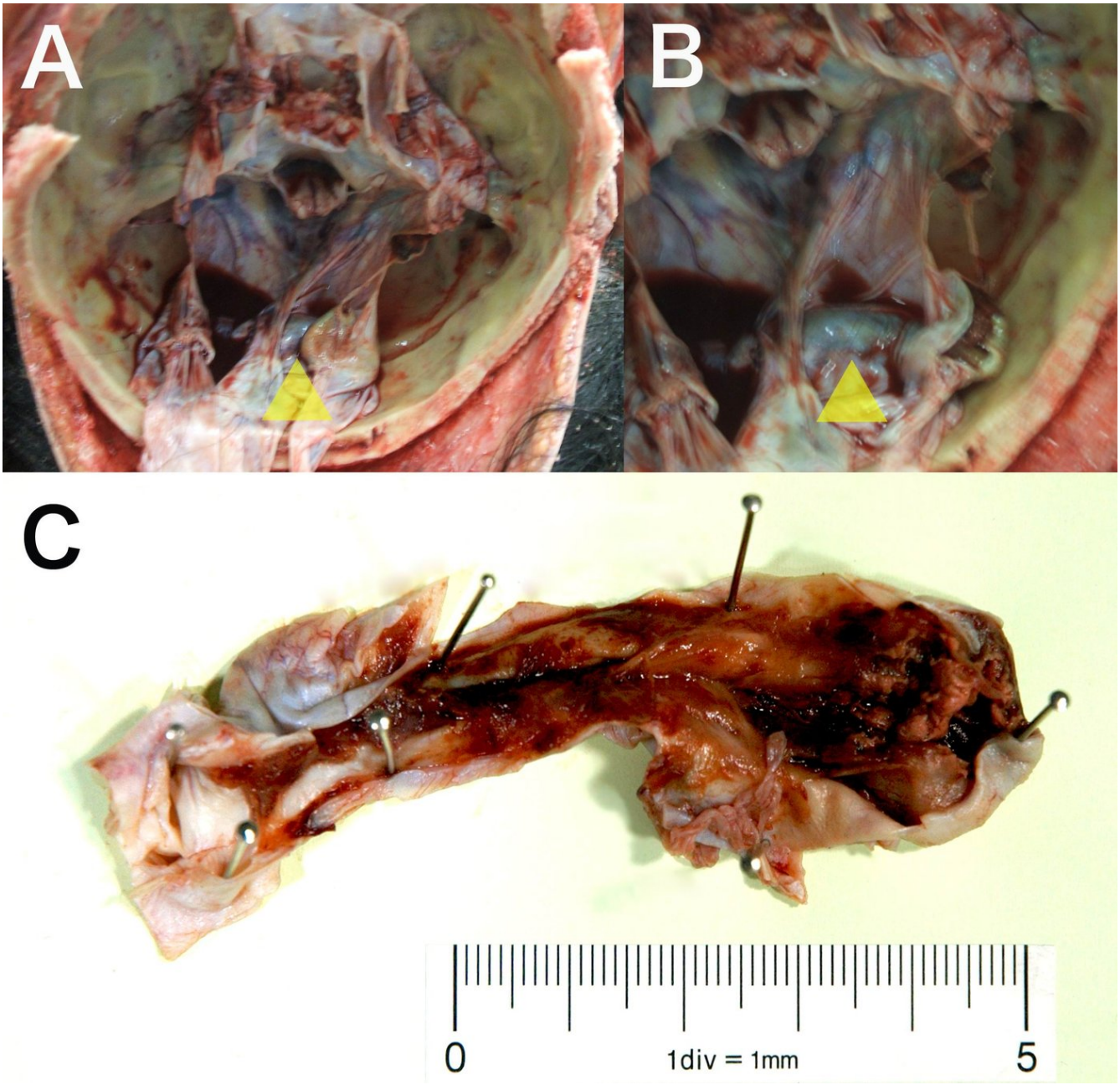

Figure 3. A brownish-green colored thrombus (arrow heads in A and B) detected in the right-transverse sinus. I am deeply sorry that these pictures are out of focus. After fixing with formalin, the organized thrombus was observed in the transverse sinus (C).

Case Report

History

One morning, a 32-year-old male was found dead in his living room by his female roommate. He had tattoos all over his body (Fig.1-A) because at that time he was working at a tattoo parlor and presumably had been practicing on his own body (Fig1-B). His roommate stated that he had no prior history of medical illness, although he often complained of headaches since the previous year and of lightheadedness several days before his death. The autopsy was performed the day following his death.



Figure 1. Tattoos all over the body of the deceased (A). At the time of his death, the deceased was working at a tattoo parlor and presumably had been practicing on his own body, especially in legs (B and C).

Autopsy findings

The right atrium was enlarged. Removal of the lungs revealed a saddle embolus extending into the lobar branches of both main pulmonary arteries (Fig.2). The thrombus had just recently developed. The liver and kidneys were congested. A relatively hard brown colored thrombus was detected in the right transverse sinus (Fig.3-A and Fig.3-B). No lesions in the brain were observed. We confirmed the absence of any thrombus in the iliac veins and in the inferior vena cava, and in the outer and deep veins of both lower limbs. Unfortunately, we were unable to examine the upper limbs.

Figure 5. This 3D computer graphics is based on histological observation from 40 serial sections. It reveales that the shape of fragment detected in the middle size pulmonary artery of right lung was just like an elephant trunk. This figure is an animation. Watch the animation (QuickTime movie, 17 MB).

Histological findings

The emboli in the medium-sized pulmonary arteries of the both side lungs mainly consisted of red blood cells and circular fragmented tissues similar to the endothelial tissue, which was recognized around the fresh emboli (Fig. 4-A and Fig. 4-B). The fragmented tissues were faintly adhered to the endothelium in the several sections of a serial 40 sections. The 3D computer graphics based on histological observation from 40 serial sections revealed that the shape of fragment detected in the middle size pulmonary artery of right lung was just like an elephant trunk (Fig.5).

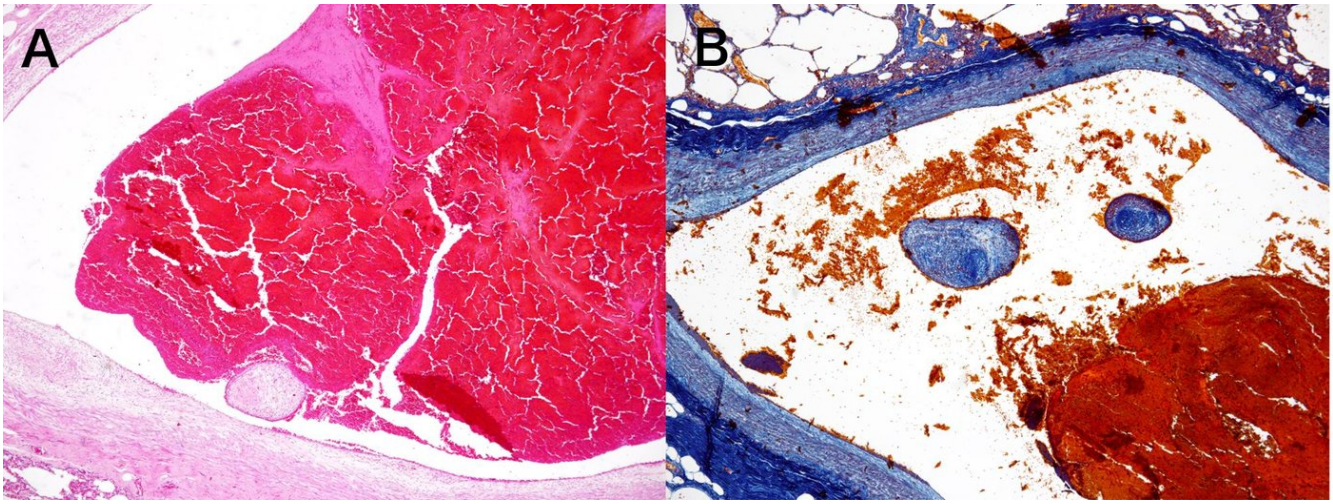

Figure 4. New thrombi detected on the middle size pulmonary arteries of both lungs. The thrombi consisted of an erythrocyte clot and tissue segments, which contained elastic fiber similar to those in endothelial wall of pulmonary artery and hemosiderin pigments similar to those in thrombus in the transverse sinus. The tissue segment slightly adhered to arterial walls only on several sections of the adjacent 40 tissue sections. (A: HE stain, and B: Azan-Mallory stain).

The thrombus in the right transverse sinus was already organized, and many capillaries in the enlarged vascular epithelial tissue were newly developed. In addition, relatively fresh clots with fibrin and erythrocytes were observed together within the vessel (Fig.6-A, Fig.6-B, Fig.6-C andFig.6-D).

Discussion

Although CVT, deep vein thrombosis, and pulmonary embolism have been associated with thrombophilic defects, CVT is the only condition with the quality of a rare disease. The annual incidence of CVT is 3 to 4 cases per million people. In contrast, deep vein thrombosis and pulmonary embolism affect 1 to 2 people out of 1000 in the general population, annually.[5]

What is already known on this topic

It is already known that cerebral venous thrombosis is an uncommon cerebrovascular disease presenting with a remarkably wide spectrum of signs and mode of onset. Recent development of diagnostic techniques with imaging machines such as MRI, MRA and CTA increases the ability to detect the cerebral venous thrombosis.

What This study adds

Although there were a few reports concerning fatal cases due to pulmonary thrombosis coming from cerebral sinus thrombosis, in the present case we added the histochemical analysis and 3-D view of the thrombosis in the pulmonary artery.

Suggestions for further development

When the pulmonary thrombosis is observed in autopsies, we should observe deep veins, and cerebral veins and sinuses.

It is still unclear why venous thrombosis mostly occurs in the deep veins of the legs and rarely in cerebral veins or sinus, and why CVT usually occurs at a relatively young age in individuals and

more often in women than in men.[6] A precise pathogenesis cannot be ascertained in at least 20% to 35% of cases.[7] The geographic frequency of CVT was reported as follows: Superior sagittal sinus: 62%, Left lateral (transverse) sinus:44,7%, Right lateral sinus:41.2%, Straight sinus:18%, Deep venous system :10%, Cortical veins: 17.1%, Jugular veins:11.9%, Cerebellum veins: 0.3%, Cavernous sinus :13%, respectively, and thrombi were detected in more than one sinus.[6]

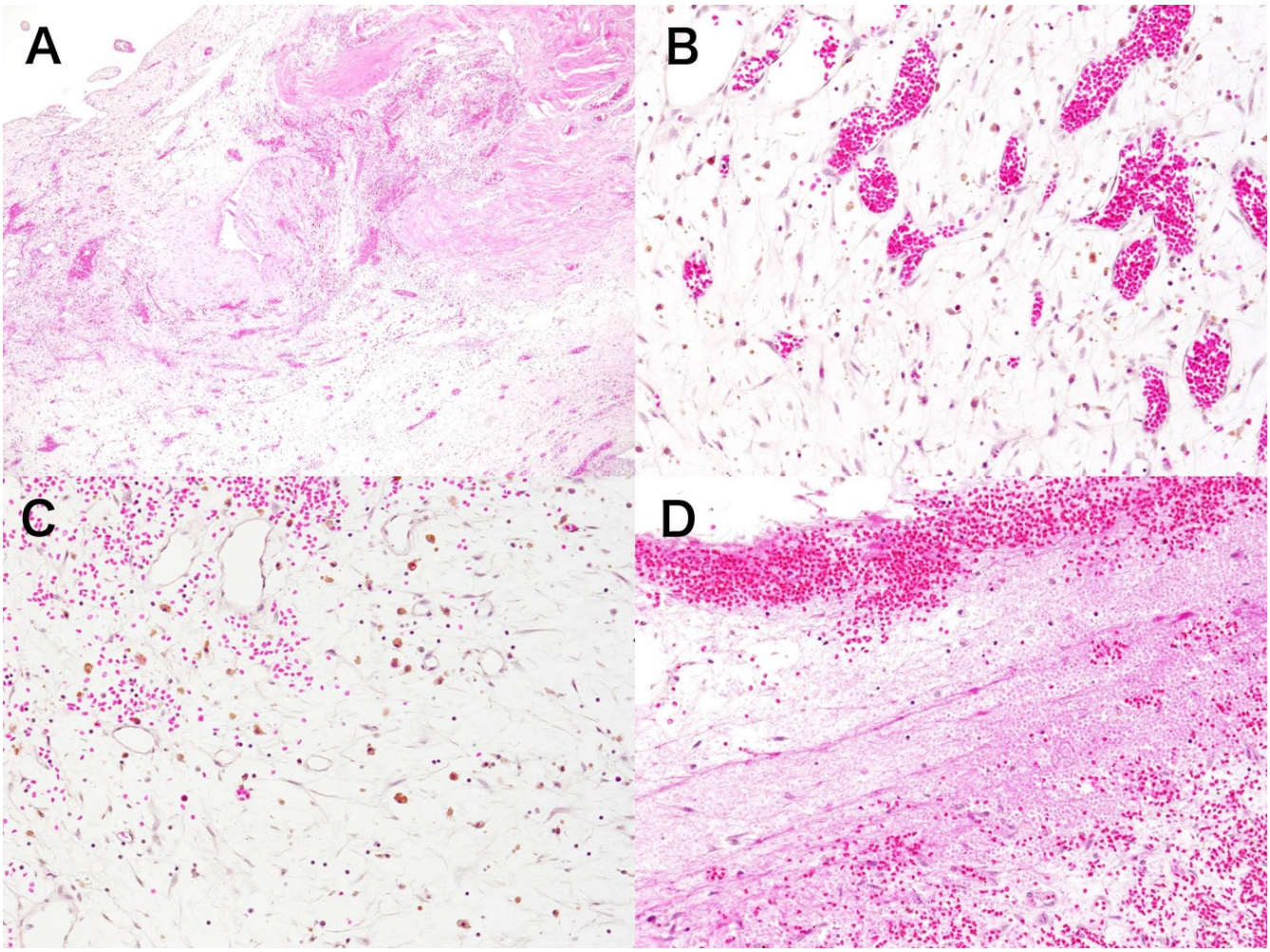

Figure 6. Histological staining revealed that thrombus in the transverse sinus was consisting of organized tissue (A) containing many capillaries (B), a lot of hemosiderin pigments(C) and fibrinous tissue with bleeding (D). Many capillaries showed producing the recanalisation in the organized tissue.

Concerning the prognosis of CVT, a meta-analysis of ISCVT cohort[6] described the prognosis of CVT as more likely than previous reported as the main cause of acute death from transtentorial herniation, secondary to a large hemorrhagic lesion, multiple lesions, or diffuse oedema. Other causes of acute death include status epilepticus, medical complication, and pulmonary embolism.[4] Diaz et al.[4] reviewed 203 cases of intracranial venous thrombosis between 1942 and 1990 and reported that the mortality rate was 49.3%, and that venous sinus thrombosis was associated with pulmonary emboli in 23 cases and that the mortality rate was 95.6% in those cases.[8]

In the present case, the thrombus with organized and re-canalized blood vessels in the transverse sinus was remarkably older than those in the pulmonary artery, and the tissue fragment detected in CVT were also observed in the pulmonary artery. Therefore, we believe that the tissue fragments came from the organized emboli in the sinus. Although several cases and retrospective studies have

observed the recanalisation phenomena in CVT and the spontaneous occurrence of recanalisation during the first few hours after thrombosis onset in many patients with CVT,[9] our subject with recanalisation of CVT showed no significant symptoms except for headache and vertigo until the onset of severe pulmonary embolism.

As thrombi most commonly from in the large, deep veins of the pelvis and lower extremities due to vein circulation, forensic pathologist have to be aware of the other sources of thrombi, specifically in the upper-extremities[10] or cerebral sinus when they encounter pulmonary thrombosis.

References

1. Gowers WR. Manual of diseases of the nervous system. 2nd ed. London: Churchill, 1888: p.416. (Back to [citation] in text)
2. Stam J. Thrombosis of the cerebral veins and sinuses. *N Engl J Med*. 2005 Apr 28;**352(17)**:1791-8. [] (Back to [citation 1] [citation 2] in text)
3. Einhäupl KM, Villringer A, Meister W, Mehraein S, Garner C, Pellkofer M, Haberl RL, Pfister HW, Schmiedek P. Heparin treatment in sinus venous thrombosis. *Lancet*. 1991 Sep 7;**338(8767)**:597-600. [] (Back to [citation] in text)
4. Diaz JM, Schiffman JS, Urban ES, Maccario M. Superior sagittal sinus thrombosis and pulmonary embolism: a syndrome rediscovered. *Acta Neurol Scand*. 1992 Oct;**86(4)**:390-6. [] (Back to [citation 1] [citation 2] [citation 3] in text)
5. Nordström M, Lindblad B, Bergqvist D, Kjellström T. A prospective study of the incidence of deep-vein thrombosis within a defined urban population. *J Intern Med*. 1992 Aug;**232(2)**:155-60. [] (Back to [citation] in text)
6. Ferro JM, Canhão P, Stam J, Bousser MG, Barinagarrementeria F; ISCVT Investigators. Prognosis of cerebral vein and dural sinus thrombosis: results of the International Study on Cerebral Vein and Dural Sinus Thrombosis (ISCVT). *Stroke*. 2004 Mar;**35(3)**:664-70. [] (Back to [citation 1] [citation 2] [citation 3] in text)
7. Preter M, Tzourio C, Ameri A, Bousser MG. Long-term prognosis in cerebral venous thrombosis. Follow-up of 77 patients. *Stroke*. 1996 Feb;**27(2)**:243-6. [] (Back to [citation] in text)
8. Cakmak S, Nighoghossian N, Desestret V, Hermier M, Cartalat-Carel S, Derex L, Honnorat J, Trouillas P. Pulmonary embolism: an unusual complication of cerebral venous thrombosis. *Neurology*. 2005 Oct 11;**65(7)**:1136-7. [] (Back to [citation] in text)
9. Baumgartner RW, Studer A, Arnold M, Georgiadis D. Recanalisation of cerebral venous thrombosis. *J Neurol Neurosurg Psychiatry*. 2003 Apr;**74(4)**:459-61. [] (Back to [citation] in text)
10. Prandoni P, Polistena P, Bernardi E, Cogo A, Casara D, Verlato F, Angelini F, Simioni P, Signorini GP, Benedetti L, Girolami A. Upper-extremity deep vein thrombosis. Risk factors, diagnosis, and complications. *Arch Intern Med*. 1997 Jan 13;**157(1)**:57-62. [] (Back to [citation] in text)