ANIL AGGRAWAL'S
Internet Journal of
Forensic Medicine and Toxicology
The world's first online journal devoted entirely to forensic medicine and toxicology · Published 1 January and 1 July

VOL. 11, NO. 1
Downloaded from www.anilaggrawal.com · ISSN 0972-8074 (Online) · https://www.anilaggrawal.com/ij/vol_011_no_001/reviews/tb/page008.html

Book Reviews: Technical Books Section

...AN INVALUABLE BOOK AND DVD SET FOR FORENSIC PATHOLOGISTS ...The photographs are very clear and informative. In all there are about 1500 pictures covering the whole panorama of forensic pathology. CRC came out with a very good atlas on poisoning sometime back - Color Atlas of Human Poisoning and Envenoming by James H. Diaz. I would imagine that both these atlases together would make a very good set for forensic pathologists, especially the younger ones at the start of their careers. They can benefit from the personal case photographs of their more experienced counterparts...

Color Atlas of Forensic Medicine and Pathology, Book and DVD Set, 1st Edition, edited by Charles A. Catanese. Hard Bound, 11" x 8.7" x 0.9" (Atlas), Standard Casing (DVD)
CRC Press LLC, 6000 Broken Sound Parkway NW, Suite 300, Boca Raton, FL 33487-2742. , . Publication Date December 10, 2009. 424 pages (Atlas), 1461 pictures (DVD), ISBN-10: 1439821186, ISBN-13: 978-1439821183 (alk. paper). Price: $299.95.

Visit the Official site of this book by clicking here

Buy from Amazon by clicking here.

Click above pictures to buy this set from Amazon. Click here to enlarge picture of book, and here to enl

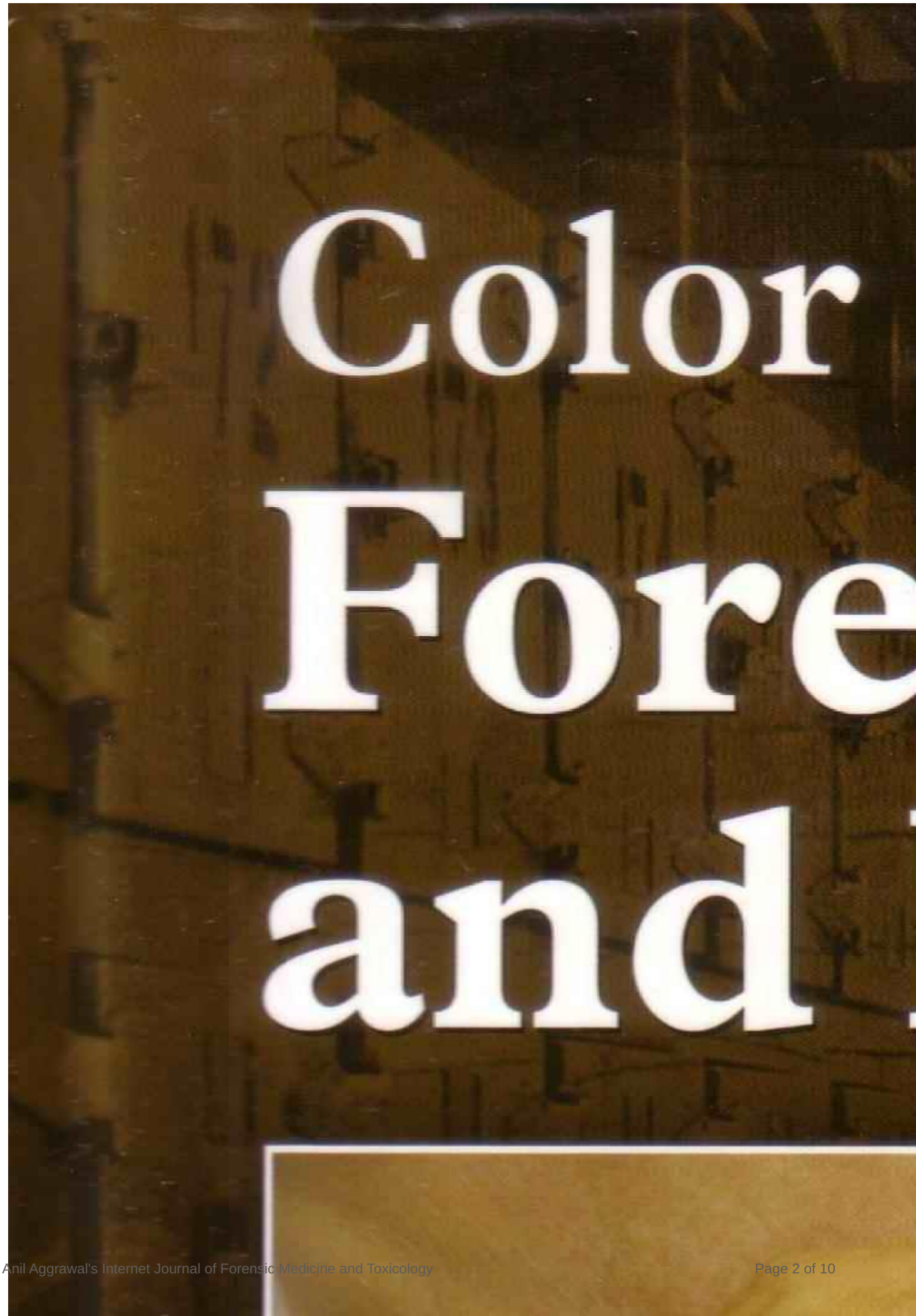
Color
Fore
and

Forensic pathology is essentially a visual subject. One can learn a lot more and lot more quicker by referring to a photograph of an injury than by reading paragraphs upon paragraphs of description of injuries. Atlases serve this purpose very well.

Sadly there are not many atlases that are available in English language, although there are some very good atlases available in German and Japanese languages. One good atlas has been published by the CRC press (by Jay Dix). Now CRC Press has come out with another very good atlas – by Charles A. Catanese. There is an accompanying DVD also, which gives the entire atlas as a PDF file. Both the atlas and the DVD can be bought as standalone items, or better still as a set, which is far more economical.

View this book on Amazon

Catanese divides his atlas in ten sections, each dealing with a major topic within forensic pathology. The topics are sudden natural death in a forensic setting (chapter 1), therapeutic Interventions, Complications, and Accidents (chapter 2), Substance Abuse and Poisoning (chapter 3), Postmortem Change and Time of Death (chapter 4), Pediatric Forensic Pathology (chapter 5), Blunt-Force Injuries (chapter 6), Sharp-Force Injuries (chapter 7), Gunshot Wounds (chapter 8), Burns (chapter 9) and finally Asphyxia (chapter 10).

The photographs are very clear and informative. In all there are about 1500 pictures covering the whole panorama of forensic pathology. CRC came out with a very good atlas on poisoning sometime back - Color Atlas of Human Poisoning and Envenoming by James H. Diaz. I would imagine that both these atlases together would make a very good set for forensic pathologists, especially the younger ones at the start of their careers. They can benefit from the personal case photographs of their more experienced counterparts.

The color atlas and DVD set can be heartily recommended to all forensic pathologists.

Excerpts from the atlas and DVD:

This atlas and DVD set is a significant addition to the literature on forensic pathology. So that our readers can get some idea about what this set contains, the editors at the journal office decided to run some pictures from this set. Here goes....

Chapter 1 - Sudden natural death in a forensic setting

This chapter offers a brief overview of some common and some not so common natural deaths that typically may occur in a medical examiner system. Also demonstrated are examples that may alter appearance of tissue such as formaldehyde fixation and variation due to different types of photographic imagery. There are also examples of normal organs in both a fresh and formaldehyde fixed state that can be used by the reader to compare with diseased organs.

Deaths under this category are often unexpected and sometimes unwitnessed. There is often a suspicion of foul play. Families may say, “But Doctor, he was in fine health. I saw him an hour ago. It cannot be natural. Somebody must have harmed him,” etc. Because of the sudden, often unexpected nature of these deaths, it is best to do an autopsy to clarify exactly what happened. This decision to autopsy depends on many factors, including the decedent’s age, medical history, family wishes, decedent’s wishes (wills, etc.), religious beliefs, circumstance at time of death, resources of a particular system, etc. As one becomes less certain of the cause of death, the level of suspicion will

increase. At some point, the decision to autopsy becomes obvious and absolutely necessary. This decision is based on experience, knowledge, and sound judgment. Not infrequently, seemingly natural deaths can have unnatural or traumatic previous circumstances; therefore, when uncertain, an autopsy is best performed. In many medical examiner systems, the majority of deaths end up being certified as natural.



Morbid obesity. This is a legitimate cause of death and can stand alone on a death certificate (This figure appe

Chapter 2 - Therapeutic Interventions, Complications, and Accidents

The evaluation of deaths related to complications of diagnostic and therapeutic procedures has traditionally been a problematic area for forensic pathologists and death investigators. The reasons for this are multiple: (1) these deaths often blur the boundaries dividing medicolegal and hospital death investigation; (2) many forensic pathologists do not feel comfortable approaching the often

complex and highly technical issues present today in modern medicine; and (3) at least some forensic pathologists believe that these types of death belong more appropriately within the domain of the hospital autopsy. Despite this ongoing controversy, most forensic pathologists and death investigators will, at some point during their careers, be forced to handle these types of deaths.



These figures show one of many possible artifacts associated with organ donation that may be mistaken periorbital hemorrhages were not present at the time of admission. (These figures appears on page 59 of the

Chapter 7 - Sharp-Force Injuries

Sharp-force injuries are defined as injuries produced by an instrument with a thin edge or point. Examples of these instruments include a knife, razor, box cutter, scalpel, sharp-edged piece of metal, broken glass bottle, broken glass window, scissor, ice pick, fork, propeller, screw driver, saw blade, axe, machete, arrow, nail, pickaxe, spiked fence post, meat cleaver, etc.

A stab wound is typically made by a knife blade and is defined as having a greater depth of penetration than surface dimension. An incised wound is a slicing-type injury where the surface dimension is greater than the depth of penetration.

Accurate, concise, and organized wound documentation is important, as with all other injuries. Each injury should have a documented location on the body, including a description of adjacent abrasions or contusions, wound dimensions, depth of penetration, and direction of penetration into the body. All injured structures should be documented, including the amount of hemorrhage both in the wound track and within body cavities. In cases where there are multiple injuries, it is acceptable to group them with ranges. It is good practice to take overall photographs of the body before and after cleaning; as well as close-up photographs of each wound.

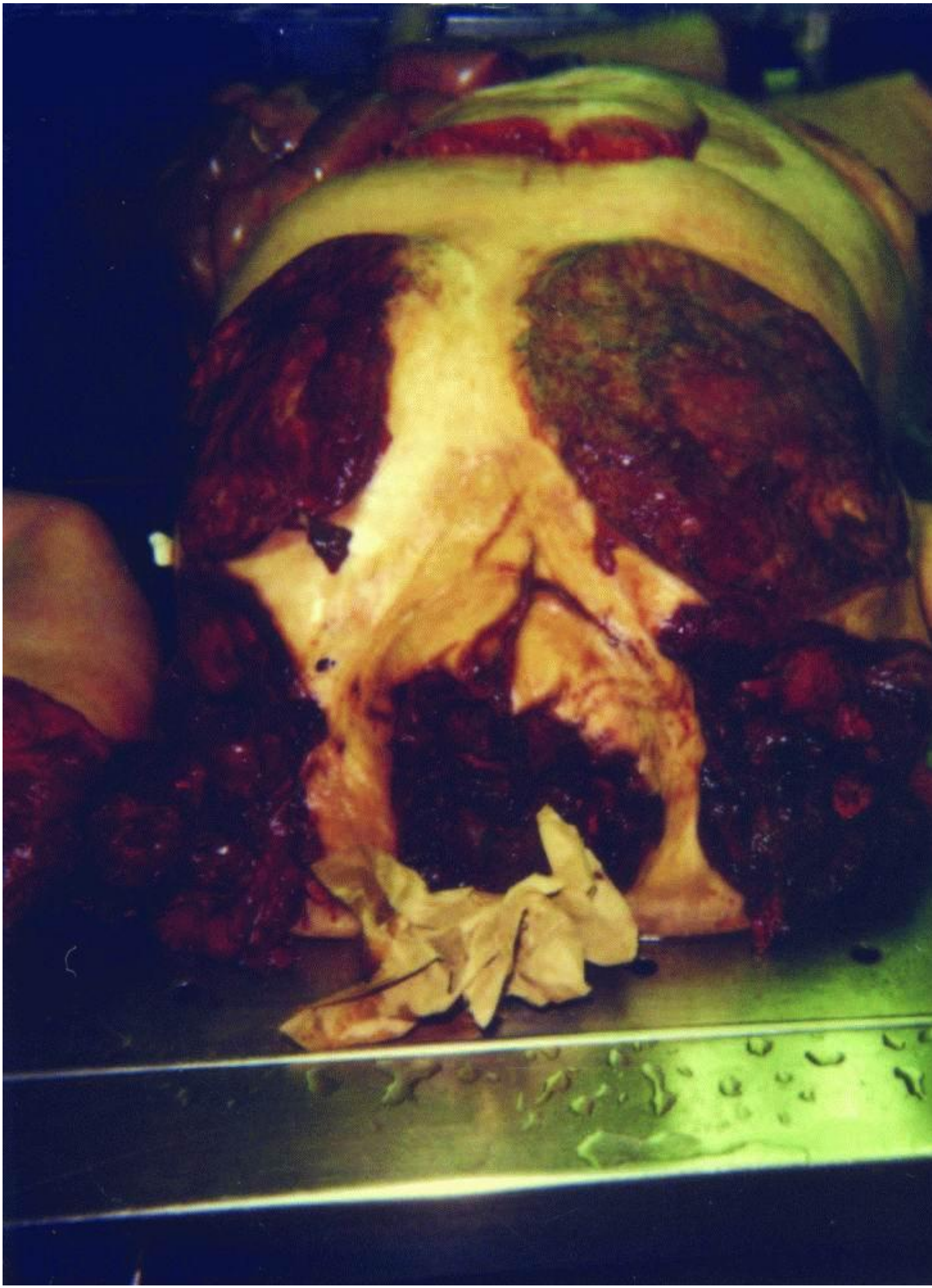

These are examples of dismembered bodies with saw cut marks through bone. It is important to save these breasts cut from the body. Also note image (right) of this young individual, who was cut into multiple pieces a

Chapter 10 - Asphyxia

This is a general term used to describe decreased oxygen uptake or use, together with decreased carbon dioxide elimination.

Airway obstruction may occur by smothering, neck compression, foreign body aspiration, excess secretions or swelling of the airway, etc. Smothering is defined as external occlusion of the mouth and/or nose which prevents air exchange. Children may aspirate foreign bodies such as peanuts, hotdogs, popcorn, watch batteries, coins, etc. Adults who aspirate food are invariably neurologically compromised or intoxicated. Airway obstruction due to excess mucus or swelling as with asthma or anaphylaxis can produce asphyxia. Also various body positions may produce airway obstruction (positional asphyxia) as with occupants of motor vehicles trapped after collisions or intoxicated people passing out and sliding into awkward positions that prevent chest expansion and air exchange.

Autopsy findings associated with smothering may be very subtle or non-existent. Findings may include abrasions around the nose and/or mouth that cannot be explained by other means (i.e., resuscitative efforts). Great force is applied to the mouth and lips which may cause tears to the frenulum of the lip, the mucous membrane that connects the inside of the lip to the corresponding gum. Smothering may occur with the use of hands or by placing an object over a face, such as a pillow. Depending on the degree of force applied and the structures compressed, there may or may not be petechiae present on the skin of the face, mucous membranes or eyes. Arguably, the greater the disparity in size between the perpetrator and the victim (i.e., adult and child), the less likely there will be a demonstrable injury due to the overpowering relative nature of this type of struggle. It is important that in cases of suspected smothering, experienced police interrogators and medical investigators perform the interviews. In cases where autopsy findings are very subtle, well-documented descriptions of the circumstances with specific details are extremely important.



Some cases may require further evaluation including a posterior neck and back dissection. This case involve
surface of bone is exposed. It is important to dissect the arms as well, which may demonstrate contusions f
visualize contusions in darker-skinned individuals. (These figures appears on page 386 of the atlas).

The Atlas and DVD are full of such illustrative pictures related to virtually every aspect of forensic pathology. We are sure our readers would be immensely benefitted by this set.

View this book on Amazon View this book on Amazon

Request a PDF file of this review by clicking here. (If your screen resolution can not be increased, or if printing this page is giving you problems like overlapping of graphics and/or tables etc, you can take a proper printout from a pdf file. You will need an Acrobat Reader though.)