ANIL AGGRAWAL'S
Internet Journal of
Forensic Medicine and Toxicology
The world's first online journal devoted entirely to forensic medicine and toxicology · Published 1 January and 1 July

VOL. 11, NO. 1
Downloaded from www.anilaggrawal.com · ISSN 0972-8074 (Online) · https://www.anilaggrawal.com/ij/vol_011_no_001/reviews/tb/page005.html

Book Reviews: Technical Books Section

...AN INVALUABLE BOOK ON PEDIATRIC HOMICIDE ...I am going to keep this book at my desk forever, as I know it is going to be of big help to me. I can heartily recommend this book to medical examiners, the police personnel of all levels, child abuse investigators, and attorneys charged with either making or ruling out the diagnosis of homicide. I would imagine that it is going to be an invaluable resource for them...

Pediatric Homicide: Medical Investigation, 1st Edition, edited by Karen Griest. Hard Bound, 9.3" x 6.4" x 0.9".
CRC Press LLC, 6000 Broken Sound Parkway NW, Suite 300, Boca Raton, FL 33487-2742. , . Publication Date September 16, 2009. 232 pages, ISBN-10: 1420073001, ISBN-13: 978-1420073003 (alk. paper). Price: $99.95.

Visit the Official site of this book by clicking here

Buy from Amazon by clicking here.

Read an interview with the author Dr. Griest by clicking here.

Click above picture to buy from Amazon. Click here to enlarge picture

PED
HO
Medica



Although there are a number of books on homicide investigation, there are very few which cater solely to pediatric homicide. As any forensic pathologist would tell you, of all cases dealt by him, about one-fifth to one-sixth belong to the pediatric category. This reviewer deals with pediatric homicide cases almost on a daily basis. A number of newborns are brought to us by the police, which they have recovered from dustbins! Needless to say, we have to take great care in such cases. The police invariably wants to know, if the child was born alive or dead, or if born alive, whether he died a natural death or was killed, or simply exposed to the elements to allow it to die. Much of my time is spent teaching my postgraduates how to deal with these cases.

View this book on Amazon

Thankfully now we have a good book, which I can heartily recommend to all my junior colleagues and students. Pediatric homicide investigation is different from normal cases, because, the cause of death in infants and children is often subtle and difficult to establish.

...Thankfully now we have a good book, which I can heartily recommend to all my junior colleagues and students. Pediatric homicide investigation is different from normal cases, because, the cause of death in infants and children is often subtle and difficult to establish...

Dr. Karen Griest, the editor and a major contributor to this book is a well known expert in this area. She has taught forensic medical investigation to police officers, criminal investigators, medical personnel, attorneys, and forensic professionals. She has also consulted on hundreds of child injury and death cases and has testified in state and federal courts throughout the United States.

As I leafed through the book, I found it had chapters on such important subjects as intentional head injury, neonaticide, intentional suffocation, child abuse by drowning and so on. Each chapter is written by an expert known in the field. The book is thoroughly illustrated by pictures, which adds to the value of this book.

Click here to read an exclusive interview with Dr. Karen Griest.

I am going to keep this book at my desk forever, as I know it is going to be of big help to me. I can heartily recommend this book to medical examiners, the police personnel of all levels, child abuse investigators, and attorneys charged with either making or ruling out the diagnosis of homicide. I would imagine that it is going to be an invaluable resource for them.

Excerpts from the book:

This book is a significant addition to the literature on pediatric pathology. So that our readers can get some idea about what the book contains, the editors at the journal office decided to run some excerpts from this book. This is how the author describes some less common presentations in Inflicted Abdominal Injury (chapter 4)....

4.2.9 Less Common Presentations in Inflicted Abdominal Injury

Shah et al. (1997) reported in a 15-month-old for the first time a small-bowel stricture secondary to abdominal trauma in child abuse, although it has been reported in lap-belt injury.

The stomach is a relatively mobile organ and can avoid serious injury in most cases by moving about in response to nonpenetrating forces. In a large series of blunt abdominal trauma cases,

gastric rupture is generally felt to comprise from 1.3% to 7.1% of visceral injuries, with most authors report¬ing about 2.1%. Schechner and Ehrlich (1974) reported two cases of gas¬tric rupture following episodes of proved or strongly suspected child abuse. One was a 4-year-old boy admitted with a stomach ache. According to his stepfather, he had been spanked on the buttocks while lying across the step¬father's knee at about 9 p.m. on the day of admission, shortly after the inges¬tion of a large picnic meal of hot dogs and beans. Ten minutes later the child began to complain of abdominal pain, nausea, and respiratory distress. At laparotomy, a 10- to 12-cm laceration was found through the anterior gastric wall near the greater curvature. Case 2 concerned a 5-year-old boy who was reported to have been kicked in the abdomen by his father earlier that eve¬ning, apparently following the ingestion of a large amount of water. A lapa¬rotomy showed a 13-cm linear tear along the lesser curvature of the stomach through the anterior wall. In each of the reported cases, the child presumably had a full stomach, and the compressing force applied squeezed the gastric contents into a small area of the stomach, thus resulting in a bursting of the gastric wall outward.

Acute gastric dilatation may occur as a complication of child abuse and neglect. Acute gastric dilatation is a paralytic phenomenon which is due to loss of muscle tone rather than mechanical gastric outlet obstruction. The pathogenesis of this acute gastric dilatation in the deprived child is related to structural and functional changes in the stomach due to chronic starvation with subsequent ingestion of a large meal in the hospital.

Boysen (1975) reported the case of chylous ascites in a battered 20-month ¬old child. The child had a history of enlarging abdomen for 2 weeks. A diag¬nostic paracentesis yielded chylous fluid. A definite leak in the abdominal lymphatic system was visualized by lymphangiogram. In one large series of chylous ascites, 12% of the cases were due to trauma. By far, the most com¬mon cause of chylous ascites in children is a congenital abnormality. Other causes include obstruction to the mesenteric lymphatic vessels by enlarged retroperitoneal lymph nodes due to neoplasm or tuberculosis or mesenteric adenitis. In about one-third of cases no cause can be found.

Both direct and indirect forces have been implicated in the cause of abdominal pseudoaortic aneurysms, although child abuse is a rare cause. Direct force, the major component of injury, occurs when the aorta is compressed against a relatively fixed vertebral column. An example is an improper seat belt position. Indirect force occurs with acute deceleration; the abdominal vasculature, especially the mesenteric vessels, are sheared from the aorta. There are often accompanying injuries to the abdominal viscera and vertebrae. A striking feature of pediatric pseudoaneurysms is delayed presentation at greater than 24 hours.

Only four cases of bladder rupture have been reported in child abuse. The bladder remains an abdominal organ for the first 6 years of life; as a result, it is more vulnerable to external trauma. After age 6, the bladder assumes a more protected position beneath the symphysis pubis. The superior sur¬face, or dome, of the bladder is the least supported and the weakest part of the bladder. It extends upward and is the only surface completely covered by peritoneum. Intraperitoneal bladder ruptures account for approximately one-third of all bladder injuries. The rupture classically appears as a large horizontal tear in the dome of the bladder. The tear is believed to occur when a blow is delivered to the lower abdomen in the presence of a full bladder. Peritoneal resorption of urine produces electrolyte imbalance, acidosis, and uremia (i.e., pseudorenal failure). The recognition of a possible relationship between an elevated BUN and intraperitoneal rupture of the bladder may be the only indication of this diagnosis in clinically

unsuspected cases. Along with laboratory findings suggestive of acute renal failure, the patient with bladder rupture may also present with symptoms such as suprapubic pain, genital pain, bilateral shoulder tip pain, anuria, abdominal distention, peri¬tonitis, nausea, decreased bowel sounds, and gross hematuria.

Peritoneal signs cannot be relied upon for early diagnosis of bladder rupture because extravasated urine is sterile, invoking little peritoneal reaction. The diag¬nostic test of choice is a retrograde cystogram radiograph. Abdominal CT scan is used for evaluation of bony injury and can substitute for diagnostic peritoneal lavage and intravenous pyelogram. Delayed diagnosis may lead to abscess and urinary fistula formation. True renal failure in the abused child may also occur. This can result from direct trauma to renal parenchyma and extensive muscular injury with rhabdomyolysis. Bladder rupture should be suspected in the setting of blunt trauma with hematuria, and in a child with abdominal distension, oliguria, hyperkalemia, and apparent renal failure.

Hopkins et al. (1994) presented an unusual case of a 2.5-year-old boy who had a 100-kg tombstone fall on him. The left renal vein was transected. The left renal vein is especially susceptible to blunt trauma because of its longer length and its course across the midline. Probable lateral displacement of the kidney in this incident led to the venous injury. Ligation of the left renal vein is possible because of collateral drainage by the adrenal and gonadal veins. Blood loss is severe with a renal vein injury because there is not the intense vasospasm that occurs with arterial injuries.

Complete avulsion of the common bile duct from the duodenum has been reported in inflicted abdominal trauma. Avulsion of the common bile duct has not been reported before, but is in keeping with injuries in battered children to relatively fixed viscera in the epigastrium, the duodenum, the pancreas, the root of the mesentery, and the liver.

Perforation of the pelvic colon has also been reported in abdominal injury from child abuse.

DiGiacomo et al. (2000) reported a case of periportal fluid tracking in a case of child abuse with abdominal injury. Laboratory studies showed marked elevations of liver enzymes. In another study of pediatric blunt abdominal injury, 40% of children with periportal fluid tracking had no other abnormal findings by CT.

Periportal venous gas and pneumatosis intestinalis are rare findings in child abuse. They have been associated with hematoma of the small bowel mesentery, duodenal hematoma, hemoperitoneum, tear of the peritoneum, mesenteric abscesses, and liver laceration. Portal venous gas may be seen in a variety of conditions, including mucosal damage from such causes as inflammation, ischemia, or causes of increased intraluminal gas pres¬sure such as trauma or obstruction. Peripheral location of portal venous gas within the liver has been attributed to centrifugal portal venous flow. Biliary air, on the other hand, is more central within the liver, presum¬ably because of the centripetal flow of bile. Both CT and ultrasonography are more sensitive than conventional radiography for detection of portal venous flow.

Figure 4.13 Bruising of lower abdomen in a case of sexual abuse. Note bruising of penis. There are ther groins. (Please Click to enlarge)

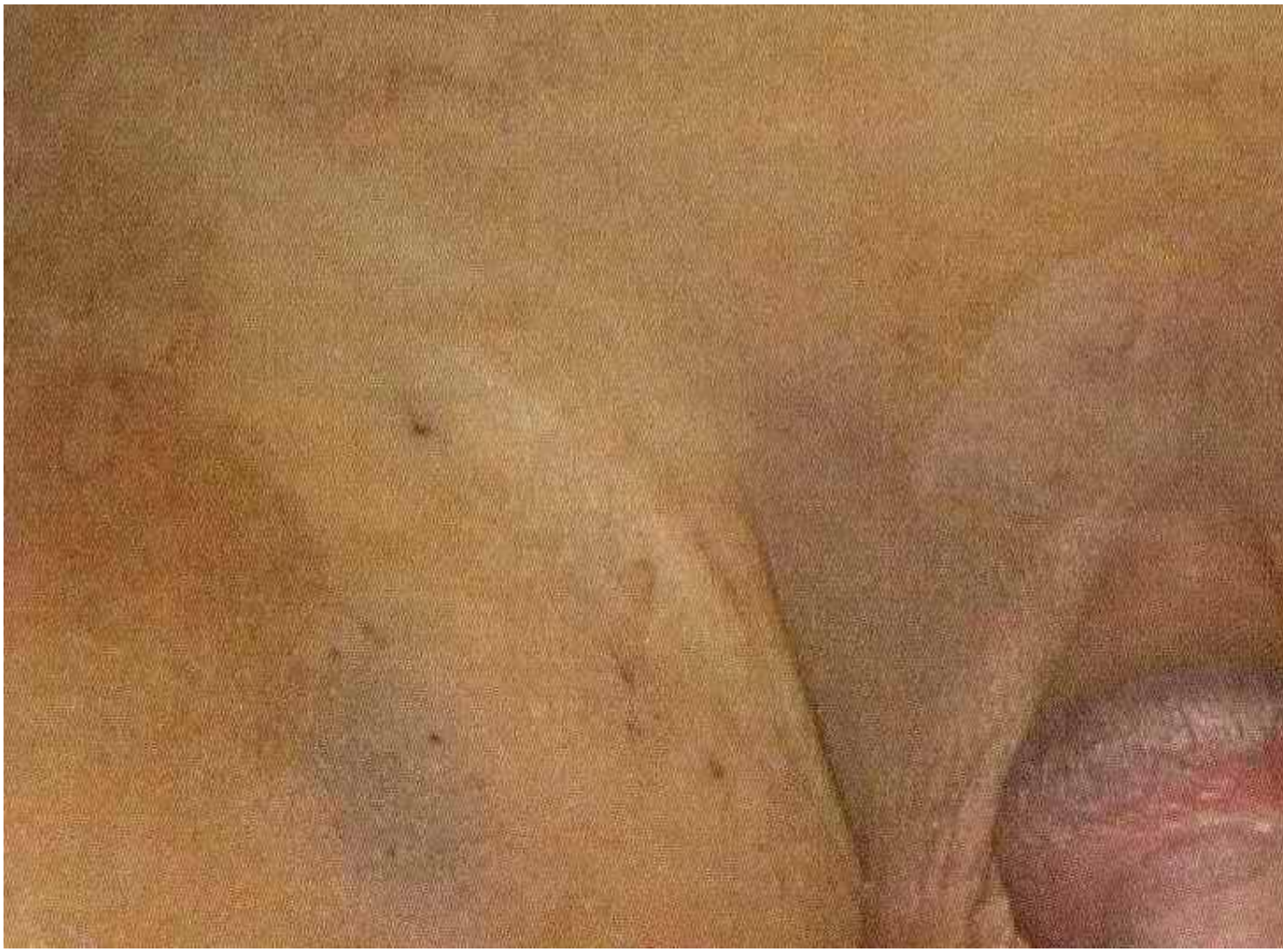

Van Winckel et al. (1997) reported the case of a 21-month-old boy who had unremitting bilious vomiting and elevated serum amylase and lipase lev¬els. Sonographic examination of the abdomen revealed a cystic mass in the epigastric region; fluid collection in the lesser sac; fluid collection bordered by the pancreas, liver, and stomach; distended intestinal loops surrounded by ascites. Fluid collection- in the lesser sac and ascites surrounding distended intestinal loops indicated remote subacute hemorrhage. Fluid in the lesser sac can be differentiated from a pancreatic pseudocyst by the absence of pan¬creatic tissue surrounding the fluid collection, by cranial and lateral exten¬sion of the fluid collection, and by the presence of ascites.

4.2.10 Child Sexual Abuse and Abdominal Injury

It is important to consider and examine the possibility of sexual abuse. A case of rectal injury from sexual abuse was excluded from the Barnes et al. study. Cases have been identified where abdominal injury and sexual abuse have coexisted. The presence of bruising of the lower abdominal wall in a child is suggestive of sexual abuse (Figure 4.13).

The picture like the one above are throughout. A great resource for forensic pathologists indeed....

View this book on Amazon

Request a PDF file of this review by clicking here. (If your screen resolution can not be increased, or if printing this page is giving you problems like overlapping of graphics and/or tables etc, you can take a proper printout from a pdf file. You will need an Acrobat Reader though.)