ANIL AGGRAWAL'S
Internet Journal of
Forensic Medicine and Toxicology
The world's first online journal devoted entirely to forensic medicine and toxicology · Published 1 January and 1 July

VOL. 10, NO. 2
Downloaded from www.anilaggrawal.com · ISSN 0972-8074 (Online) · https://www.anilaggrawal.com/ij/vol_010_no_002/reviews/tb/page009.html

Book Reviews: Technical Books Section

...AN EXCELLENT BOOK ON FORENSIC ODONTOLOGY ...This is perhaps the first book which gives information on the forensic examination of dental structure in such great detail... and with so many illustrative photographs... A must for all medical examiners, investigators, dental specialists, forensic odontologists, lawyers, and expert witnesses...

Dental Autopsy, 1st Edition, by William E. Silver and Richard R. Souviron. Hard Bound, 10.1" x 7.2" x 0.6".
CRC Press LLC, 2000 Corporate Blvd., N.W., Boca Raton, Florida 33431, , . Publication Date June 23, 2009. 276 pages, ISBN-10: 1420070134; ISBN-13: 978-1420070132 (alk. paper). Price: $129.95

Visit the Official site of this book by clicking here

Buy from Amazon by clicking here.

Click above picture to buy from Amazon. Click here to enlarge picture

Dental Autop



The book under review is a comprehensive treatise on forensic odontology. It is organized for field and lab reference. One of the most valuable aspects of the book is that it has been illustrated with more than 300 color photos.

The main aim of the book is to educate the dental, medical and legal professions in the conduct of a forensic dental examination of the oral structures and its many ramifications in the criminal justice system as well as in civil litigation. The book must prove to be an essential resource for medical examiners, investigators, dental specialists, lawyers, and expert witnesses.

The value of the book is enhanced by the actual case law that it provides. For instance on page 151, it gives the first ever case in the United States, where a bitemark was used to link a suspect to the crime. The criminal - a person named Doyle - after committing a burglary, quite naively bit into some cheese that was available at the scene of crime. In this 1954 Texas case (State v. Doyle, Texas, 1954), Dr. William Kemp, a Texas dentist testified that the bites in the piece of cheese at the scene of crime was indeed made by the suspect Doyle! Interestingly in this case, the police obtained the sample bitemark evidence from Doyle *without* a court order. Doyle later argued (in appeal) that this was a violation of his Fifth Amendment rights (protection against self-incrimination). However the appellate court did not agree with his argument and allowed the prosecution.

View this book on Amazon

The book - which is one of the best in the field so far - has been written by Dr. William Silver and Dr. Richard Souviron. Silver is the deputy chief forensic odontologist for the Miami Dade Medical Examiner's Department. He has worked on numerous mass disasters and training programs, offering his expertise in dental identifications in the World Trade Center disaster, Hurricane Katrina, and the Miami Valujet crash. Dr. Richard Souviron is the chief forensic odontologist for the Miami Dade Medical Examiner's Department and is one of the founding forensic odontologists for the Odontology section of the American Academy of Forensic Sciences. He has been involved in several high profilebitemark cases and has appeared on Court TV, 60 Minutes, Forensic Files, Dateline, CNN, and BBC.

Click here to read an exclusive interview with Dr. Silver and Dr. Souviron.

Here is a list of book contents, so readers may know exactly what kind of information to expect in this book.

Chapter	Title	Page
1	Introduction to Forensic Odontology	1
2	Medical Autopsy	13
3	Forensic Odontology	29
4	Classification of Dental Remains	51
5	Role of Dental Professionals	59
6	Instrumentation	65
7	Crime Scene	75
8	Antemortem Records	81
9	Postmortem Records - The Dental Autopsy	89

10	Methods of Comparison and Identification	117
11	Mass Disaster	133
12	Facial Approximation	145
13	Odontoglyphics - Bitemarks	151
14	The Expert Witness	195
15	Psychological consequences	225
16	Professional Organizations	227
Final Note		231
Appendix		233
Bibliography		261
Index		265

Excerpts from the book:

Here are some excerpts from the book, so reader can get some ideas as to what is contained within the book. This is what the authors have to say in chapter 13 (**Odontoglyphics - Bitemarks**) - pages 158 onwards.

Bitemark Classification

Figure 13.8 Class I bite: multiple bites. (This figure appears on page 158 of this book. Please Click to enla



The types of human bitemarks can vary greatly; they can be offensive, defensive, self-inflicted, or consensual. The wound, regardless of type, can be classified as human or animal. Animal bites are discussed later in the text but human bites in skin can be classified based on severity.

Class I

The pattern is diffuse. No individual tooth marks are identified. There may be one or both arches marking (Figure 13.8). It may appear as a diffuse bruised ring and may be of little or no evidentiary value for matching to a suspect (Figure 13.9a,b). The Class I bite may not even be identifiable as a human bitemark, only a round pattern injury. However, it may be of great value in other regards such as saliva, DNA, arch forms, and so on.

Figure 13.9a Class I bite: bite mark on arm. (This figure appears on page 159 of this book. Please Click t

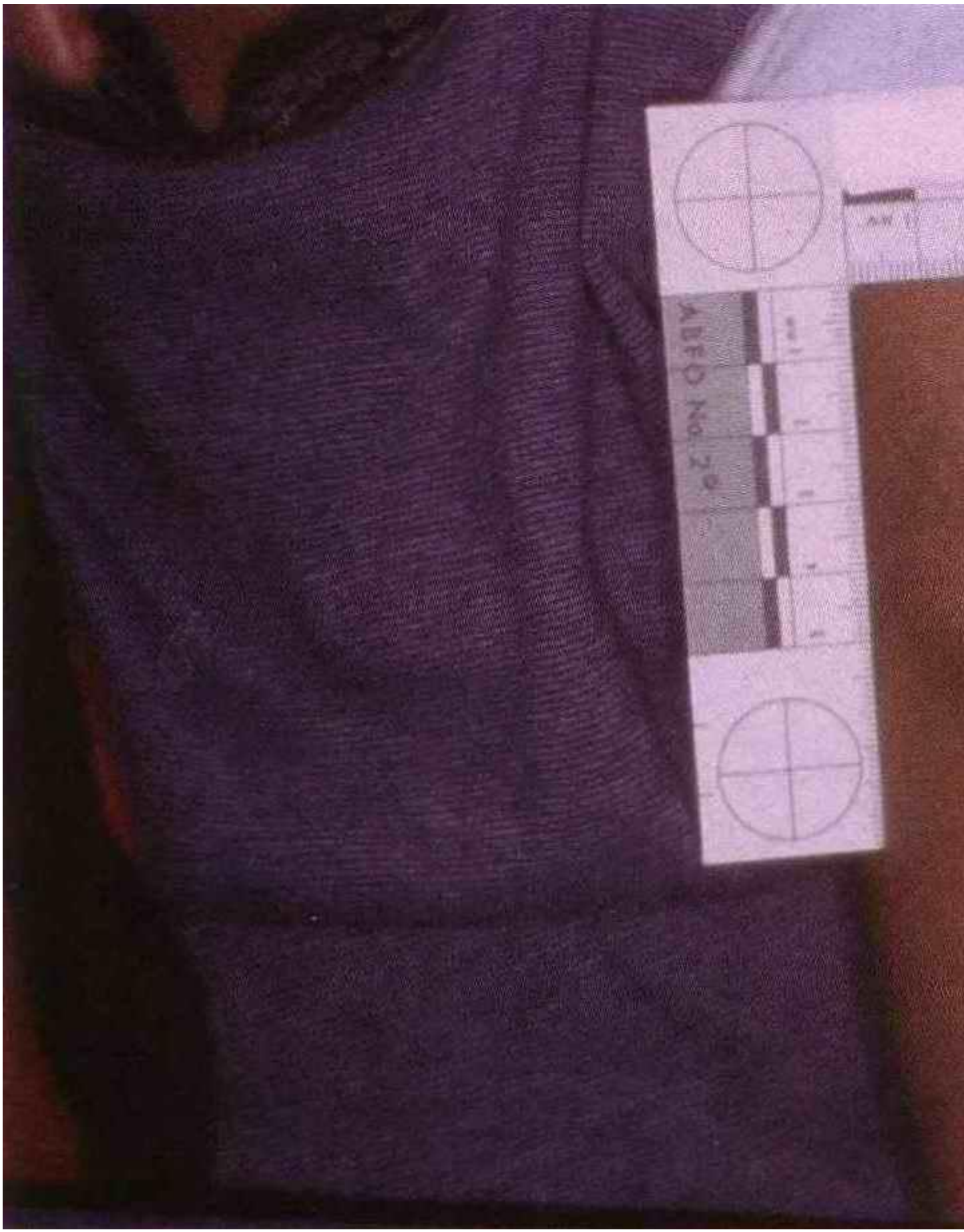
ABFO No. 2

Class II

This bite wound has both class and some individual characteristics. The arches upper (maxillary) and lower (mandible) can be identified. Specific teeth maybe identified. A Class II bite may be used more for exclusion than for inclusion of a suspect (Figures 13.10 and 13.11).

Figure 13.10 Class II bite. (This figure appears on page 160 of this book. Please Click to enlarge)



Class III

This bite will show excellent tooth morphology in at least one arch. Specific teeth shapes and their position in the dental arch can be identified. This class of bitemark can produce a dental profile of the biter as in the Bundy case and will be used for both inclusion as well as exclusion (Figure 13.12). The third dimension or indentations may be present and can help estimate the time the bite was inflicted in relation to the time of death (Figure 13.13).

Figure 13.12 Class III bite. (This figure appears on page 161 of this book. Please Click to enlarge)



Class IV

This bite will be an incision or possibly an excision of the tissue. Blood is present on the surface and DNA may be contaminated. This class of bite is difficult if not impossible to get a profile of the teeth that caused it. However, a Class IV bite will almost always produce a permanent injury or disfigurement (Figure 13.14): the loss of a finger or an ear (Figure 13.15), or a permanent scar.

Figure 13.14 Class IV bite - one year old bite scar (This figure appears on page 162 of this book. Please C enlarge)



The book gives a host of similar information on all aspects of forensic odontology. We are sure our readers would enjoy the book as much as we at the journal office did.

Review by *-Puneet Setia and Avneesh Gupta*





View this book on Amazon

Request a PDF file of this review by clicking here. (If your screen resolution can not be increased, or if printing this page is giving you problems like overlapping of graphics and/or tables etc, you can take a proper printout from a pdf file. You will need an Acrobat Reader though.)