ANIL AGGRAWAL'S

Internet Journal of Forensic Medicine and Toxicology

The world's first online journal devoted entirely to forensic medicine and toxicology · Published 1 January and 1 July

VOL. 10, NO. 2

Downloaded from www.anilaggrawal.com · ISSN 0972-8074 (Online) · https://www.anilaggrawal.com/ij/vol_010_no_002/poster/poster005.html

Poster Session: Poster 5

CITE THIS ARTICLE

Gupta B.D. and Singh, O.G. Rigor Mortis photographed. *Anil Aggrawal's Internet Journal of Forensic Medicine and Toxicology, 2009*; Vol. 10, No. 2 (July - December 2009): ; Published: July 1, 2009,

Email Dr. B.D.Gupta (the corresponding author) by clicking here

Dr. B.D. Gupta (Click to enlarge)



Rigor Mortis photographed

B. D. Gupta* and O.G. Singh**

**** Prof & Head, **Tutor***

Forensic Medicine Department

M.P.Shah Medical College, Jamnagar
India

Case Report

Pictures: Shows shortening and thickening of muscle mass with prominent tendon on both forearms.

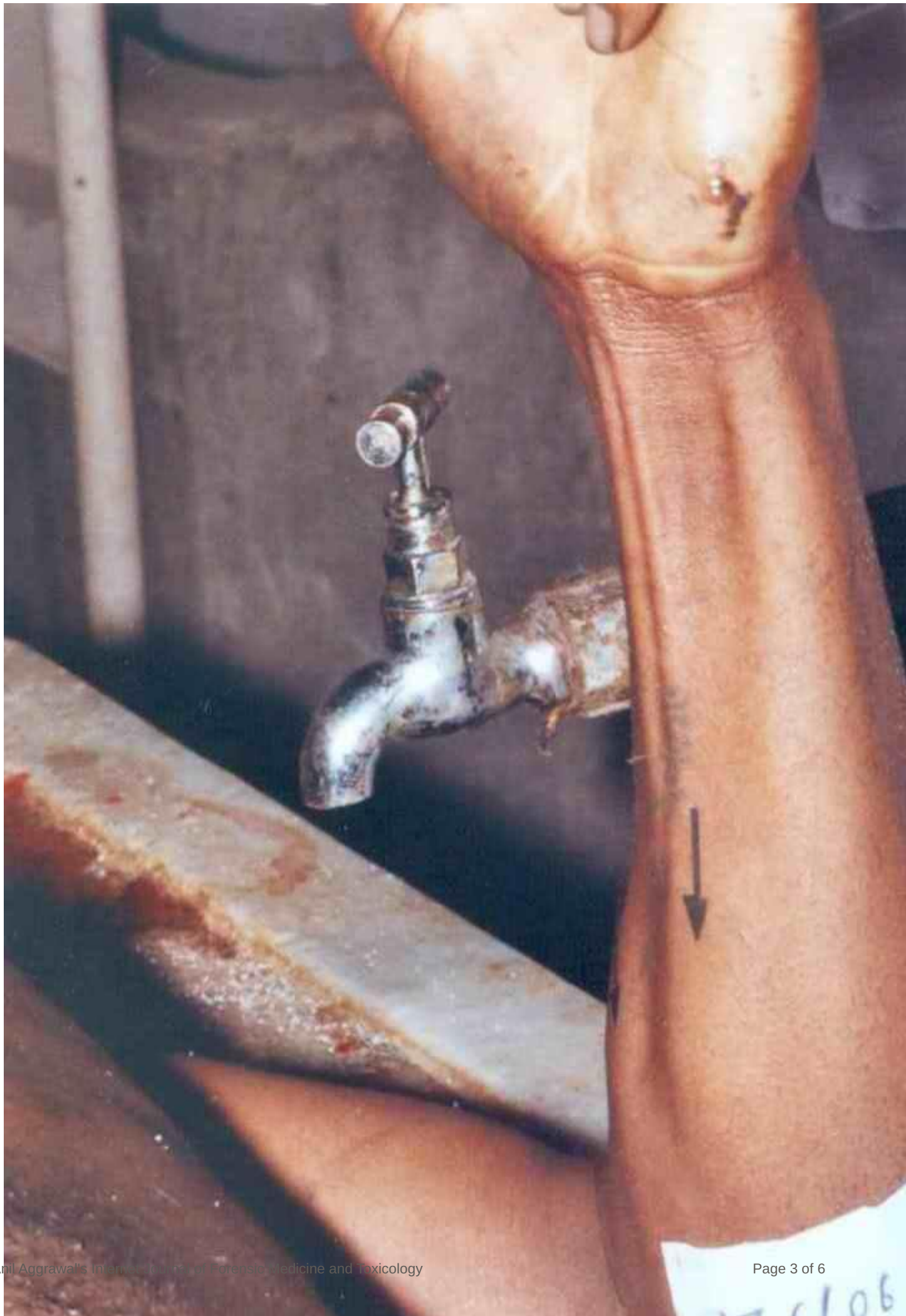

Picture 3: Graze discoloration of side of the trunk



Please click all pics to enlarge

Commonly rigor mortis is better felt than seen. Therefore we do not find photographs of rigor mortis in literature. Here we present one. It was a case of railway accident; therefore multiple injuries were expected. We did find multiple injuries on the body. Looking for such injuries when we examined the forearms we found more or less symmetrical swellings on front of both forearms. We thought that these could be contusions though there was no discoloration externally. (See photographs- there is not even a shade of discoloration in either of them). There was no fracture of underlying bones also. Though it was a case of railway accident, railway accidents are known for bizarre injuries, still it was least probable to have contusions on the front of forearms on both sides simultaneously. At that moment due to stiffness of the forearms and swelling without obvious cause for the same we thought that this could be due to rigor mortis. We dissected the sites and confirmed if there are any internal injuries explaining the swellings. There were none. So here we have rigor mortis photographed. The deceased died due to head injury and fracture of right thighbone.

(N.B. Click all pictures to enlarge!)

*Corresponding author and requests for reprints:
B.D. Gupta
Professor of Forensic Medicine
M.P.Shah Medical College
Jamnagar 361008
India

[Poster 1] [Poster 2] [Poster 3] [Poster 4] [Poster 5]
[Back to Poster Index]