ANIL AGGRAWAL'S
Internet Journal of Forensic Medicine and Toxicology
The world's first online journal devoted entirely to forensic medicine and toxicology · Published 1 January and 1 July

VOL. 10, NO. 2
Downloaded from www.anilaggrawal.com · ISSN 0972-8074 (Online) · https://www.anilaggrawal.com/ij/vol_010_no_002/poster/poster004.html

Poster Session: Poster 4

CITE THIS ARTICLE

Gupta B.D., Vaghela, P.C., Singh, O.G. and Mehta, R. Metastasis in heart from a primary carcinoma of hypopharynx -A rare event. *Anil Aggrawal's Internet Journal of Forensic Medicine and Toxicology, 2009*; Vol. 10, No. 2 (July - December 2009): ; Published: July 1, 2009,

Email Dr. B.D.Gupta (the corresponding author) by clicking here

Dr. B.D. Gupta (Click to enlarge)



Metastasis in heart from a primary carcinoma of hypopharynx -A rare event

***B. D. Gupta**[*], **P. C. Vaghela**[**], **O. G. Singh**[**], **Rahul Mehta**[***]*
**** Prof & Head, **Tutor, ***PG Student***
Forensic Medicine Department

M.P.Shah Medical College, Jamnagar
India

Case Report

Picture 1: Heart shows multiple nodules of metastasis (Please see arrows)

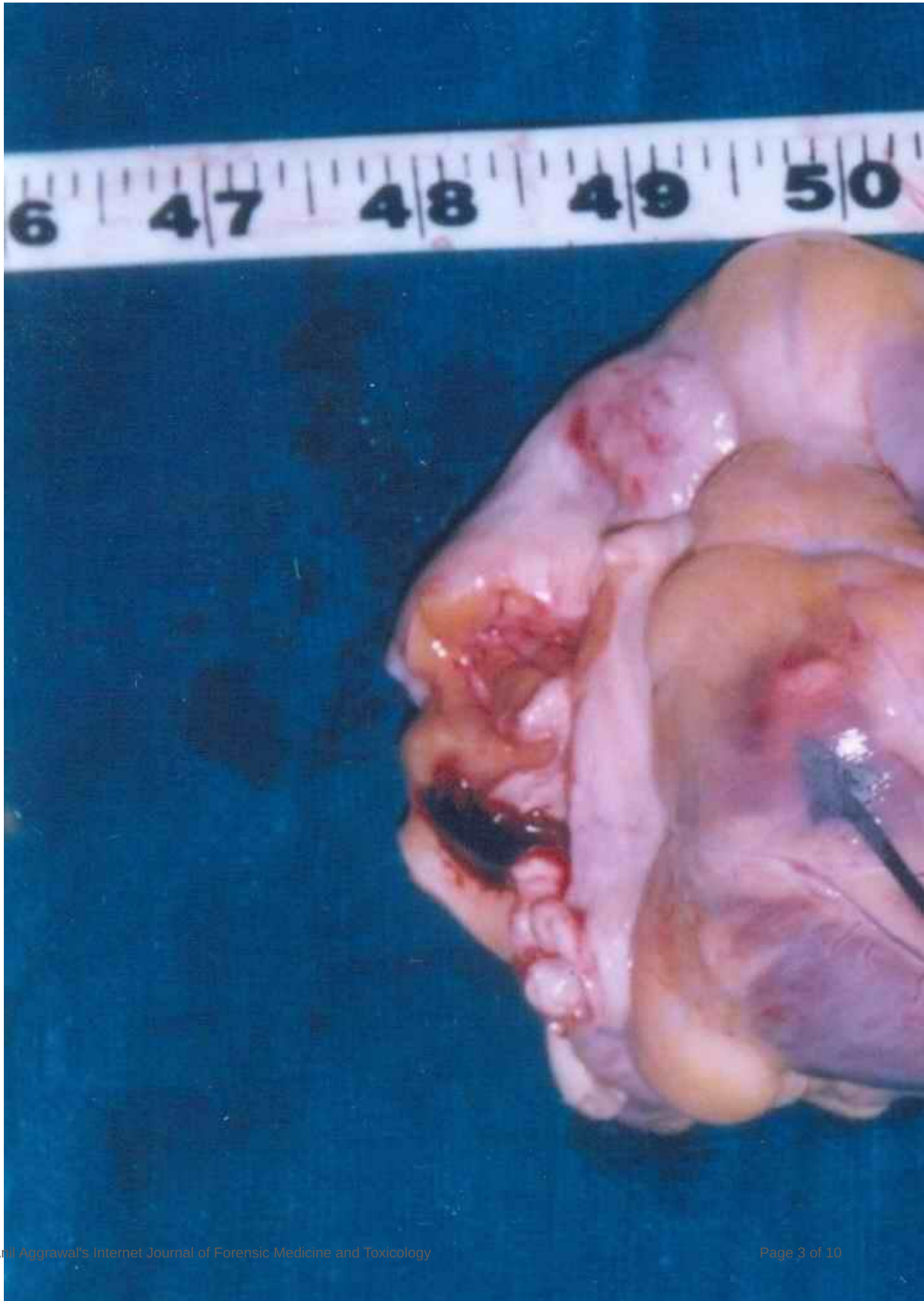
6
47
48
49
50

Picture 4: Heart muscles infiltrated with tumour cells. (x 100). Oval area shows infiltration of tumour c

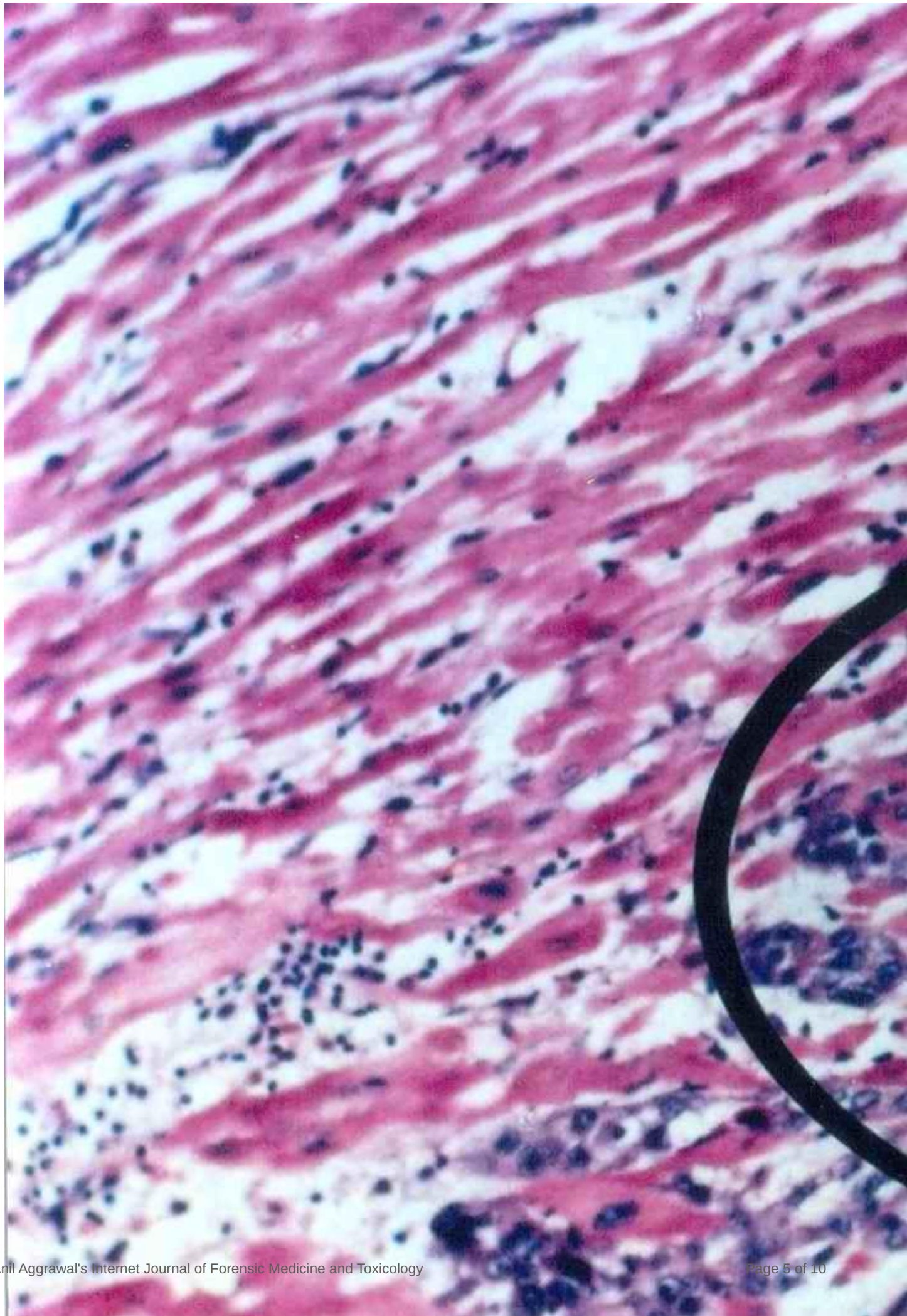

Picture 7: Liver (cut surface) shows multiple nodules of metastasis. (Please see arrows)

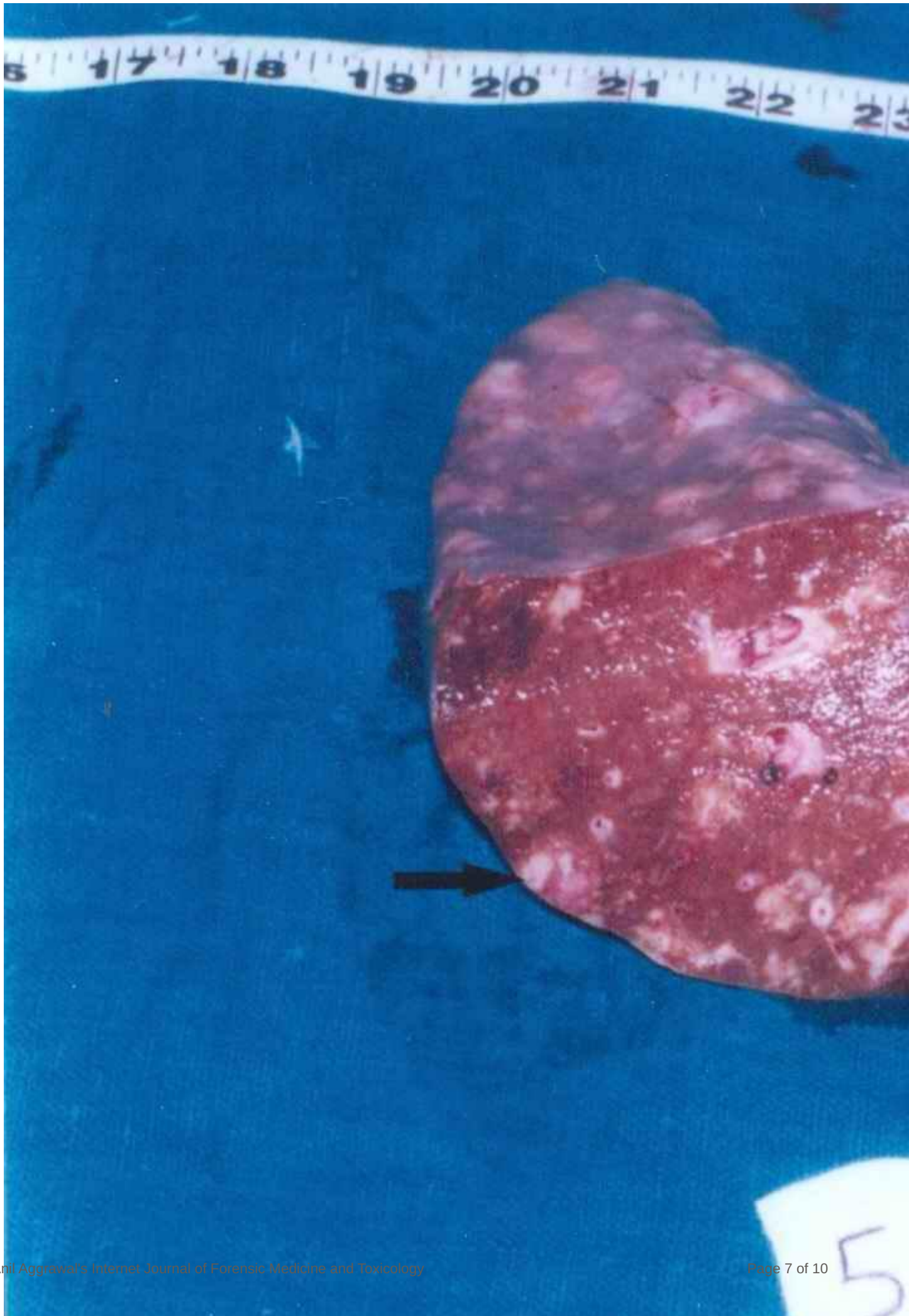
17
18
19
20
21
22

Picture 10: Lung (gross) - upper portion shows firm area, which is cut. Arrow shows nodules of metasta


LEFT
526/05
10/08/05

Please click all pics to enlarge

A case of carcinoma of hypopharynx was brought to the casualty department of G.G. hospital, Jamnagar, Gujarat. The patient was found dead on arrival.

A medico legal postmortem examination was conducted. Photographs are displayed to show gross and microscopic appearance of secondary metastasis in the heart and other organs. Here our main emphasis lies on the cardiac metastasis, which is a very rare event.

(N.B. Click all pictures to enlarge!)

*Corresponding author and requests for reprints:
B.D. Gupta
Professor of Forensic Medicine
M.P.Shah Medical College
Jamnagar 361008
India

[Poster 1] [Poster 2] [Poster 3] [Poster 4] [Poster 5]
[Back to Poster Index]