ANIL AGGRAWAL'S
Internet Journal of
Forensic Medicine and Toxicology
The world's first online journal devoted entirely to forensic medicine and toxicology · Published 1 January and 1 July

VOL. 10, NO. 2
Downloaded from www.anilaggrawal.com · ISSN 0972-8074 (Online) · https://www.anilaggrawal.com/ij/vol_010_no_002/poster/poster003.html

# Poster Session: Poster 3

CITE THIS ARTICLE
Gupta B.D. and Singh, O.G. Spinal cord comes along the removal of brain. Postmortem artifact: Any takers? *Anil Aggrawal's Internet Journal of Forensic Medicine and Toxicology, 2009*; Vol. 10, No. 2 (July - December 2009): ; Published: July 1, 2009,

Email Dr. B.D.Gupta (the corresponding author) by clicking here

**Dr. B.D. Gupta (Click to enlarge)**



## Spinal cord comes along the removal of brain. Postmortem artifact: Any takers?

***B. D. Gupta*** [*] ***and O. G. Singh*** [**]
**** Prof & Head, **Tutor***
***Forensic Medicine Department***

*M.P.Shah Medical College, Jamnagar*
*India*

## Case Report

**Picture 1: Brain and spinal cord in continuity. (see arrow)**



**Picture 3: Attempted erasure of old tattooing on left forearm**

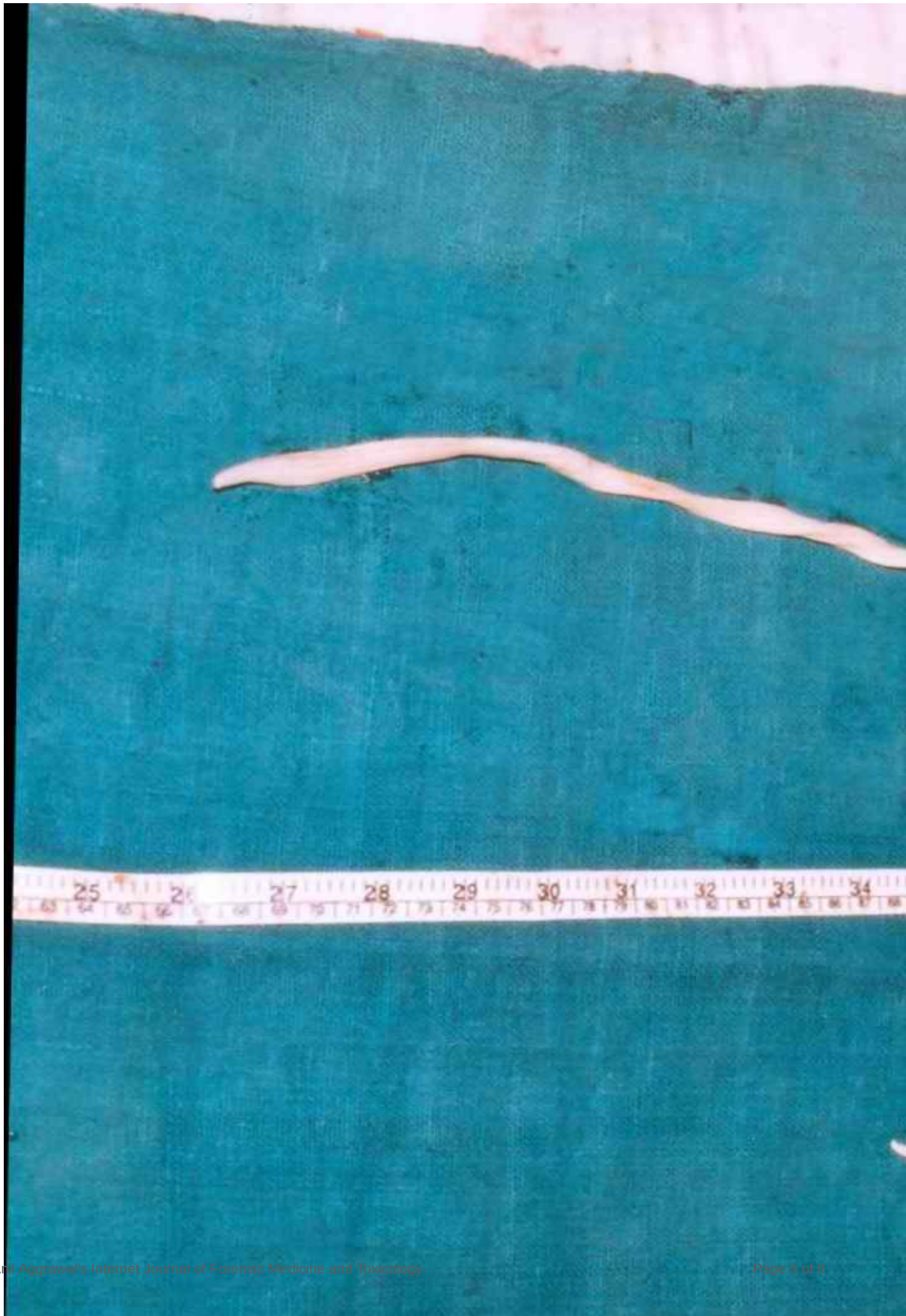
25
27
28
29
30
31
32
33
34

**Please click all pics to enlarge**

While removing the brain after opening the skull in routine manner, to our surprise the whole spinal cord came along with. Within short span of time this happened in another case too. The first case was that of a 13 year old female who had died due to snakebite. The second case was that of a younger victim than the first one, the details of which were not known. Inadvertently we could not label the case and therefore could not find the details. Because of the same reason we could not take its photograph also with whole brain. In our experience of 28 years and about 15,000 autopsies such things happened for first time. Thus our findings can be aptly said to be rare amongst the rarest cases. Simultaneously both the cases occurred in the younger age group and of fresh bodies. Such cases are quite thought provoking. Informally we learn from our colleagues that it happens in cases of dead bodies of children. We tried to search the literature but we could not find any report in this regard. Any takers?

(N.B. Click all pictures to enlarge!)

*Corresponding author and requests for reprints:
B.D. Gupta
Professor of Forensic Medicine
M.P.Shah Medical College
Jamnagar 361008
India

[ Poster 1 ] [ Poster 2 ] [ Poster 3 ] [ Poster 4 ] [ Poster 5 ]
[ Back to Poster Index ]