ANIL AGGRAWAL'S
Internet Journal of Forensic Medicine and Toxicology
The world's first online journal devoted entirely to forensic medicine and toxicology · Published 1 January and 1 July

VOL. 10, NO. 1 · JANUARY – JUNE 2009
Downloaded from www.anilaggrawal.com · ISSN 0972-8074 (Online) · https://www.anilaggrawal.com/ij/vol_010_no_001/papers/paper003.html

Azan-Mallory stain is a useful tool for diagnosing pulmonary thrombosis in a partially decomposed body

Yoshio Yamamoto, Izumi Takase, Ikuo Sakaguchi, Tokiko Nakagawa, Chikako Uemura, Katsuji Nishi

Department of Legal Medicine, Shiga University of Medical Science, Seta-Tsukinowacho, Ohtsu 520-2192, Shiga, Japan

Contact: the corresponding author Katsuji Nishi · nishi@belle.shiga-med.ac.jp

CITE THIS ARTICLE

Yamamoto Y, Takase I, Sakaguchi I, Nakagawa T, Uemura C, Nishi K. Azan-Mallory stain is a useful tool for diagnosing pulmonary thrombosis in a partially decomposed body. *Anil Aggrawal's Internet Journal of Forensic Medicine and Toxicology* [serial online], 2009; Vol. 10, No. 1 (January – June 2009): [about 6 p]. Available from: https://www.anilaggrawal.com/ij/vol_010_no_001/papers/paper003.html

ABSTRACT

We performed autopsies on a 77 year-old woman and her 46 year-old her son. They were both found dead together in a toilet of their apartment house. When they were discovered, decomposition of their bodies had already begun. A large saddle embolus with fibrin tissue and brownish a hard brownish clot were detected in the body of the mother at the bifurcation of the main pulmonary trunk of the mother. Her cause of death was determined as due to pulmonary thrombosis found in the thrombi deep in the veins of her legs via iliac vein. Azan-Mallory staining could revealed the existence of purplish fibrin strands with purplish color in the small-sized arteries and substantial re-canalization of older thrombi in the medium-sized pulmonary artery. These findings indicate that Azan-Mallory staining may be a useful tool to detect the thrombi in a partially-decomposed lung. The cause of the son's death of was determined as the pulmonary edema due to drug overdose, likely incurred by a mental disorder.

Keywords: Pulmonary thrombosis, Decomposed body, Azan-Mallory Stain

Introduction



Figure 1. Death scene of the mother and her son. She is lying on her right side beside the toilet seat with her son on top of her after he presumably fell directly forward. They lay one upon another, namely, the upper half of his body pressed against mother's lower body (Photo 1). The back of his

underwear is pulled up to his right-shoulder, suggesting that the mother tried to pull on his undershirt in order to free herself.

Acute massive pulmonary embolism (PE) carries an exceptionally high mortality rate.[1] Autopsy cases with massive PE have increased gradually over the last decade at our department. Although the large saddle emboli at the bifurcation of the main pulmonary trunk were easily detected in recently deceased bodies, we sometimes encountered autopsies of decomposed bodies with PE, where it is difficult to detect the emboli in the lungs with histological examination. Recently we performed autopsies on a mother (age 77) and her son (age 46). At the beginning of the investigation, police investigators suspected that the son attempted a forced double suicide. However, postmortem examination indicated the time since death was roughly 6 days based on death scene investigation, and the condition of the decomposing bodies. Additional autopsies revealed that the mother died from a massive PE derived from the right iliac vein and the son died from pulmonary edema due to an overdose of anti-depressant drugs. Through the use of Azan Mallory staining, we were able to detect emboli in the small-sized arteries of the decomposed lung.

Case report



Figure 2. Mother's Body at Autopsy - The face is swollen by putrefied gas and the color of the skin is a yellowish green, and large putrid blisters are visible on the skin. No maggots are on her skin, although there were many maggots on his skin.

One day in September a woman (age 77) and her second son (age 46) were found dead in a toilet of their apartment room. She was found lying on her right side beside the toilet seat and her son, who had presumably been sitting straight and fell forward, was found lying on top of her. The upper half of his body pressed against his mother's lower body (Picture 1). The back of his underwear was pulled up to his right-shoulder, suggesting that the mother pulled up his undershirt. When her first son visited and knocked on their door 6 days before their bodies were discovered, there was no reply and the front door was locked. Newspapers from previous days remained in their mailbox. The mother suffered from depression and was hemi-paralyzed. Although the son took care of his mother, he also had a mental disorder. Seven days before their bodies were found, they had gone to the hospital together.

Autopsy findings on the woman

The face was swollen from putrefied gas and the color of the skin was yellowish green, and large putrid blisters were visible on the skin. No maggots were found on the skin (Photo 2).

A small amount of fat fluid was detected in both chest cavities. The fat laden heart flattened from putrefaction but no fibrosis and no stenosis by arteriosclerosis in the coronary arteries was detected.

The significant pathological findings were in the lungs. The lungs were edematous, and a large saddle embolus with fibrin tissue and a hard brownish clot were detected at the bifurcation of the main pulmonary trunk (Photo 3).

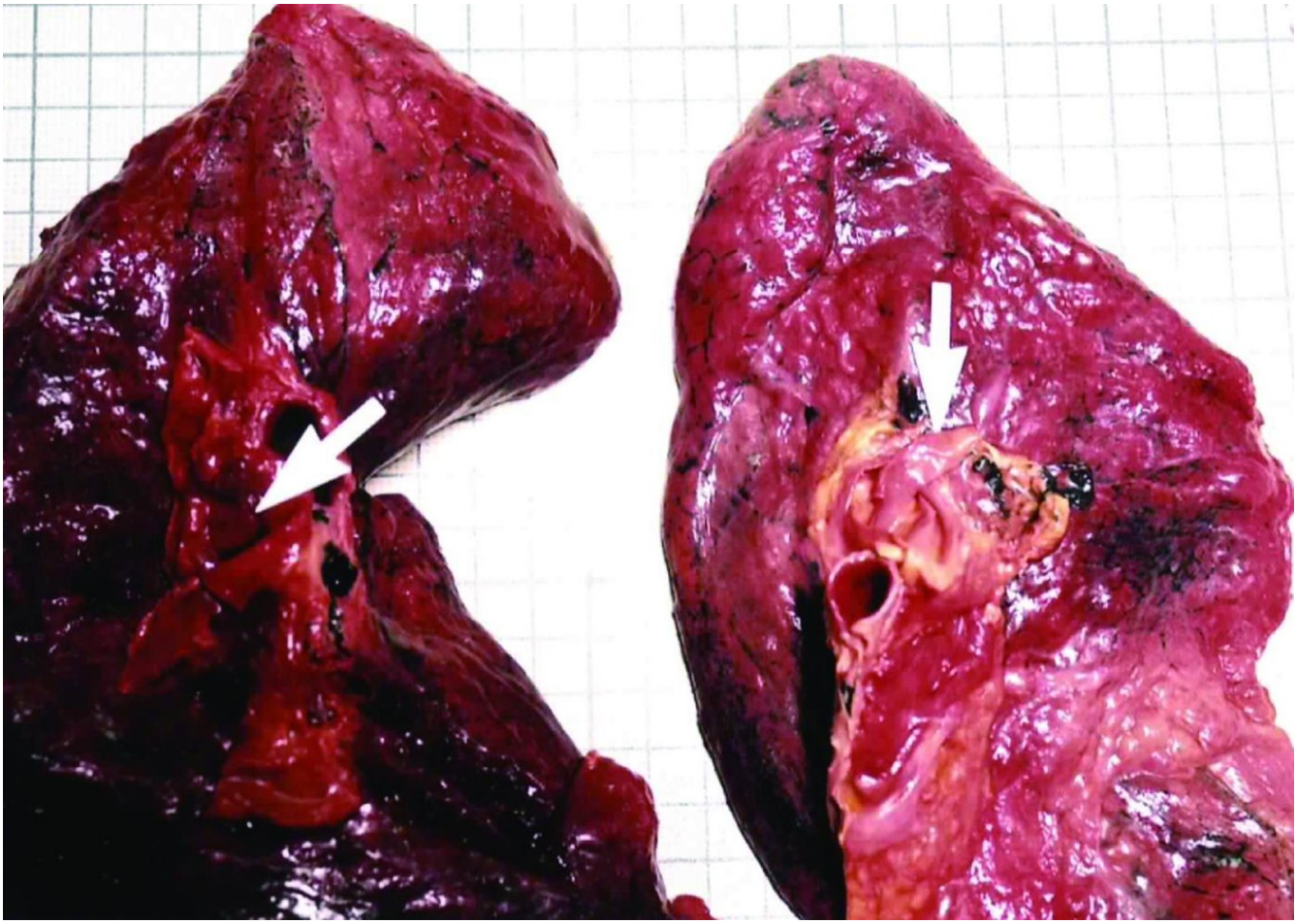

Figure 3. Pulmonary embolism - A large saddle embolus with fibrin tissue and a hard brownish hard clot were detected at the bifurcation of the main pulmonary trunk.

In the abdominal cavity there was a large amount of dissolved fat fluid dissolved from fat tissue of the mesentery and the greater omentum. Each organ in the abdominal cavity had decomposed but kept it's morphology. No food or other residue was recognized in the stomach and the intestine, respectively, and no feces remained in the rectum, although the intestines were intensively expanded by putrefied gas.

A stick-shaped dark brown thrombi (5cm in length, 0.5cm in width) with dark brown color was recognized inside of the right iliac vein (Photo 4-1 and 4-2). Inside of the aorta the blood clot resembling a cord was remained (Photo 5). The urinary bladder contained about 100ml of urine.

The brain had putrefied and become semi-liquefied, however, no bleeding was observed.

Autopsy findings on the son

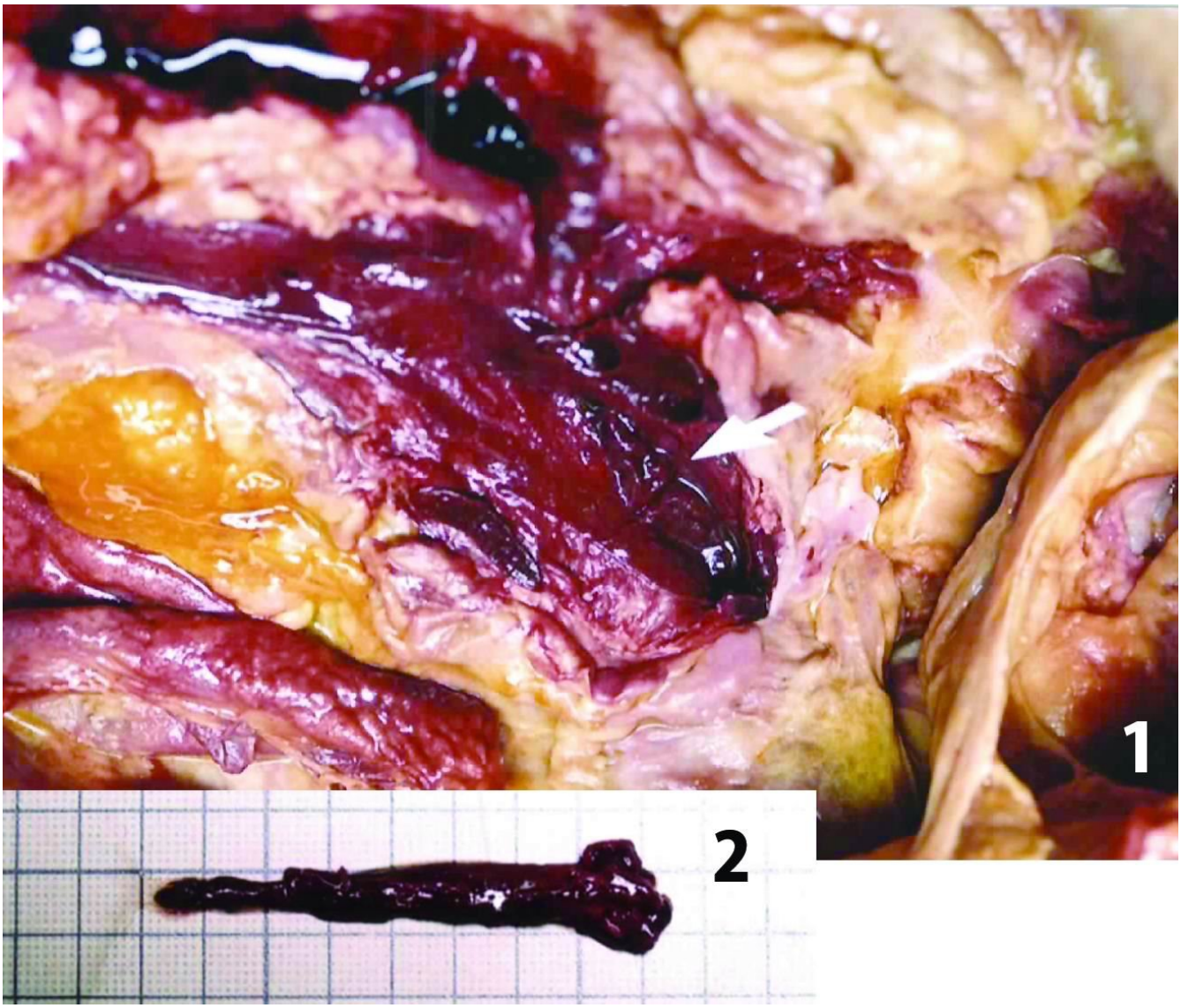

Figure 4. Thrombi - A stick-shaped dark brown hrombi (5cm in length, 0.5cm in width) with dark brown color was found inside of the right iliac vein (Photo 4-1), and the removed thrombi (4-2).

The autopsy findings on the son were similar to that of his mother. The color of his face and chest had changed to black, and his face and chest were infested with maggots. However, his back remained the yellow. The urinary bladder contained 660 ml of urine. The lungs showed severe edema. The stomach and intestines were nearly empty, except a small amount of white semi-liquefied residue with white color. The brain had semi-liquefied, however showed no bleeding.

Toxicological examination

No significant toxicological results were found in the woman by a gas-chromatographic examination.

Toxicological examination of the semi-liquefied residue in the stomach obtained from the son showed the existence of sleeping and anti- depressant drugs.

Histological examination of the lungs from the woman

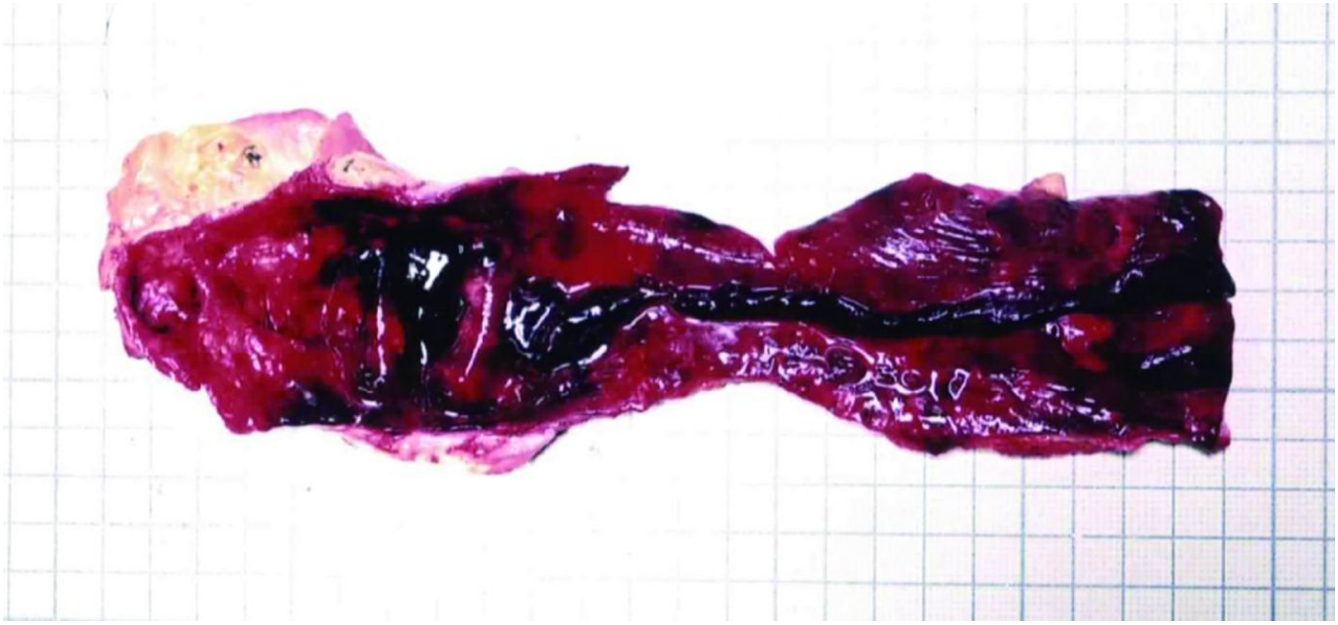

Figure 5. Blood clot in the aorta - Inside of the aorta a blood clot just like as cord wasdetected.

The histological examination of the woman's lungs by Azan-Mallory stain and PTAH stain could revealed the existence of purplish fibrin strands in the small size arteries (Photo 6-1 and 6-2) and of substantial re-canalization of older thrombi in the medium-sized pulmonary arteries (Photo 6-3 and 6-4).

The histological examination of the organs from the son revealed putrefaction in each organ without any other significant pathological findings.

Discussion

Rudolf Virchow[2] proposed a classic triad of local trauma to the vessel wall, hypercoagulability, and stasis as causes of venous thromboembolism. In the present case, a blood clot containing fibrin was observed in the aorta of the woman. This may indicate that her blood had been in a state of hypercoagulability in her blood.

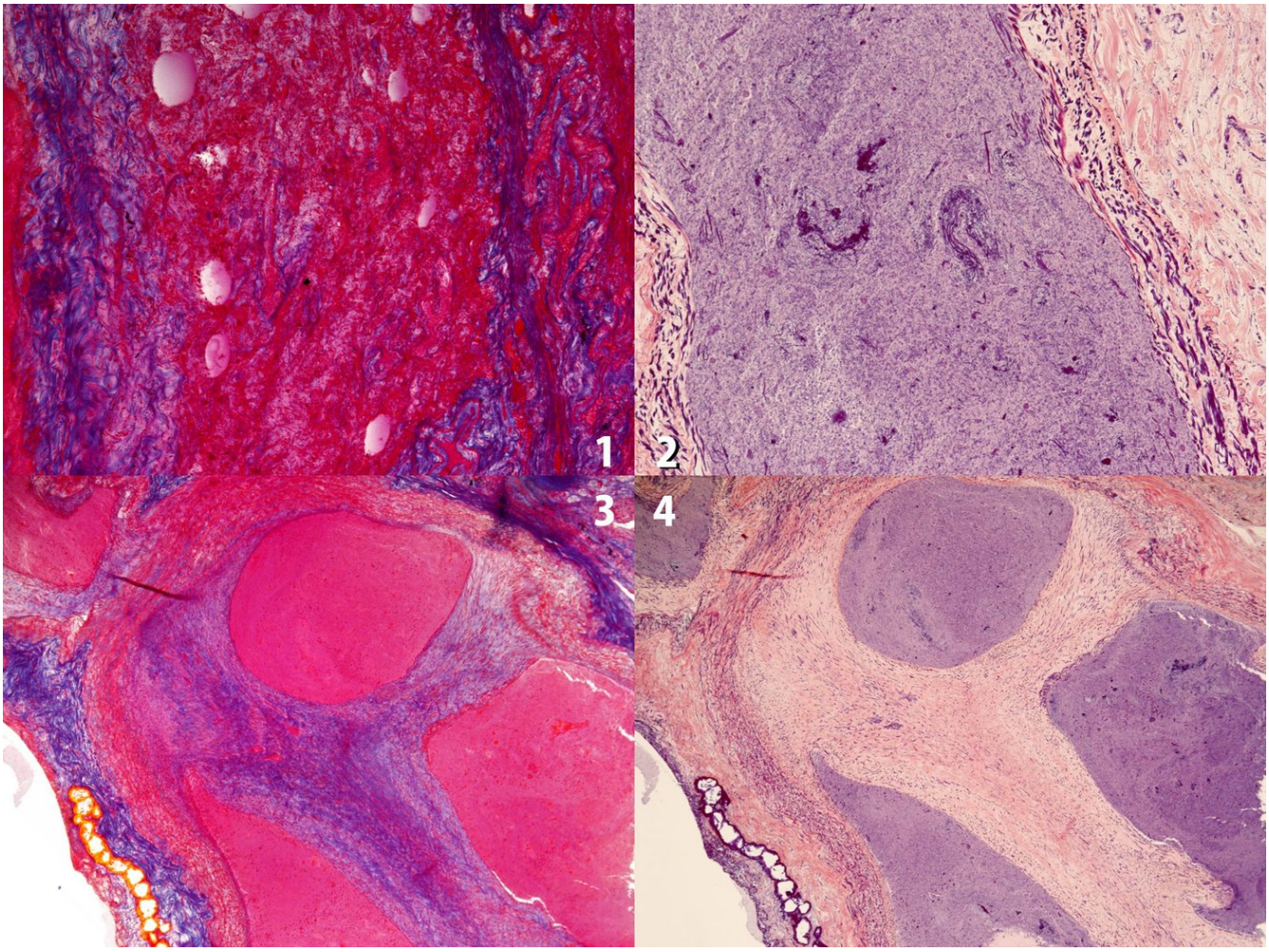

Figure 6. Histological examination of the lungs from the woman - The histological examination of the lungs from the woman using both the Azan-Mallory (AM) stain and PTAH stain could revealed the existence of purplish fibrin strands with purplish color in the small size arteries (6-1 with AM stain and 6-2with PTAH stain) and of the substantial re-canalization of older thrombi in a medium-sized pulmonary artery (6-3 with AM stain and 6-4 with PTHA stain).

Some of the differences between the autopsy findings on the mother and the son indicate that the son's death occurred prior to the mother's death. On is the existence of maggots mainly on his skin and not his mother's skin. Another is his outstretched under-shirt which might have been pulled on by the mother. We presume that he was dead after he died after remaining unconscious for several hours due to his drug overdose, since sleeping pills and anti-depressants were detected in his large amounts in his urine. The death scene of these two subjects suggests that the mother could not move due to the pressure of her son on her legs, although she tried to lift his body by pulling on his undershirt. She must have been pinned to the floor under her son in a cramped position, similar to the so-called coach-class syndrome or economy class syndrome.

Pulmonary embolism ranges from incidental, clinically unimportant thromboembolism, to massive embolism with sudden death. Although massive PE with fibrin or organized tissue at the bifurcation of the main pulmonary trunk can easily be detected even in a decomposed body, it was a little somewhat difficult to detect the emboli in the middle sized or peripheral arteries of the decomposed body, since erythrocytes in the clot were completely destroyed during the prolonging postmortem interval Azan stain is the improved version by Heidenhain of the collagenous fiber

dyeing method (Mallory stain) using acid fuchsin devised by Mallory originally. It is also called as the Azan-Mallory stain.[3]

The Azan-Mallory stain is one of several commonly used techniques in which three or more dyes are combined. These multiple-dye stains have the advantage of showing a large number of tissue structures. The Azan-Mallory's stain combines aniline blue, orange G (stains proteins) and acid fuchsin (stains DNA and RNA). Collagen-containing connective tissue is shown as blue, erythrocytes as orange, and chromatin, nucleoli, basophilic cytoplasm, and muscle cell cytoplasm as red. With azocarmine and aniline blue (Azan) stain, a combination of the basophilic dye (azocarmine) with aniline blue stains nuclei and basic structures are stained red and collagen, mucus, and cartilage matrix are stained blue.[4] The Azan-Mallory stain method is still used today for detecting many components of tissue from many organs.[5 , 6 , 7]

The histological examination of the lungs of the woman using the Azan-Mallory stain revealed the existence of purplish fibrin strands in the small-sized arteries (Photo 6-1). The stained result was clear compared to that with PHAT (Photo 6-2). Fibrin strands were recognized in the massive haemolysed erythrocytes showing a one day duration of thrombosis.[3] In the medium-sized pulmonary artery, substantial re-canalization of older thrombi was intensively detected (Photo 6-3) by Azan-Mallory stain compared with that by PTAH (Photo 6-4). It is believed that the substantial canalization occurred over three months.[8] These findings combined with the autopsy results show that the woman had been in ill with recurrent pulmonary thrombosis.

Conclusion

At the beginning of the investigation, the police investigators suspected that the son attempted a double suicide. However, autopsy results combined with the evidence from the death scene revealed that the mother died from pulmonary thrombosis and the son died due to a drug overdose perhaps caused by his mental disorder.

The Azan-Mallory staining method is one of the useful tools to detect thrombi in the lungs of a partially decomposed body.

References

1. Ro A, Kageyama N, Tanifuji T, Kobayashi M, Takada A, Saito K, Murai T. Histopathological study of pulmonary arteries in 14 autopsy cases with massive pulmonary thromboembolism. Leg Med (Tokyo) . 2003 Mar; 5 Suppl 1 :S315-7
2. Virchow RLK: Cellular Pathology As Based Upon Physiological And Pathological Histology. 7th American ed., Frank Chance (Translator). New York, NY:1860, 236.
3. Otsuka S., Daily dyeing method guidance for histopathology and cytodiagnosis. (2) Daily dyeing method of connective tissues. A) Dyeing method of collagenous fiber. Azan stain. Modern Medical Laboratory . 2001; 29(7) :640-3.
4. Virtual Histology Lab: Available at http://casweb.ou.edu/pbell/histology/Outline/cell.html
5. Matsuyama TA, Inoue S, Tanno K, Makino M, Ogawa G, Sakai T, Kobayashi Y, Katagiri T, Ota H. Ectopic nodal structures in a patient with atrial tachycardia originating from the mitral valve annulus. Europace . 2006 Nov; 8(11) :977-9.

6. Horikawa M, Fujimoto M, Hasegawa M, Matsushita T, Hamaguchi Y, Kawasuji A, Matsushita Y, Fujita T, Ogawa F, Takehara K, Steeber DA, Sato S. E- and P-selectins synergistically inhibit bleomycin-induced pulmonary fibrosis. Am J Pathol . 2006 Sep; 169(3) :740-9.
7. Aoki J, Ikari Y, Nakajima H, Mori M, Sugimoto T, Hatori M, Tanimoto S, Amiya E, Hara K. Clinical and pathologic characteristics of dilated cardiomyopathy in hemodialysis patients. Kidney Int. 2005 Jan; 67(1):333-40.
8. Knight B., Dating of pulmonary emboli and deep vein thrombi. In Forensic Pathology, pp, 310-311, Bernard Knight, Edward Arnold (A division of Hodder and Stoughton, London), 1991.