ANIL AGGRAWAL'S

Internet Journal of Forensic Medicine and Toxicology

The world's first online journal devoted entirely to forensic medicine and toxicology · Published 1 January and 1 July

VOL. 9, NO. 1 · JANUARY – JUNE 2008

Downloaded from www.anilaggrawal.com · ISSN 0972-8074 (Online) · https://www.anilaggrawal.com/ij/vol_009_no_001/papers/paper004.html

A Case of Impacted Bullet on a Rare Site

Basant Lal Sirohiwal[1], Daya Sirohiwal[2], Luv K. Sharma[3], Swati Sirohiwal[4]

[1]Professor, Forensic Medicine, Pt. B.D. Sharma PGIMS, Rohtak, India
[2]Professor, Gynaecology and Obstetrics, Pt. B.D. Sharma PGIMS, Rohtak, India
[3]Associate Professor, Forensic Medicine, Pt. B.D. Sharma PGIMS, Rohtak, India
[4]III yr MBBS student, All India Institute of Medical Sciences, New Delhi, India

Contact: Basant Lal Sirohiwal · drbasantsri@gmail.com

CITE THIS ARTICLE

Sirohiwal BL, Sirohiwal D, Sharma LK, Sirohiwal S. A Case of Impacted Bullet on a Rare Site. *Anil Aggrawal's Internet Journal of Forensic Medicine and Toxicology* [serial online], 2008; Vol. 9, No. 1 (January – June 2008): [about 8 p]. Available from: https://www.anilaggrawal.com/ij/vol_009_no_001/papers/paper004.html

ABSTRACT

The authors present a rare case of a gunshot wound, where the bullet, after tracing a complicated course within the body came to lodge in the head of the femur.

Keywords: Impacted Bullet, Firearm wounds, Atypical injury

Case Report



Figure 1. Picture showing firearm entry wound with abraded collar, more so marked on left side of wound situated on the right front lower middle aspect of abdomen.

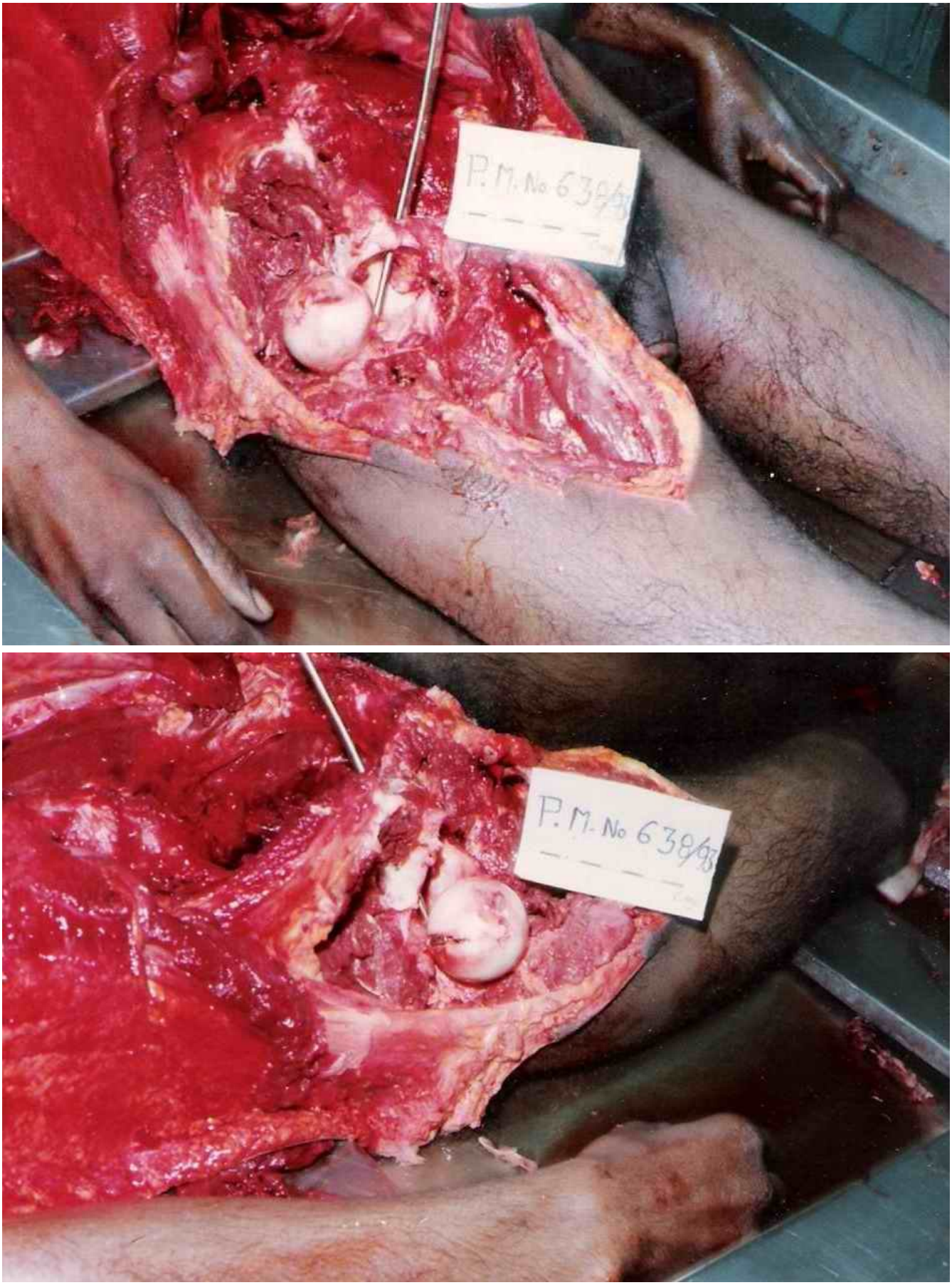

Figure 2a (top) and 2b (bottom). Probe in the acetabulum indicating track of bullet, found impacted in the head of femur, when rotated laterally after opening the right hip joint in situ.

A well built identified male of 20 years age was brought dead to Maulana Azad Medical College, New Delhi with a history of firearm injury. The different photographs taken during the post-mortem examination clearly point out the occurrence of crime and help in reconstruction of the path taken by the bullet in the body.

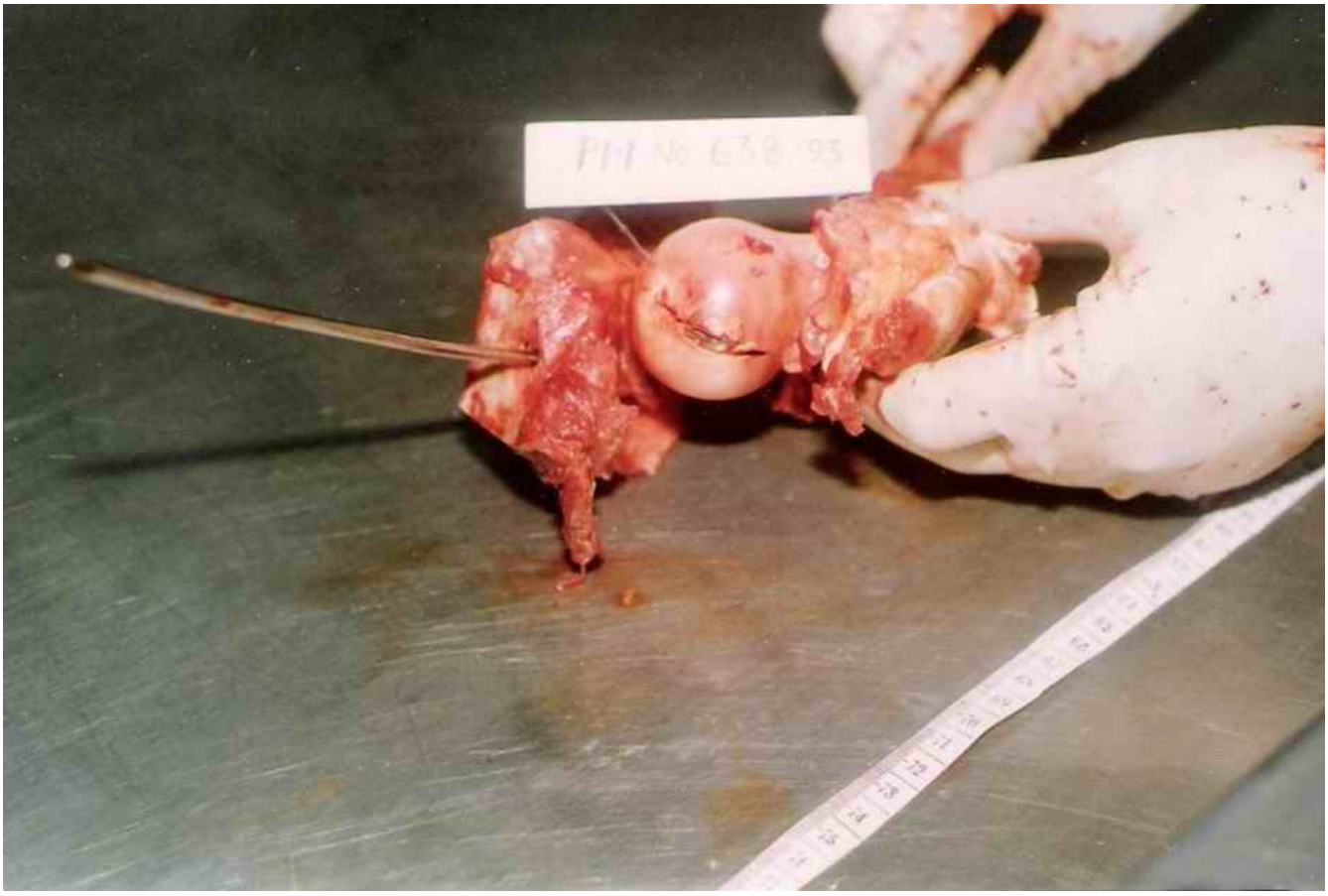
PM No 638/95

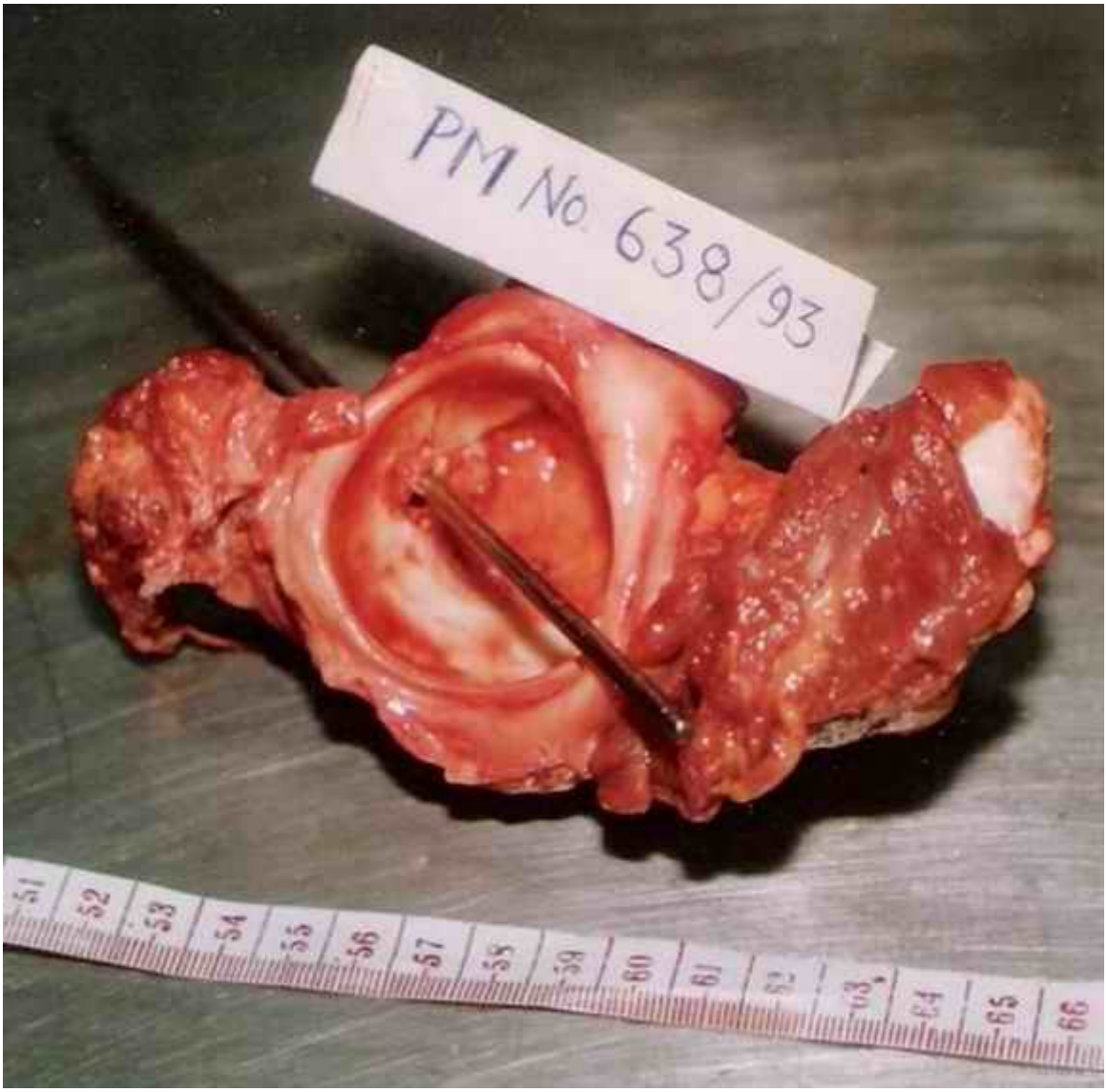
PM No. 638/93

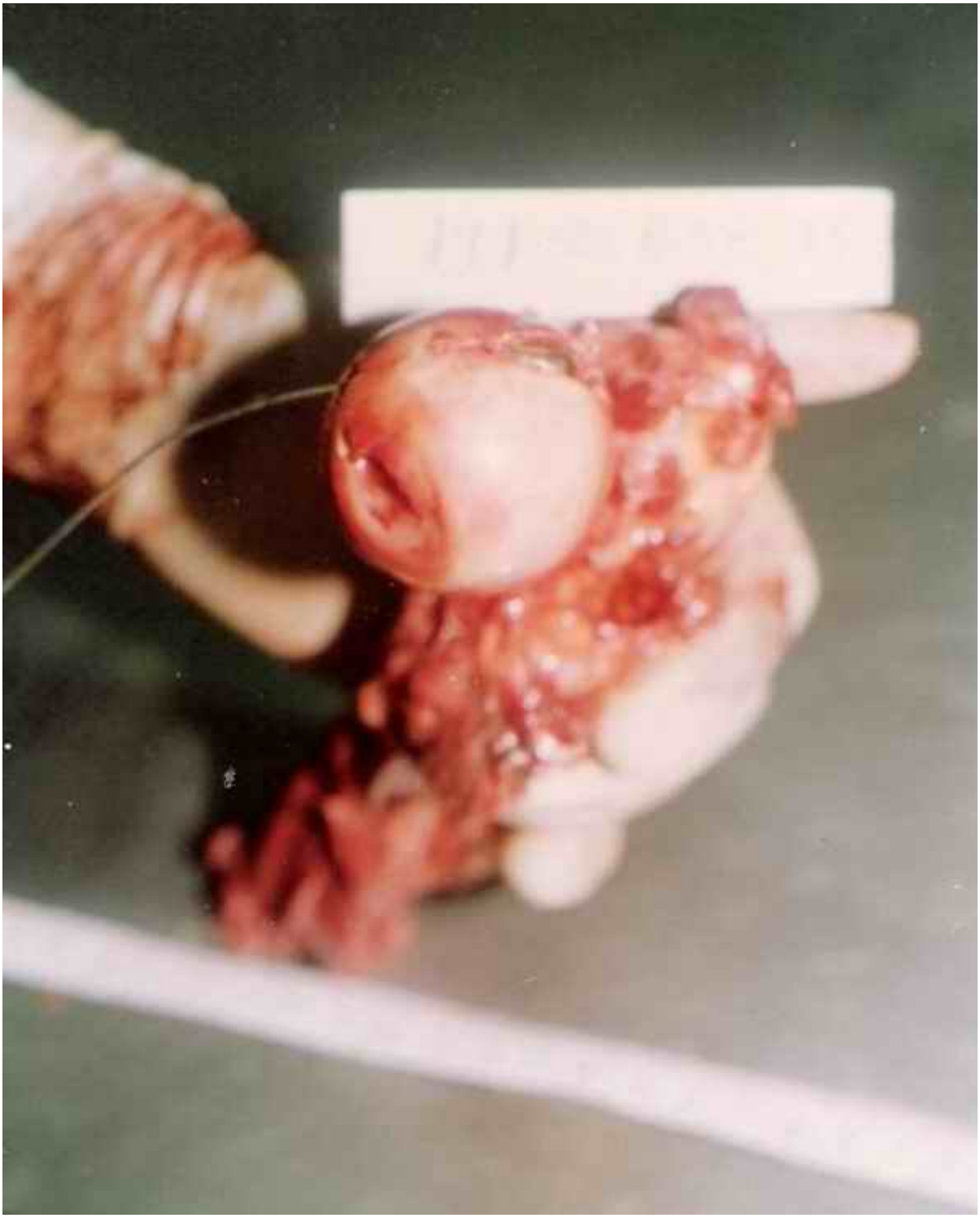

Figure 3a (top), 3b (middle) and 3c (bottom). The acetabulum and upper part of femur were removed after dissection. The track was reconstructed.

Post-Mortem Findings

Dead body of a well built male with eyes closed and cornea hazy. Blood stains as streaks were present on the left lower front of abdomen & groin. Blood oozed out of the abdominal wound on slight pressure. Post-mortem staining was present on the back. Rigor mortis was in the developing phase.

External injuries

Rifled firearm ammunition entry wound 1 cm× 0.9 cm × abdominal cavity deep, situated on the lower middle front of right abdomen, 2 cm from midline, 7.5 cm below level of umbilicus, 9 cm inner and at the level of right anterior iliac spine and 91 cm above the right heel. Abrasion collar was present, more so on inner aspect of the wound in an area of 0.2 cm. There was no singeing, blackening or tattooing present around the wound.

Internal injuries

Peritoneum was showing a wound below the above injury with 2.5 liters of fluid blood in the peritoneal cavity. The caecum was showing a through and through wound. There was extensive effusion of blood in the retro-peritoneal space. All organs were pale and healthy. The big vessels of the abdominal cavity i.e. external and internal iliac were found to be injured. The psoas muscle showed a wound on its lower aspect near and above the acetabular area. Right iliac bone on upper aspect of acetabulum in its middle showed a bullet entry hole with radiating fractures on both sides. Acetabulum showed an exit wound in its upper middle aspect with shattering of bone pieces which were felt in the hip joint after opening it. The head of the femur showed an entry hole in its front inner middle aspect with the bullet traveling into the bone, found impacted and visible on its upper middle back aspect with a radiating fracture upto the neck. There was extensive effusion of blood into and around the hip joint.

Cause of death











Figure 4a (top left), 4b (top right), 4c (middle left), 4d (middle right)& 4e (bottom). The upper part of femur with head was cleaned and the bullet was removed and placed on the side from where it was found impacted.

The cause of death In this case was haemorrhage and shock consequent upon injuries to intestines and big vessels by firearm projectile discharged from a conventional rifled firearm from a distant range.

Conclusion

Bullets in some cases may come to rest within the body in rather obscure situations. It is imperative on the part of the forensic pathologist to look for the bullet, and even go for special examinations such as X-rays and MRI etc if the localization is difficult by ordinary means.