ANIL AGGRAWAL'S
Internet Journal of Forensic Medicine and Toxicology
The world's first online journal devoted entirely to forensic medicine and toxicology · Published 1 January and 1 July

VOL. 8, NO. 1 · JANUARY – JUNE 2007
Downloaded from www.anilaggrawal.com · ISSN 0972-8074 (Online) · https://www.anilaggrawal.com/ij/vol_008_no_001/papers/paper001.html

Immuno-histochemical characteristics of necrotic area in the old-infarction area of human brain by using of antibodies against cystatin C, Cathepsin B, puromycin sensitive alanyl-aminopeptidase and Prostaglandin D2 synthase - A preliminary examination

Aki K. Kobayashi, Izumi Takase, Tomoaki Kitamura, Aiko Takamure, Tokiko Nakagawa, Misuzu Ohyagi, Akira Morimoto, Shigeru Yamasaki, Yoshio Yamamoto, Iwao Ohkubo, Katsuji Nishi

Department of Legal Medicine, Shiga University of Medical Science, Seta-tsukinowa-cho, Ohtsu, Shiga 520-2192, Japan

Contact: the corresponding author Aki K. Kobayashi · katarina36@iris.eonet.ne.jp

CITE THIS ARTICLE

Kobayashi AK, Takase I, Kitamura T, Takamure A, Nakagawa T, Ohyagi M, Morimoto A, Yamasaki S, Yamamoto Y, Ohkubo I, Nishi K. Immuno-histochemical characteristics of necrotic area in the old-infarction area of human brain by using of antibodies against cystatin C, Cathepsin B, puromycin sensitive alanyl-aminopeptidase and Prostaglandin D2 synthase - A preliminary examination. *Anil Aggrawal's Internet Journal of Forensic Medicine and Toxicology* [serial online], 2007; Vol. 8, No. 1 (January – June 2007): [about 18 p]. Available from: https://www.anilaggrawal.com/ij/vol_008_no_001/papers/paper001.html

ABSTRACT

Brain infarction is occasionally encountered at forensic autopsy cases. Since the extent of infarct area and degenerative process are very diverse, it is not easy for forensic pathologists to recognize and decide the extent of old-necrotic area in the infarct lesion of the brain by hematoxylin eosin staining. We examined histochemical characteristics of the old infarct area by antibodies against cystatin C, cathepsin B, and puromycin sensitive amino-peptidase, and prostaglandins D2 synthase, as a preliminary study for resolving the process of degenerative or necrotic changes in the brain infarction. The results obtained in this study revealed that these substances were expressed in the infarct area in relation to degeneration or protection of the infarct tissue. Among them, cystatin C and cathepsin B were predominantly expressed in the infarct area. The Cystatin C was expressed in the amorphous substance and collagen like net substance adjacent to non-affected area, showing clearly boundary between necrotic and normal area. Cathepsin B was expressed mainly in macrophages in the necrotic

cave. These results indicate that anti- Cystatin C is a useful tool to detect and determine the boundary of necrotic area in the old infarction of the brain.

Keywords: Cystatin C, Prostaglandin D2 synthase, Brain infarction

Introduction

The cerebrospinal fluid contains several kinds of predominantly brain-derived proteins including cystatin C (CC), proteases such as cysteine proteases, and puromycin sensitive amino-peptidase (PSA), and prostaglandins D2 synthase, which may be reflected by the pathological changes of the brain.

Cystatin C (CC) is a potent endogenous inhibitor of the cysteine proteases, and involve in regulation of local inflammation[1] and tumor invasion and metastasis.[2] CC is up regulated in degenerated neurons in the hippocampal subregion CA1 after global ischemia in the rat[3] suggesting a role in the neuronal death after cerebral ischemia. CC is produced by all nucleated cells, including neuroendcrine cells and cortical neurons.[4]

Cathepsin B, H, L and S, a family of the cysteine proteases, distributed widely in various tissues and involved in various biological processes such as degradation of cellular proteins, regulation of pro-enzymes and pro-hormones[5,6] and the enzyme activity of cathepsins B (CB) and L increase in the pyramidal neurons in the cornu Ammonis (CA) 1 sector of the hippocampus 3-5 days after ischemia.[7]

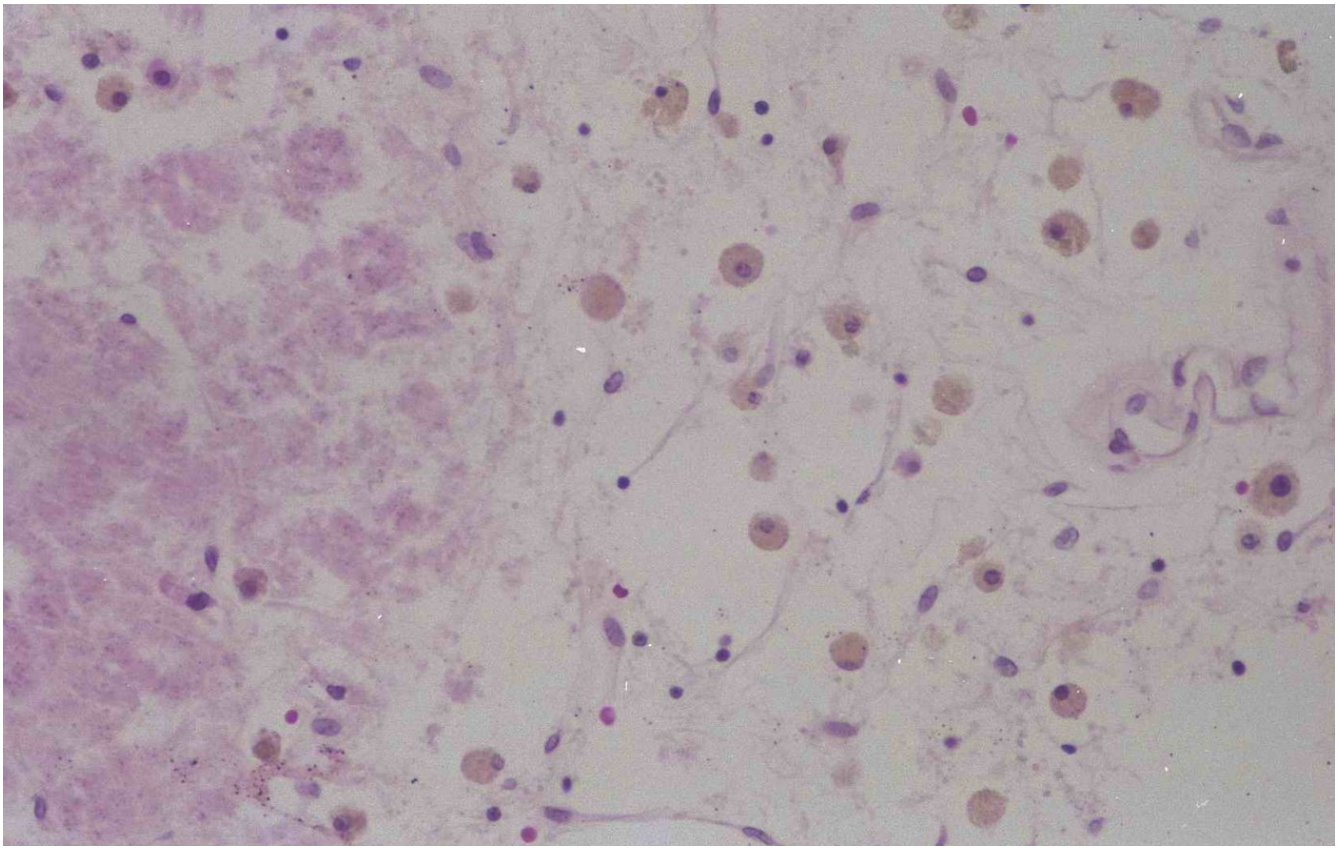

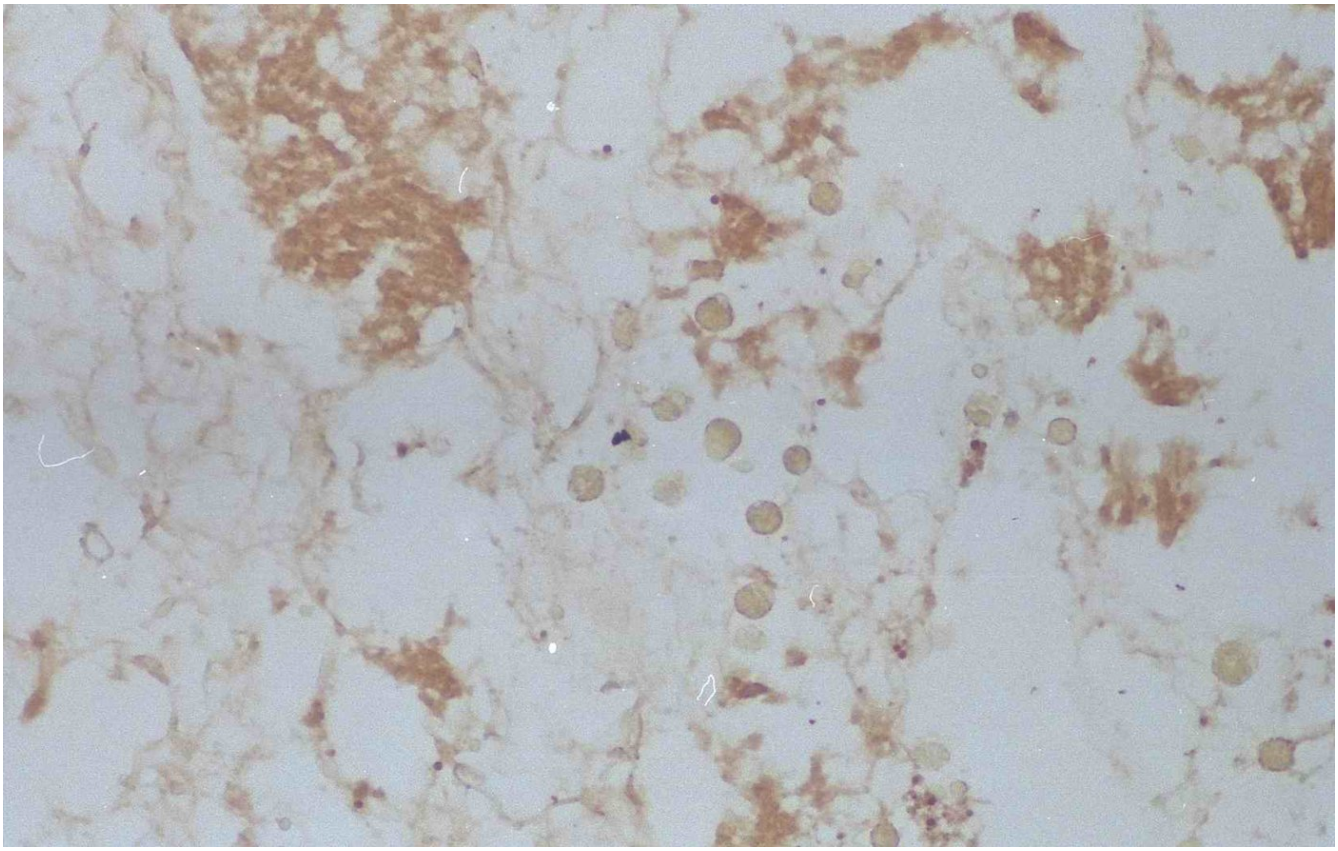

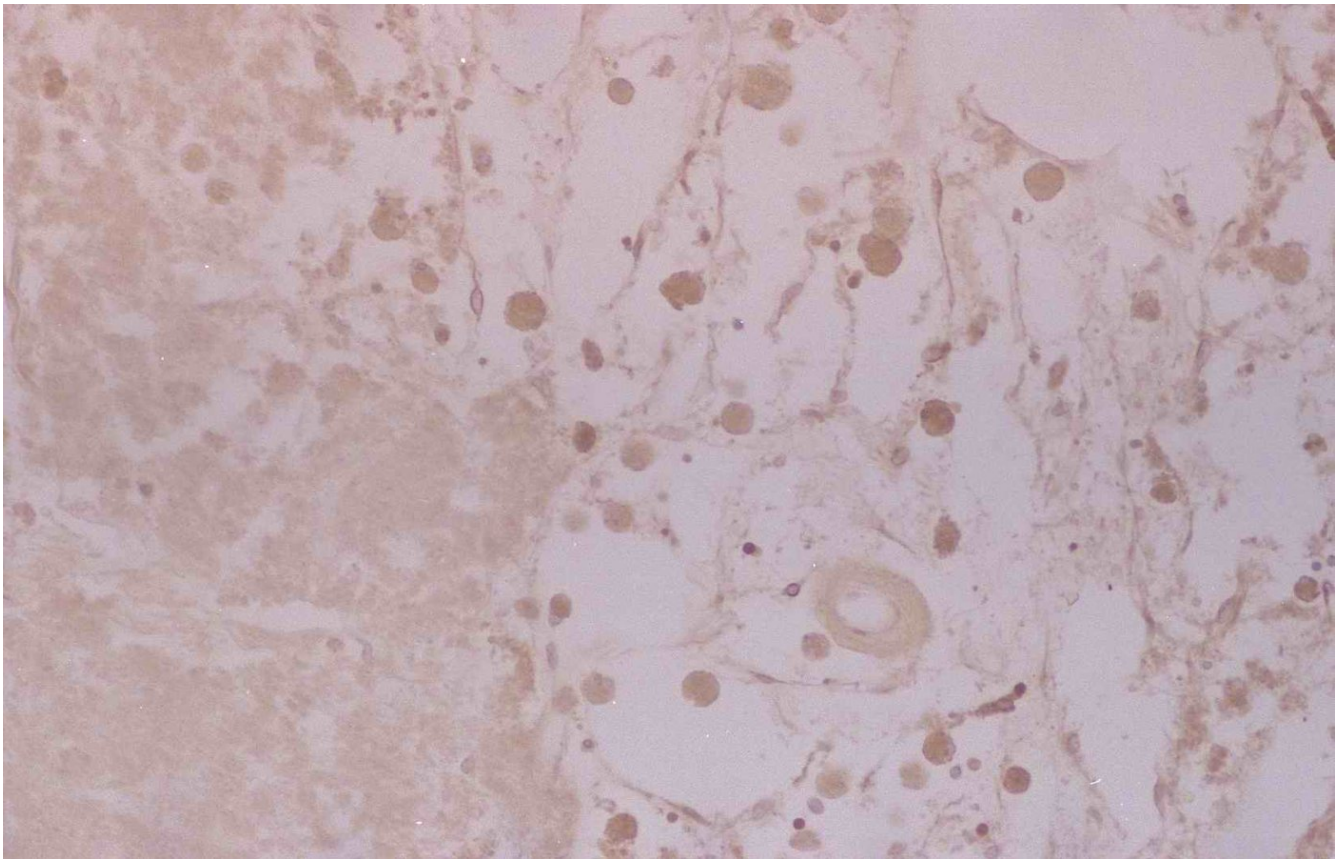

Figure 3. Old infarct area in the cerebellum from an individual (autopsy no.0636). Small vessels, capillaries, are increased and numerous macrophage-like cells infiltrate in to the center of the infracted area. Amorphous materials also exist in the center by HE stain like as islands (3-A). Anti CC stains the amorphous material and shows weak reactivity with macrophage-like cells (3-B). The macrophage-like cells are intensively stained by anti CB (3-C). Anti PSA and anti PGDS show weak reactivity with the macrophage-like cells.

Several studies have reported that the chronic administration of opioids induce changes in the biosynthesis of endogenous opioid peptides or their precursors in the specific brain regions of the adult central nervous system.[8] A major pathway in enkephalin degradation occurs via cleavage of the Tyr-Gly amide bond by aminopeptidase.[9] We reported that puromycin sensitive aminopeptidase (PSA) was expressed in human brain tissues.[10]

The prostaglandin D2 synthase (PGDS) is produced in the choroids plexus and secreted into cerebrospinal fluid is also detected in neurons of medulla oblongata and Purkinje cells in the cerebellum.[11] The PGDS converts prostaglandin H into prostaglandin D2, and cyclooxygenase-2, a rate-limiting enzyme in prostaglandin synthesis because of production of prostaglandin H, mediates the induction of prostaglandin synthesis during the inflammatory response in vivo in many organs including brain.[11]

We purified CC and PGDS from combined human cerebrospinal fluid, PSA from human liver and CB from seminal fluid, and produced rabbit polyclonal antibodies against these biological materials.[12,13,14,15] These four substances detected both in the brain and cerebrospinal fluid may play important roles in the central nervous system.

It is not easy for forensic pathologists to recognize and determine the extent of old-necrotic area in the infarct lesion of the brain by HE stain. In this study we examined the staining patterns in the

degenerated or necrotic human brain tissue in the old infarction with antibodies against CC, CB, PSA or PGDS. Although many investigators reported inducement of proteases and/or protease inhibitors in the early stage of infarction,[3,7] few study was made concerning to the expression of these protein in the progressive area of the brain infarction. The results obtained in the present study revealed that anti-CC antibody is a most useful tool to decide the necrotic region in the old-infracted brain lesion and indicated that CC, CB, PGDS and PSA were expressed in astrocytes or microglia cells surrounding the ischemic region, although their role might vary in the necrotic area.

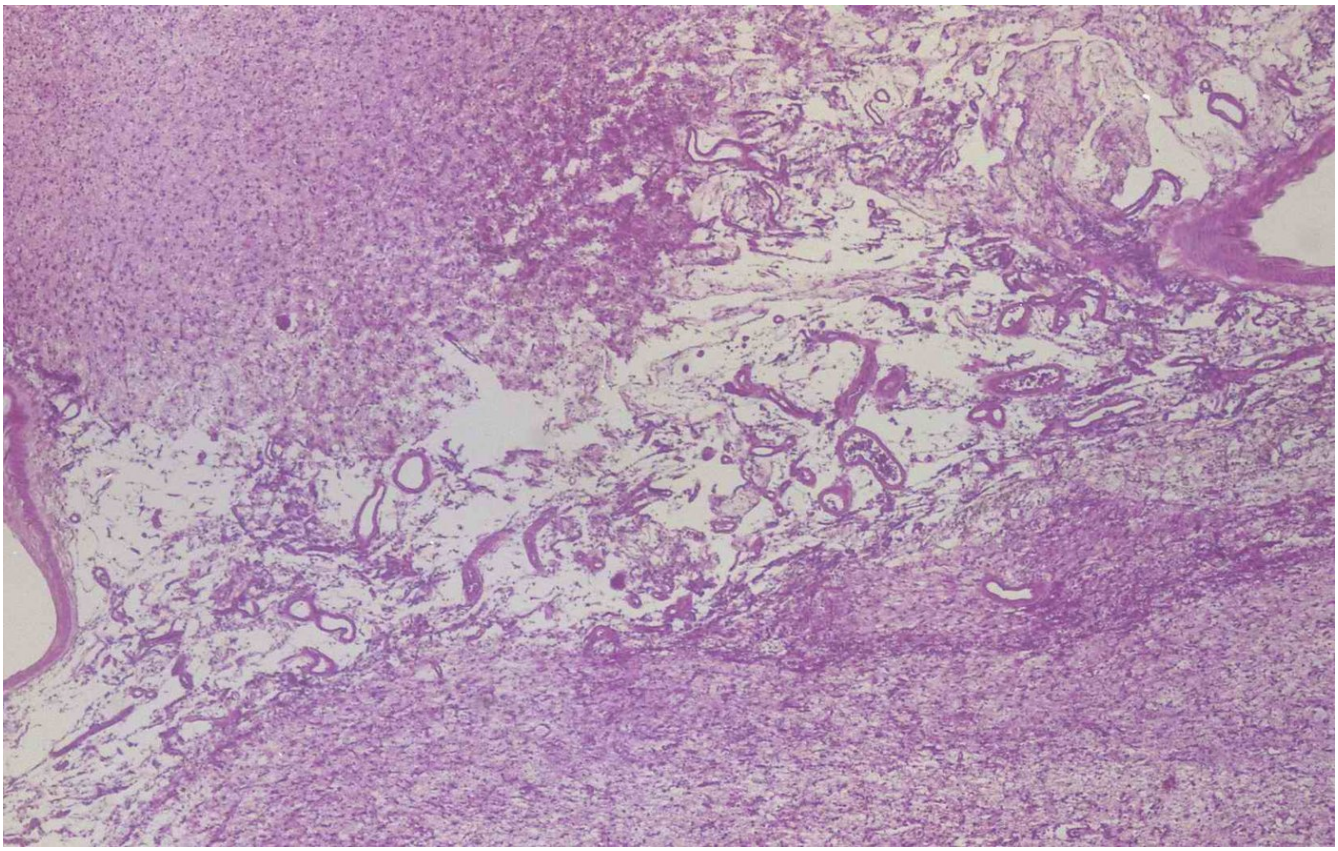

Figure 4. Relatively-old infarct area in the cerebrum from an individual (autopsy no.50947). Numerous small sized glial cells and capillaries exist in the cavity due to necrosis after infarction by HE stain and show no reactivity with these antibodies used in this study.

Materials and Methods

Human cerebral and cerebellum tissue specimens including relatively old or old- infarct lesion were obtained from 9 cadavers at autopsy in Department of Legal Medicine, Shiga University of Medical Science or in Osaka Medical examiner's Office. The summary of the cadavers is described in Table 1. Anti-CC, anti-CB, anti-PSA and anti-PGDS were used. All of antibodies against CC, CB, APS and PGD are produced in our laboratory.[12,13,14,15] Additionally anti-Le x antibody purchased from Dako Japan was used to detect astrocytes.[11] Immuno-staining was done according to our previous method.[11] In briefly the tissue specimens of the brain were fixed in 10% formalin, and serial paraffin sections (3 μm) were mounted onto slides. Deparaffinized sections were immersed in absolute methanol containing 0.3% H_2O_2 for 30 min at room temperature to block endogenous peroxidase. After washing in 0.01M PBS, the sections were incubated overnight at 4° C with anti-CC, anti-CB, anti-APS, anti-PGDS or anti-Lewis x diluted at 1:400,1:200, 1:400, 1:400 or 1:50 respectively. After washing in 0.01M PBS, the sections were incubated with biotin-conjugated anti-rabbit IgG or

anti-mouse IgG for 1 hr, washed and then treated with streptavidin-biotin-peroxidase complex (HISTOFINE SAB-PO kit, Nichirei, Tokyo) for 1 hr. 3-3diaminobenzidine was used as chromogen. We made a serial section for each tissue block. One section was stained by Hematoxylin Eosin (HE). Although some tissue sections were counterstained by Hematoxylin, others were observed without counterstaining.

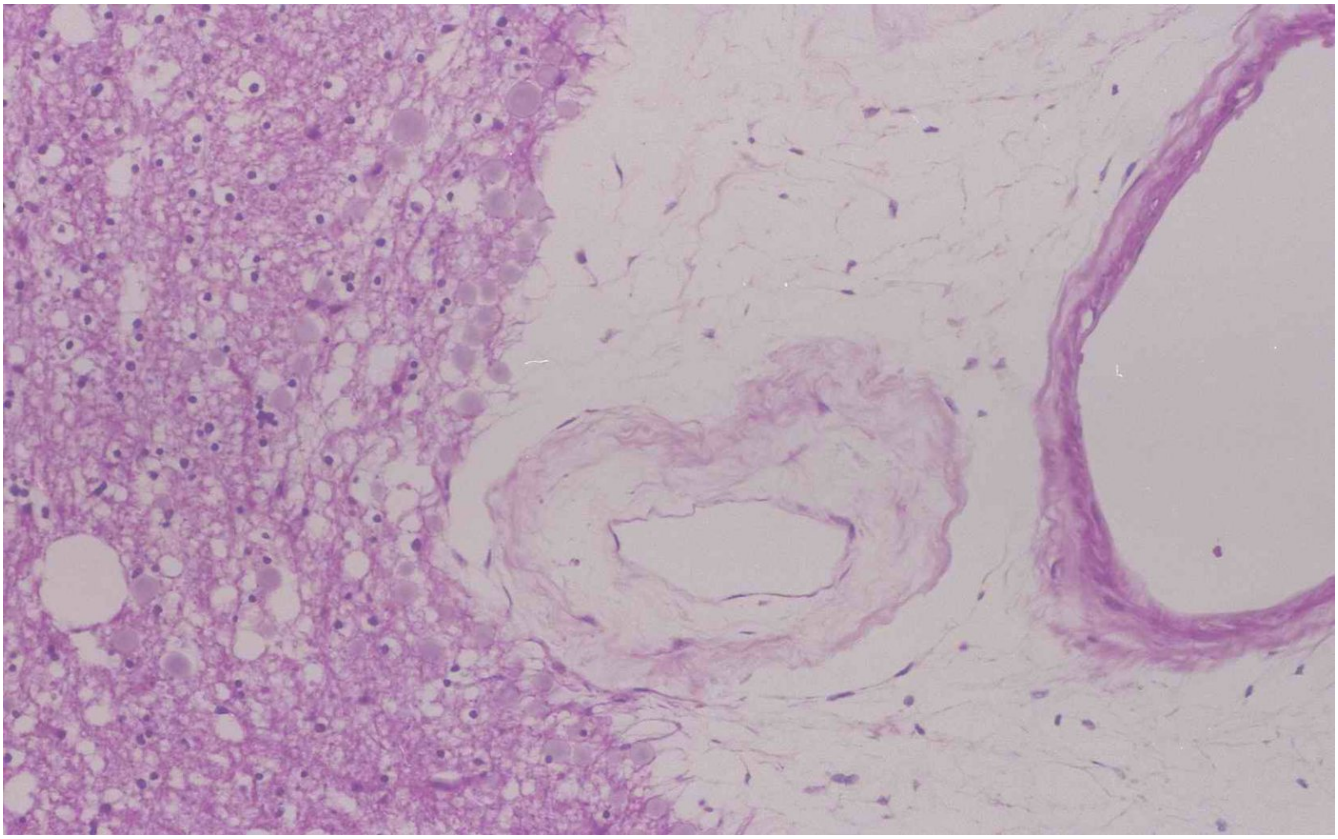

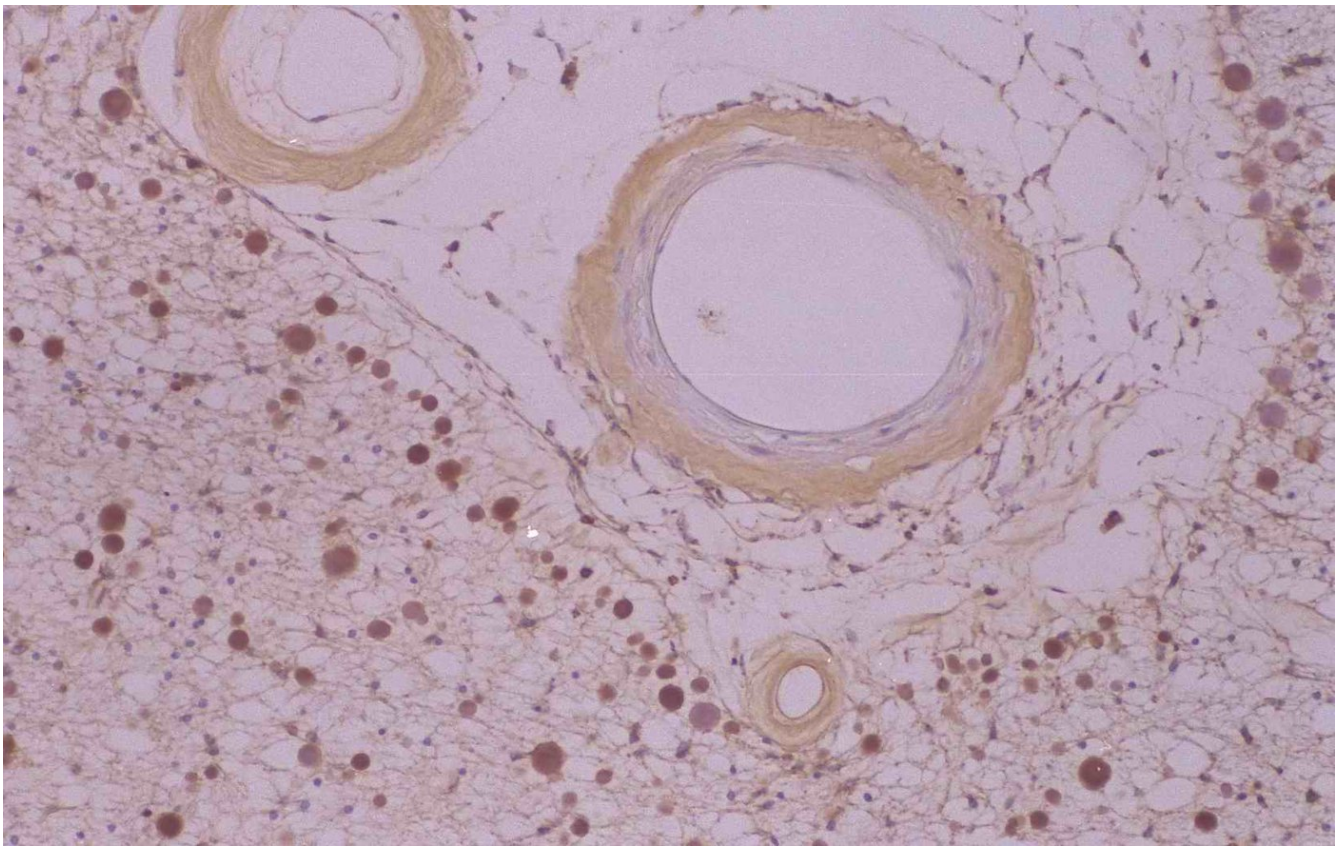

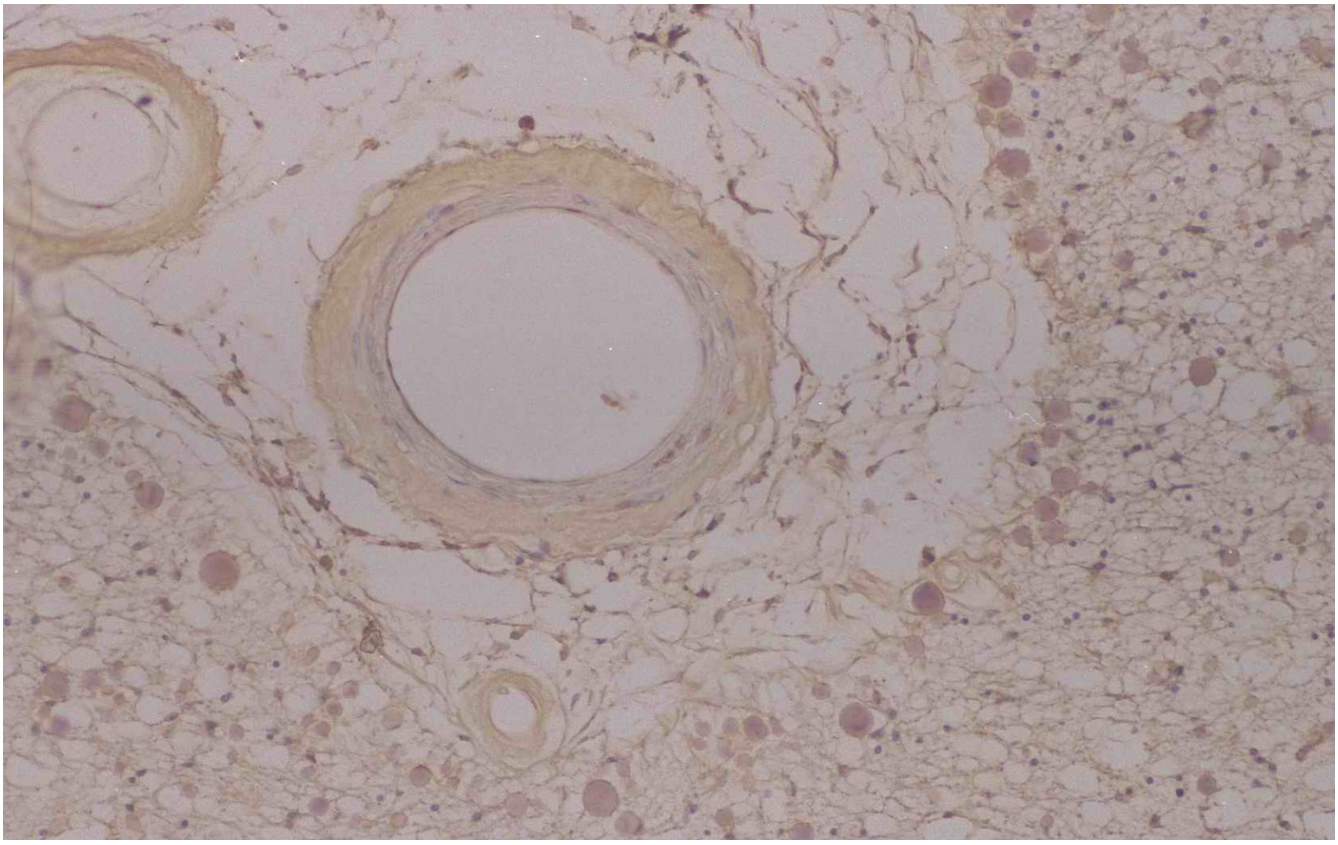



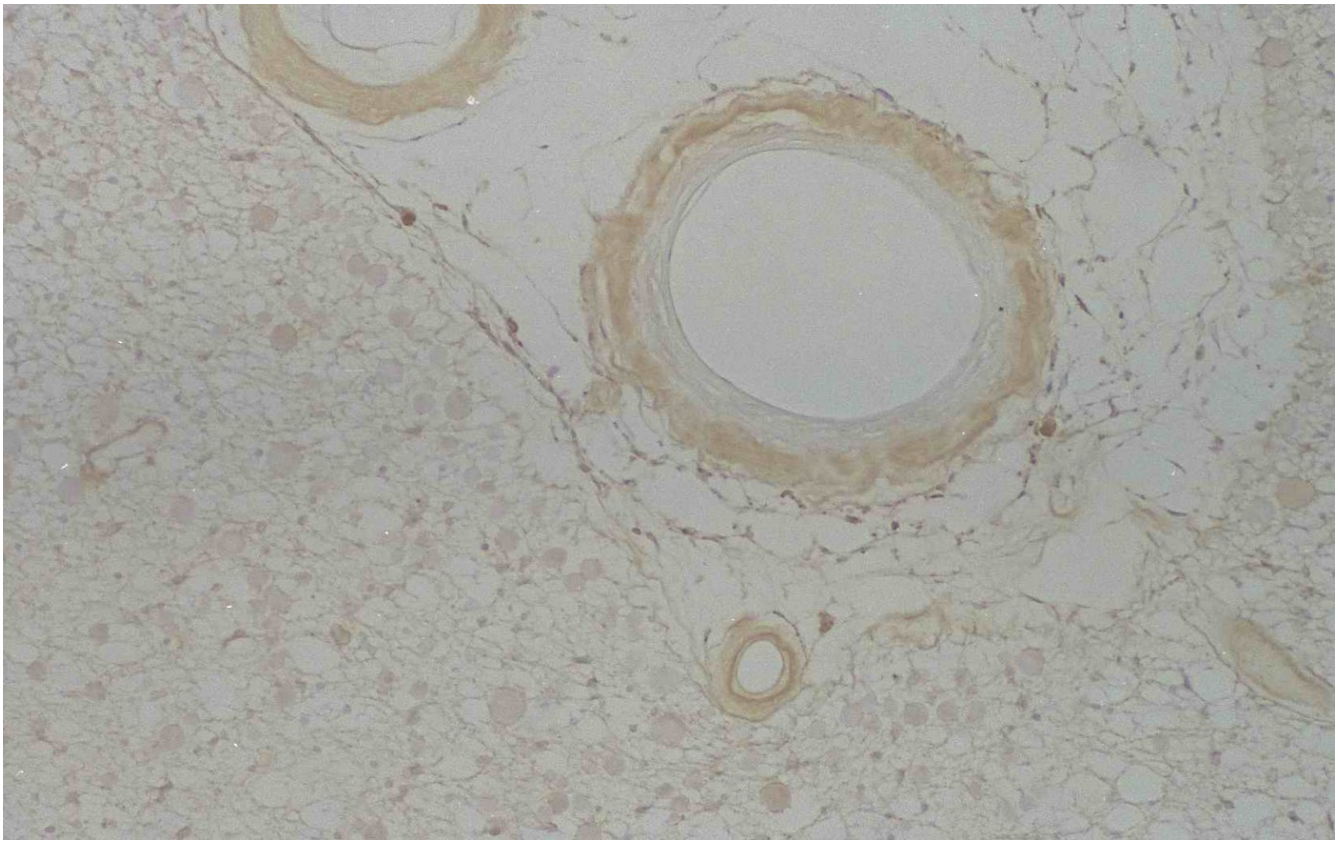

Figure 5. Immunostaining of corpora amylacea in the cerebrum from an individual (autopsy no. 50947). Many corpora amylacea are detected around a blood vessel that exist the surrounding the infracted cavity (5-A, top row left). The corpora amylacea show intensive reactivity with CB (5-B, top row right), weak with PSA (5-C, middle row left), feeble with CC (5-D, middle row right) and PGDS (5-E, bottom row).

Results

1. Old infarction in the cerebellum

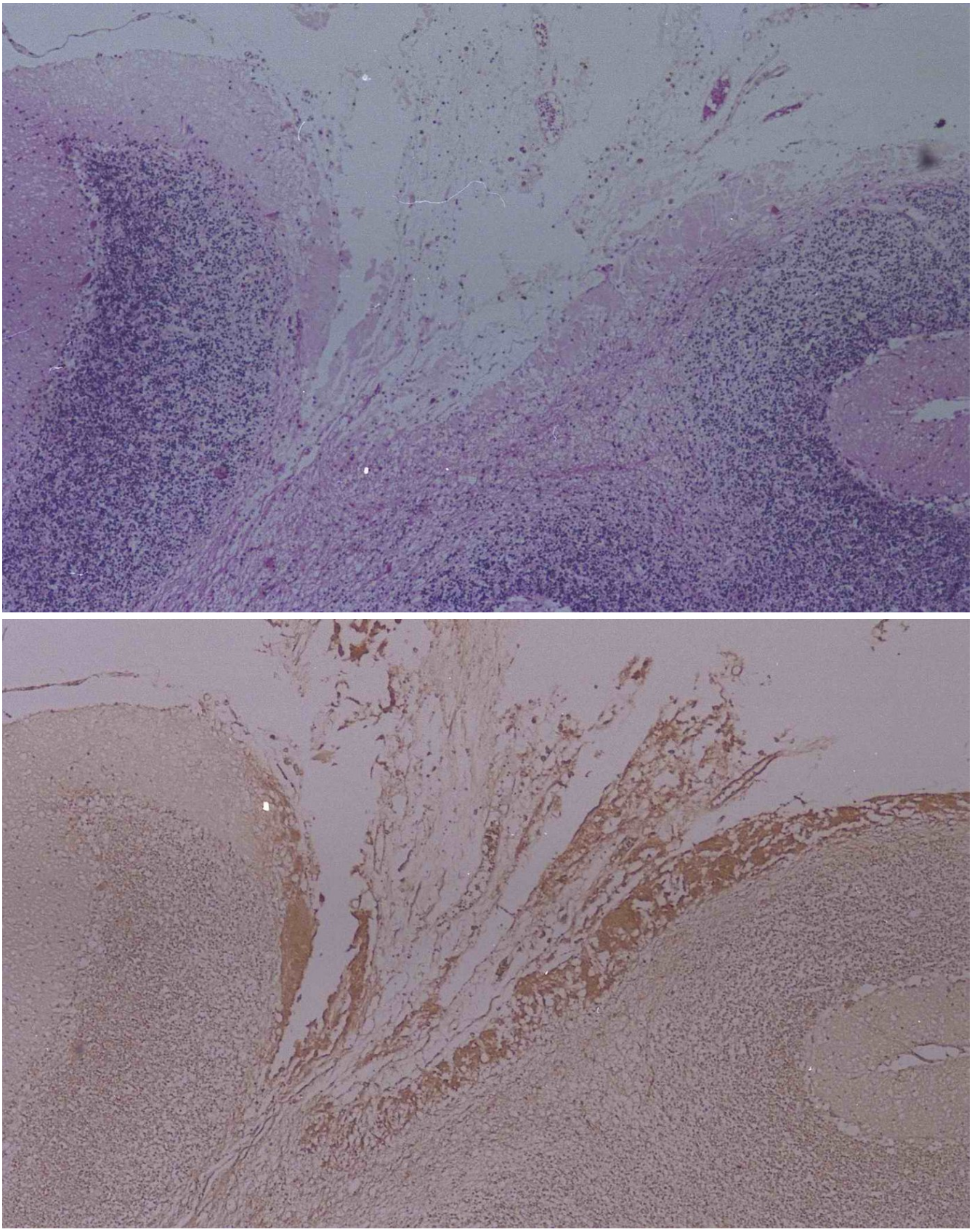

Figure 1. Old infarct area in the cerebellum from an individual (autopsy no.0636). Reticulation made by collagen-like fibers exist in the intact cortex by HE stain (1-A, top). Anti CC clearly stains the collagen-like fibers like as the meshes of a net (1-B, bottom). Although anti PSA weakly stained the collagen-like fibers, anti PGDS showed no reactivity with the collagen-like fibers.

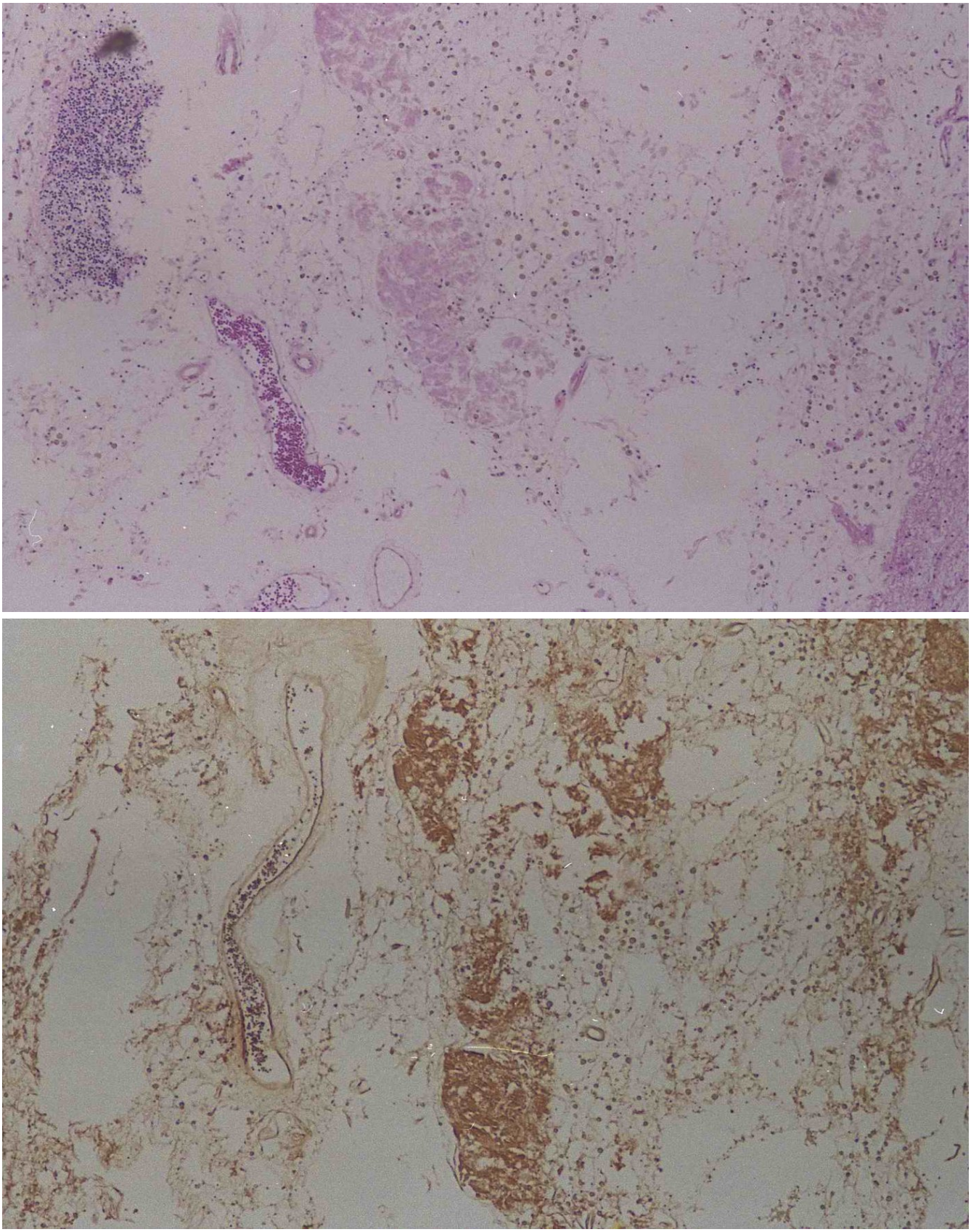

Figure 2. Old infarct area in the cerebellum from an individual (autopsy no.0636). Amorphous material without nucleus was recognized adjacent to the granular cell layer and the collagen-like fibers are found between the amorphous materials by HE stain (2-A, top). Anti CC clearly and intensively stains the amorphous material and collagen-like fibers (2-B, bottom). Although anti PSA weakly stained the amorphous material, anti CB and anti PGDS showed feeble reactivity.

In the cerebellum without pathological lesion, the Purkinje cells showed clear reactivity with anti-PGDS, weak or moderate with anti-CB and PSA, and from feeble to strong with anti- CC. Anti Le x showed no reactivity with the Purkinje cells and remarkable reactivity with granular cell layer. The reactivity of neuronal cells in the dentate nucleus of the cerebellum was varied in intensity, from clear with anti-PGDS and moderate with anti-CB and -CC to weak with anti-PSA.

The old infarct area in the cerebellum from a cadaver whose onset of infarction was 5 years before her death (autopsy no.0636), possessed three pathological changes that consisted a cave formation, a deposition of amorphous material with collagen-like fiber adjacent to the relatively intact cortex and reticulation made from collagen-like fiber, which was enclosed by the intact cortex, as shown in Fig.1-A.2- A and 3-A. The different kinds of pathological finding might indicate that three times onsets of infarction may be occurred in her cerebellum. The cave consisted primarily of a cavity with insular amorphous material, a few strands of collagen, numerous macrophage-like cells and small amount of haemosiderin-laden phagocytes cells. The scattered amorphous material was found like as islands at the periphery of non-affected cerebellum tissue and collagen-like fibers observed adjacent to non-infarct tissue. The amorphous material and collagen-like fiber were intensively stained by anti CC, and showed relatively weak reactivity with anti-CB and PSA. The staining results were shown in Fig.1 and 2. The macrophage-like cells spread in the cavity were weakly or feebly stained by anti CC and strongly stained by anti-CB and PSA, as shown in Fig.3. Anti-PGDS showed clear reactivity with the Purkinje cells and glia cells in the survived region, and macrophage-like cells in the infarcted region. The glia cells stained by anti-CC, CB, PSA and/or PGDS are remarkable in the surrounding of infracted area compared with normal region. Anti CC antibody could distinguish the necrotic area from intact tissue with intensive staining, showing in Fig.1.

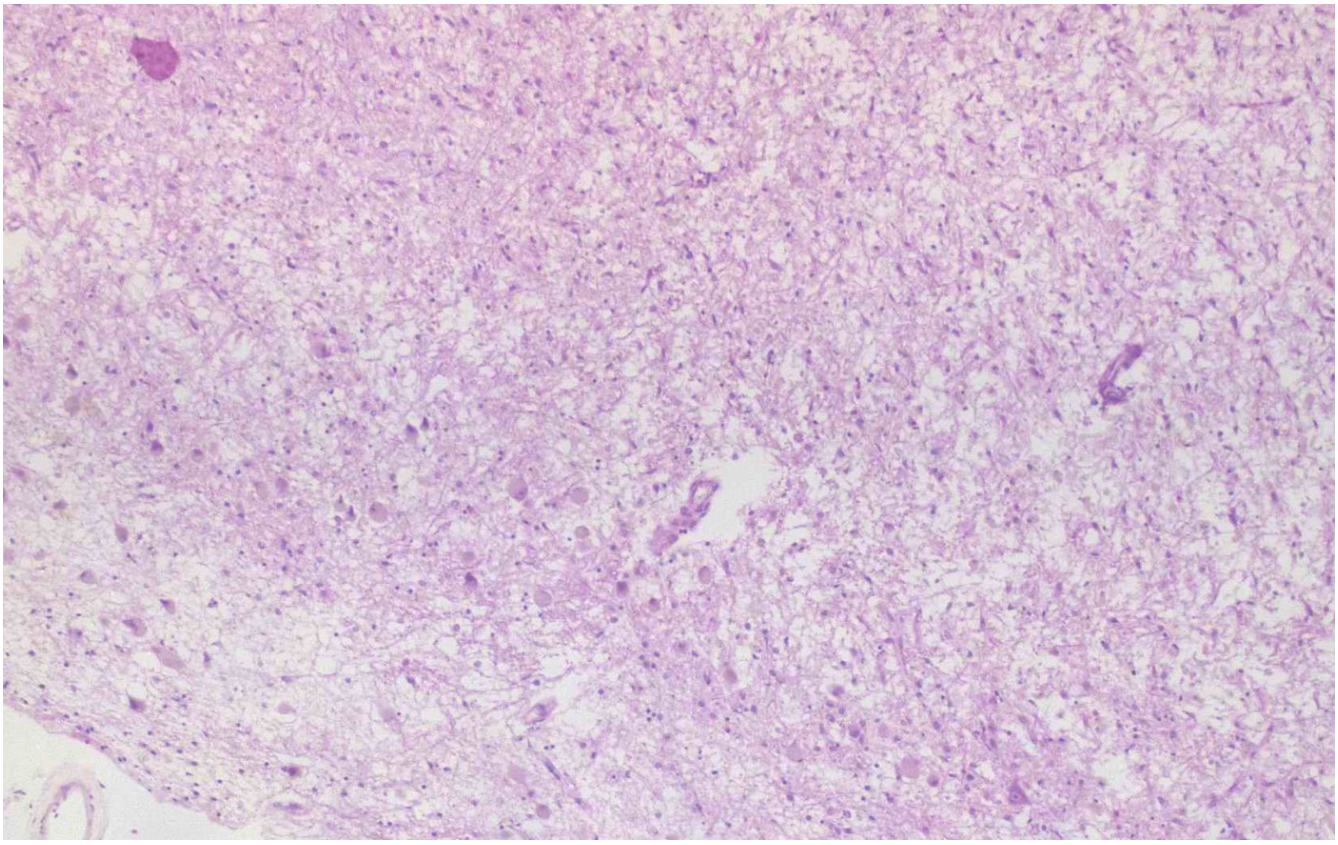



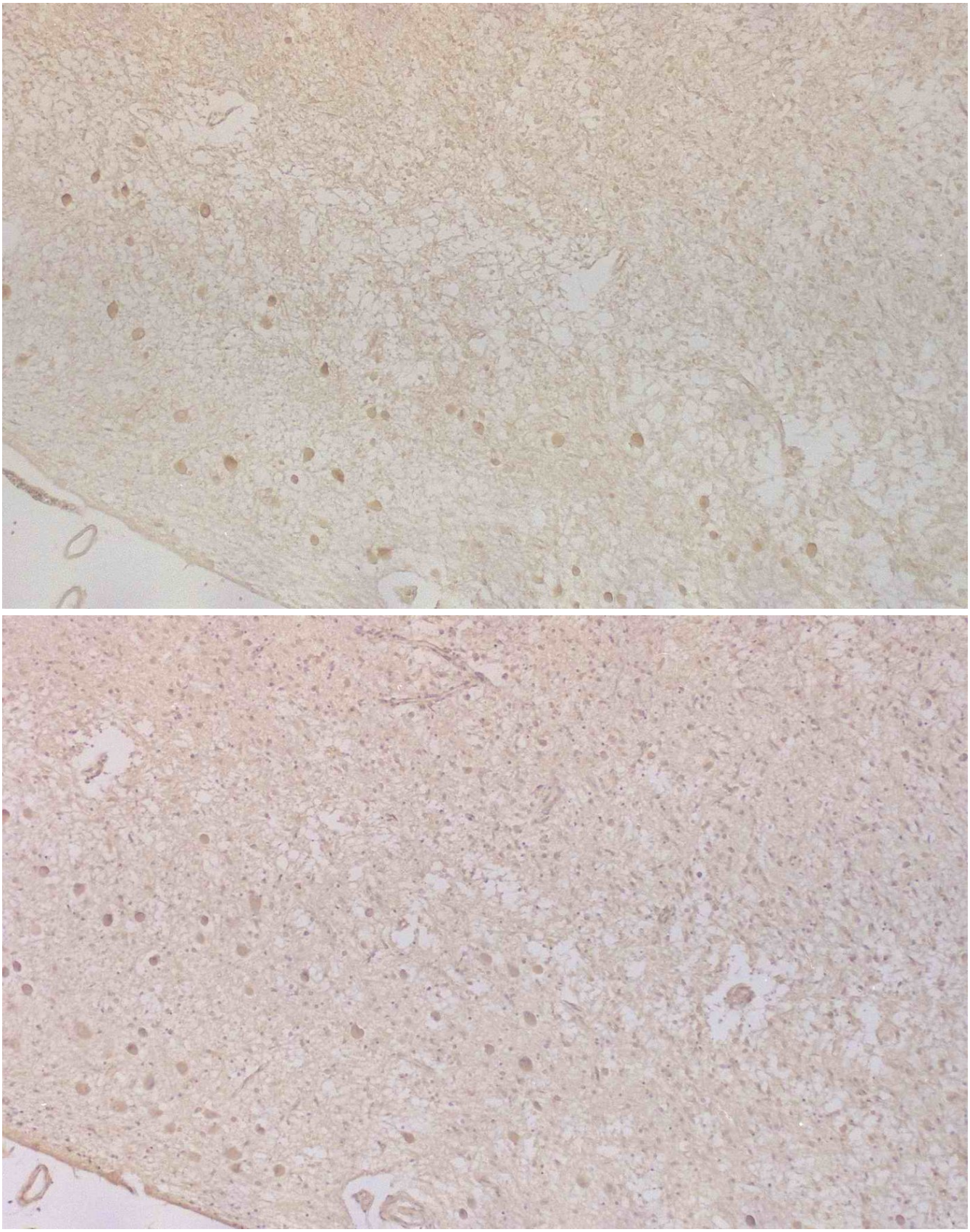

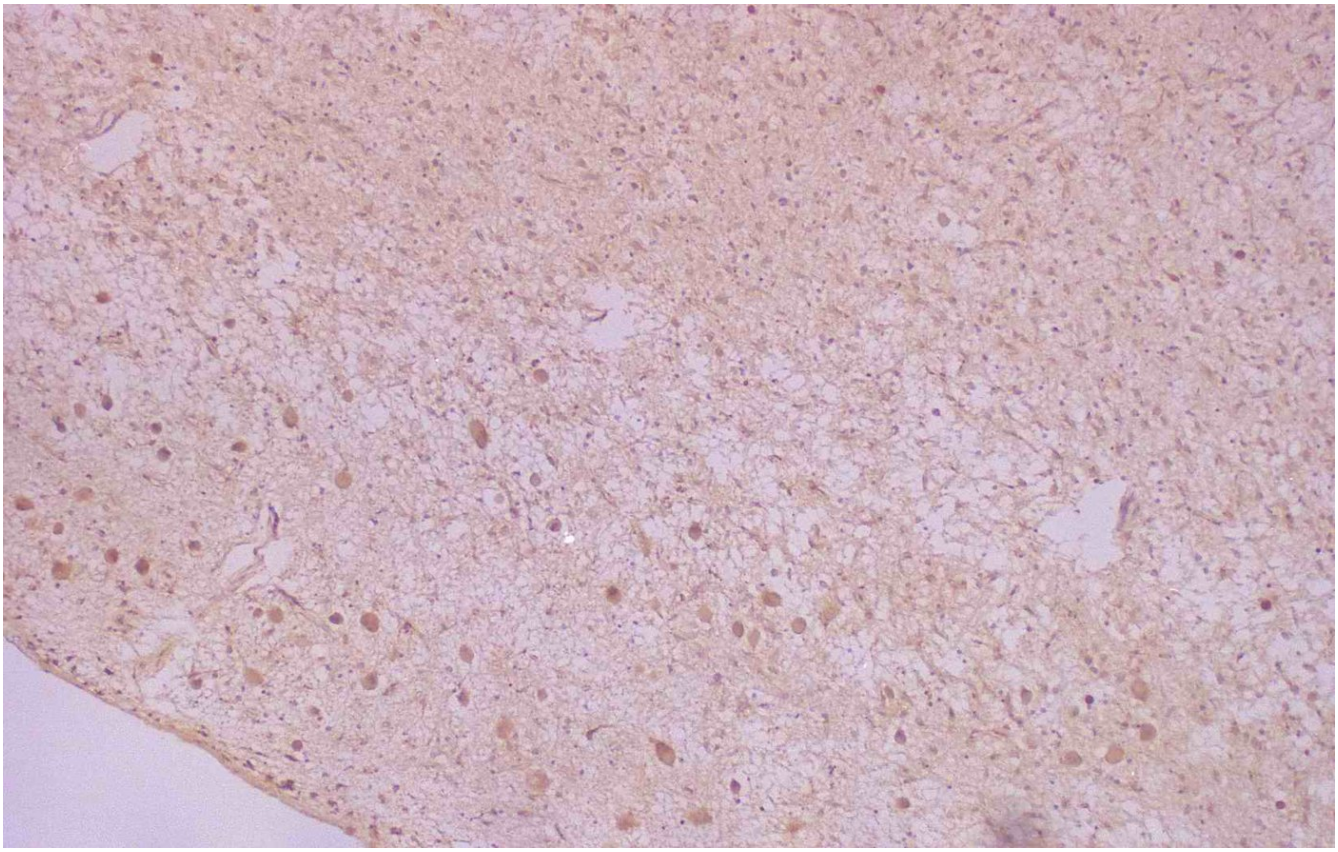

Figure 6. Relatively-old infarct area in the cerebrum from an individual (autopsy no.50947). Germistocytic astrocytes, large sized astrocytes, are detected in the cortex, peripheral area of the cavity, by HE stain (6-A). The astrocytes show relatively good reactivity with anti CC (6-B), CB (6-C), PGDS (6-D) and PSA (6-E), respectively.

2. Old infarction in the cerebrum

In the cerebral tissue without pathological lesion, glial cells showed clear reactivity with anti- CB, PSA and weak with anti-CC and PGDS, and neuronal cells showed feeble reactivity with them although anti-PGDS showed good reactivity with some neurons.

In the relatively old infarction from a patient who died 2 months after her onset of infarction (autopsy no.50947), the center of infarct area is replaced by a cavity with numerous of small sized glial cells and prominent capillary proliferation and without macrophages and amorphous material in HE stain. In the center of relatively old infarct area the small sized glial cells showed no reactivity with these antibodies. However, the number of larger sized glia cells stained by anti-CC, CB, PSA and PGDS was increased in the surrounding of infarct area compared with normal region. Additionally, in the area from surrounding to periphery of the infarction, numerous fibrous astrocytes and some germistocytic astrocytes showed intensive reactivity with these antibodies, respectively, as shown in Fig 5. The germistocytic astrocytes stained by anti-Le x antibody were appeared in the peripheral region of the infarction. The reactivity with antibodies and germistocytic astrocytes may be not false positive, since corpora amylacea showed intensive reactivity with CB, weak with CC and feeble with PSA and PGDS on the serial sections from an individual (Fig. 6).

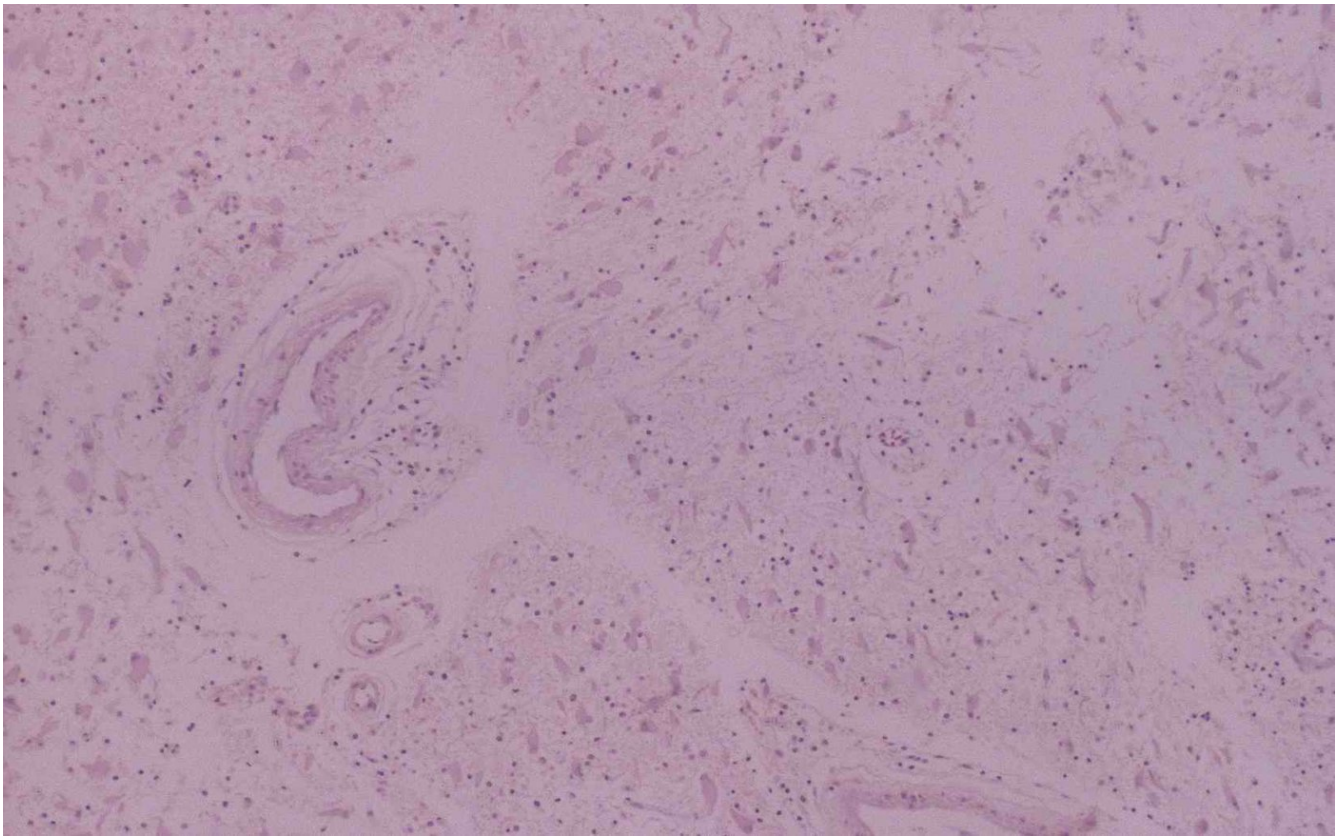

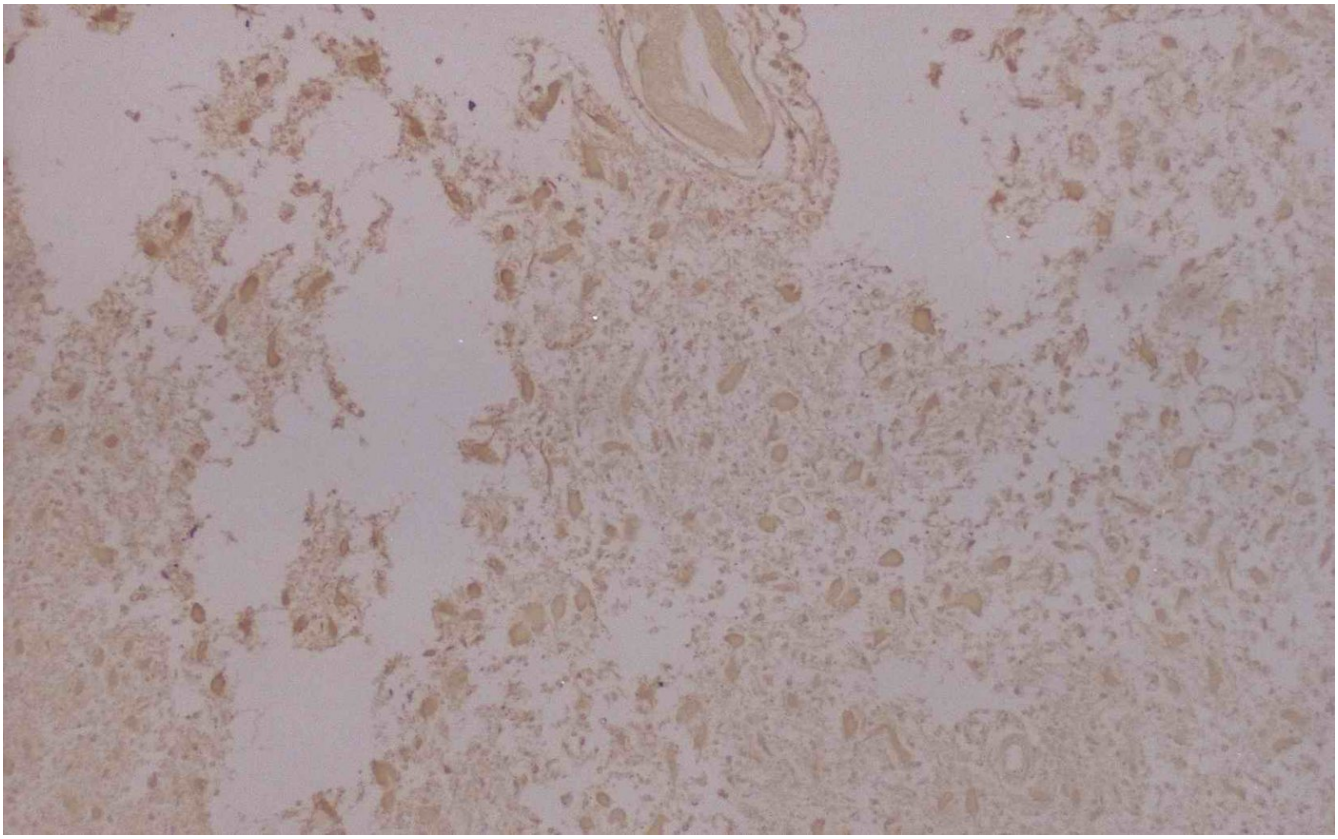

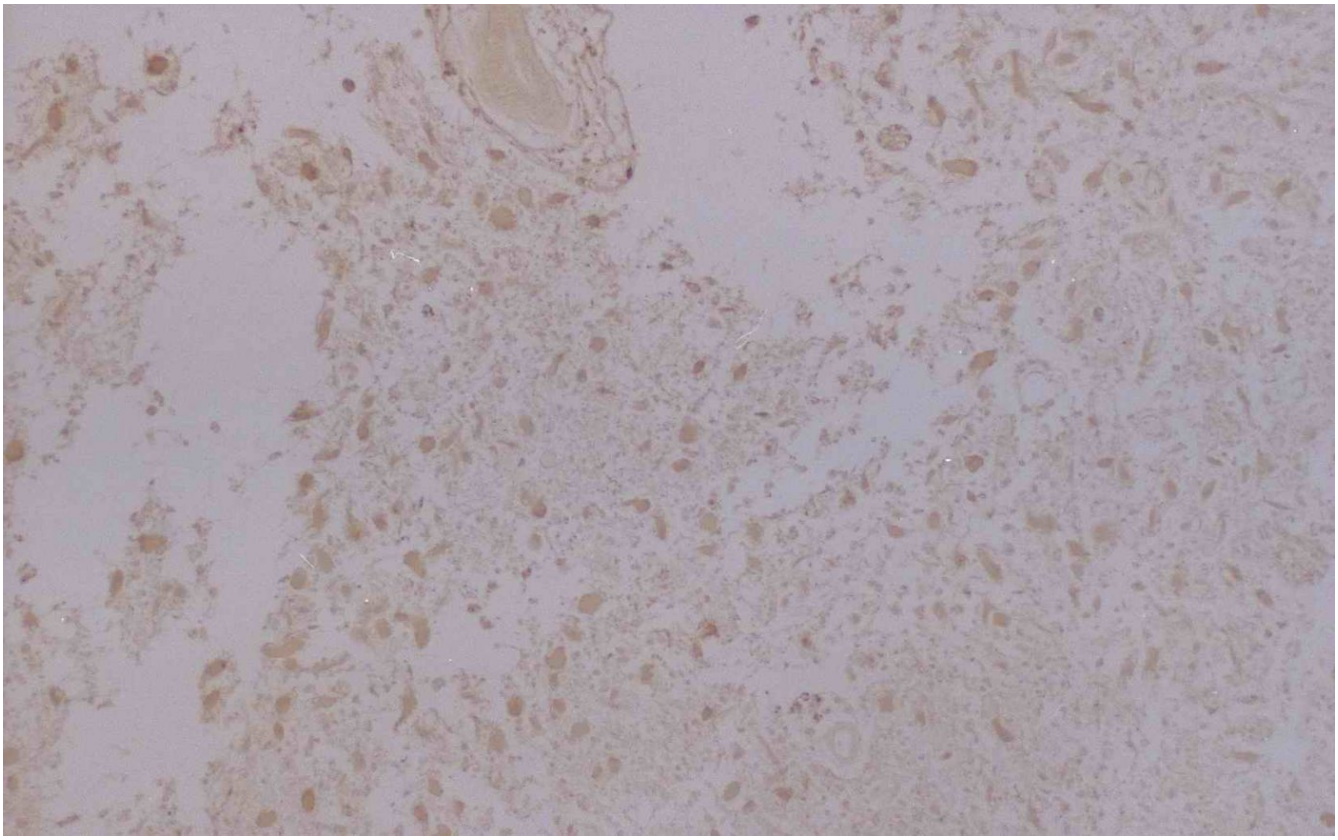

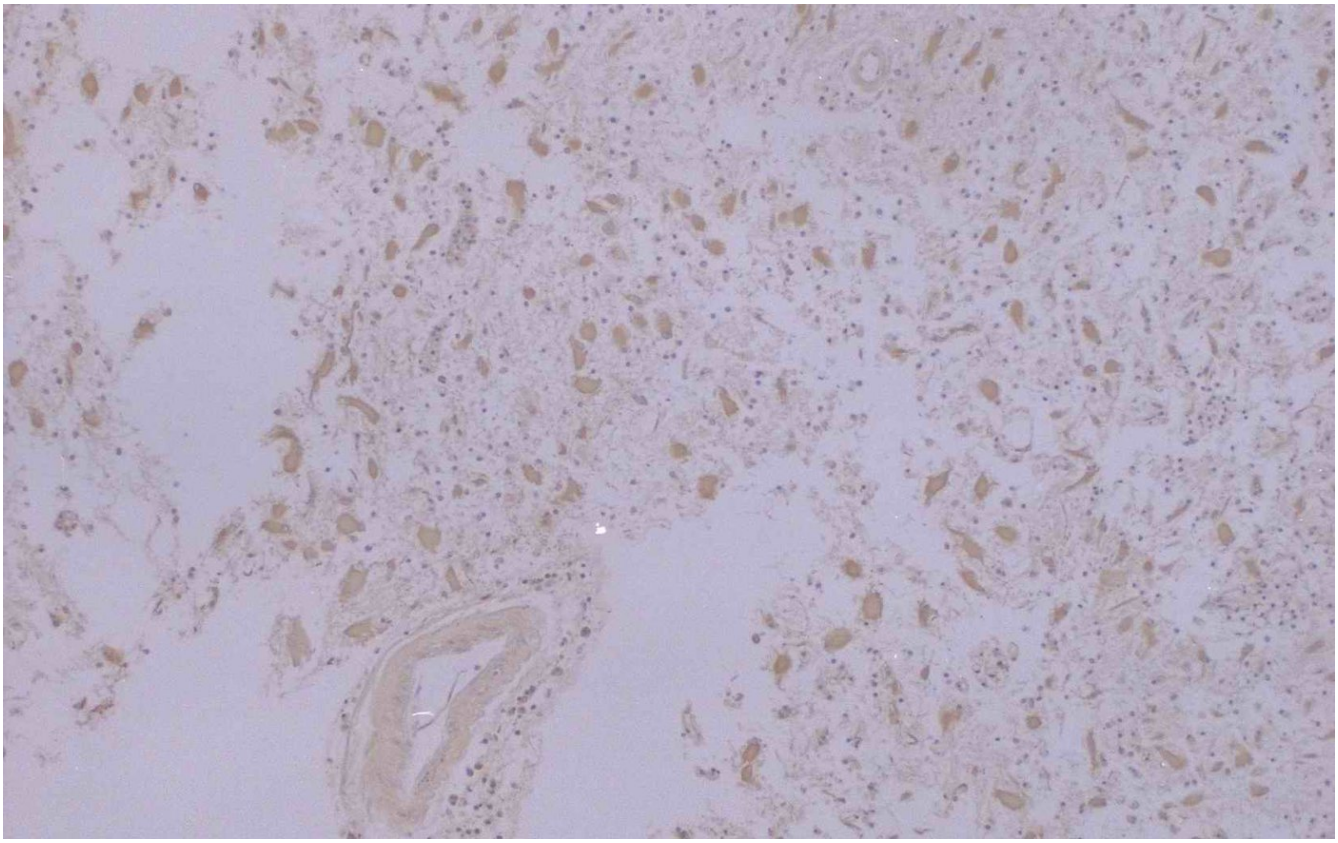

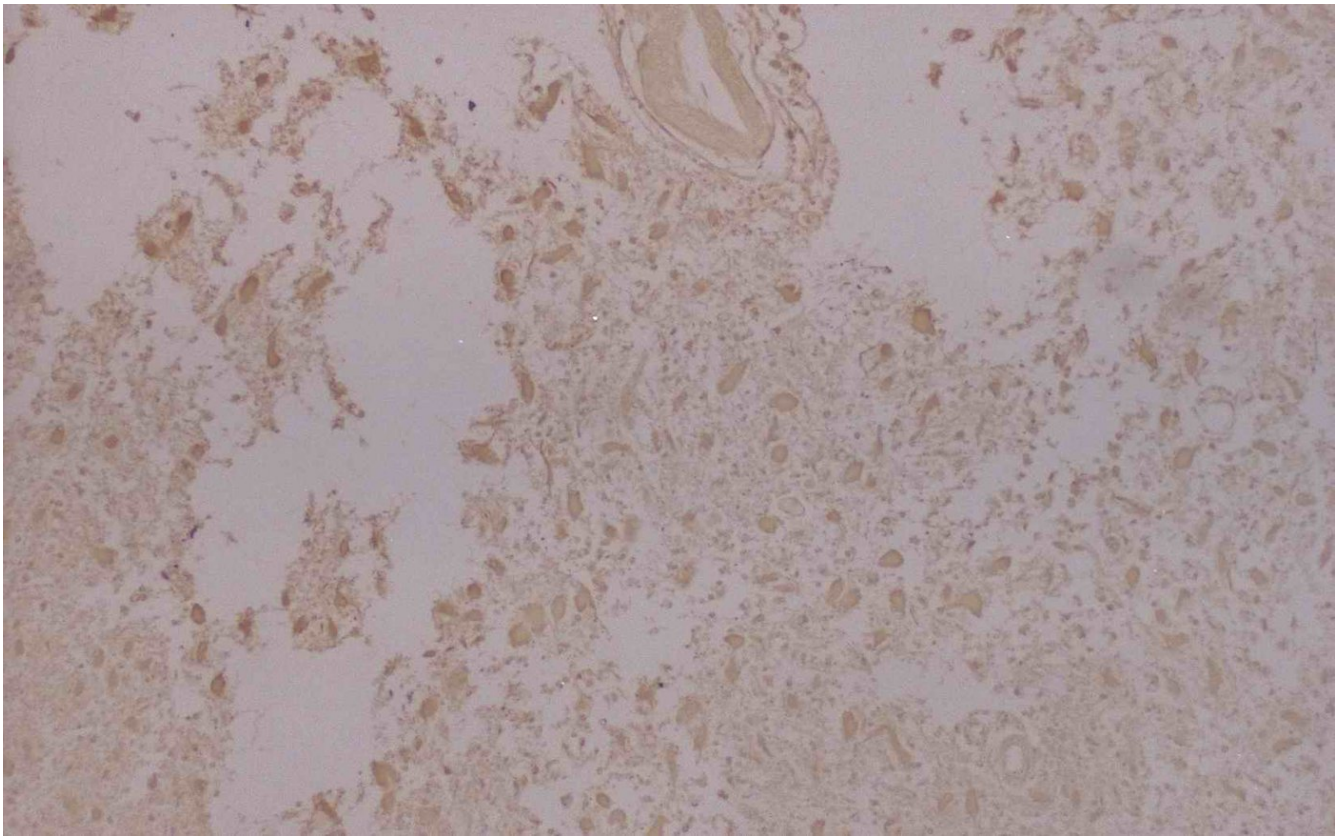

Figure 7. Old infract area of vassal ganglia from an individual (autopsy no. 0544). The germistocytic astrocytes detected in the center of the infarction by HE (7-A) are clearly and intensively stained by anti CC (7-B), CB (7-C) and PGDS (7-D), and weak by anti-PSA (7-E), respectively.

In old infarct area of the cerebrum from 69 year-old male who was in vegetative state and died due to asphyxia after 1-year onset of sudden episode of losing consciousness by unknown cause (autopsy no. 0544), the numerous germistocytic astrocytes in the center of the infracted area, many macrophages in the collagen-like fiber tissue and prominent capillary proliferation were detected by HE staining. Germistocytic astrocytes were stained clearly and intensively by anti-CC and CB antibodies, and anti PSA and PGDS showed moderate or weak reactivity with the germistocytic astrocytes. Anti CB and PGDS stained macrophage the clearly than those by anti PSA and CC staining. Staining results were shown in Fig.7 and 8.

Discussion

Although early ischemic episodes related to the role of CC and CB have been identified by many investigators, few reports have been made concerning those in old infract area.

In this study, CC and CB were predominantly expressed in the old infract area of human cerebrum and cerebellum, although the expression circumstances were different each other in the old infract tissues. CC was expressed mainly in the amorphous material that lacked the nucleus, and CB was mainly detected in soma of macrophages-like cells. The results obtained in this study indicate that CC and CB may inhibit or co-operate each other in the degenerative process of infarct brain tissue. CB is involved in various biological processes such as degradation of cellular proteins and regulation of enzymes, as well as in pathological processes.[5] CC is an inhibitor of cysteine protease such as cathepsin B,[1,2] and co-localized with amyloidßprotein in the brain of Alzheimer's disease patients.[16] Both CC and CB are expressed even in early stages of the damaged brain area after

ischemia. There are controversial reports concerning the roles of CC and CB in the ischemic brain lesion,[17,18] because CC has been presumed to protect the neuronal damage by CB in the infarct lesions, since CC inhibits the act of lysosomal cathepsin.[1]

What is already known on this topic

The cerebrospinal fluid contains several kinds of predominantly brain-derived proteins including cystatin C (CC), proteases such as cysteine proteases, and puromycin sensitive amino-peptidase, and prostaglandins D2 synthase (PGDS), which may be reflected by the pathological changes of the brain. Cystatin C is a potent endogenous inhibitor of the cysteine proteases, and involved in regulation of local inflammation and tumor invasion and metastasis. CC is up regulated in degenerated neurons in the hippocampal subregion CA1 after global ischemia in the rat suggesting a role in the neuronal death after cerebral ischemia. CC is produced by all nucleated cells, including neuroendcrine cells and cortical neurons. The prostaglandin D2 synthase (PGDS), produced in the choroid plexus and secreted into cerebrospinal fluid, is also detected in neurons of medulla oblongata and Purkinje cells in the cerebellum. The PGDS converts prostaglandin H into prostaglandin D2, and cyclooxygenase-2, a rate-limiting enzyme in prostaglandin synthesis because of production of prostaglandin H, mediates the induction of prostaglandin synthesis during the inflammatory response in vivo in many organs including brain.

What This study adds

In this study, the authors show that anti-CC antibody is a most useful tool to determine the necrotic region in the old-infracted brain lesion and indicated that CC, CB, PGDS and PSA were expressed in astrocytes or microglia cells surrounding the ischemic region, although their role might vary in the necrotic area.

In the old infarct area CC was mainly expressed in the amorphous material in the cerebellum and collagen-like fiber showing different expression site of CB that was mainly detected in macrophage-like cells. This indicates that CC and CB work independently in the old infarct area. We were not able to decide the constituent and origin of the amorphous material in this study. It may be of the material related to recovery of damaged brain tissue or of plugging the cavity, since the amorphous material is not detected in the relatively old infarct tissue and old infarct area in the cerebrum. The amorphous material might be peculiar to the cerebellum infarction or expressed only in the late stage of the process of infarction tissue in the brain, that is, expression depend on diurnal variations, since the amorphous material was detected only in the old infarction area of cerebellum in which the duration was 5 years from onset of the infarction.

PSA detected in the senile plaque in our previous study[10] may carry an important role in the destruction or protection of the damaged brain tissues.

Sairance et. al.[19] reported that Cox-2 protein was present in both neuronal and glial cells throughout the human brain in accord with infarct topography and duration of 15 hours to 18 days. In this study PGDS was also expressed both in fibrous and germistocytic astrocytes surrounding the center of the infract area, although PGDS was not recognized in the neurons of the infarct area. This may be obvious and naturally since Cox-2 produces prostaglandin H and PGDS converts the prostaglandin H into prostaglandin D2.[11]

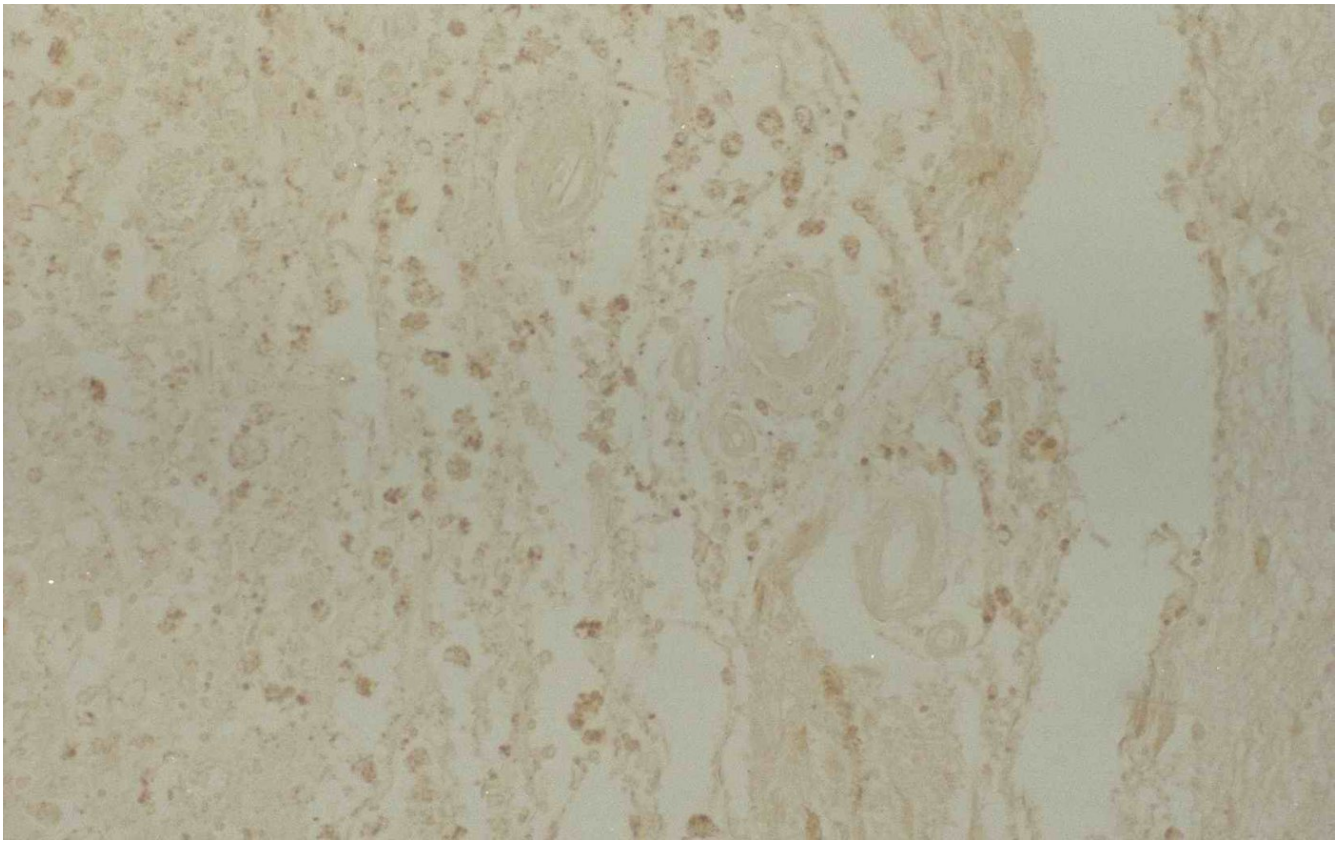

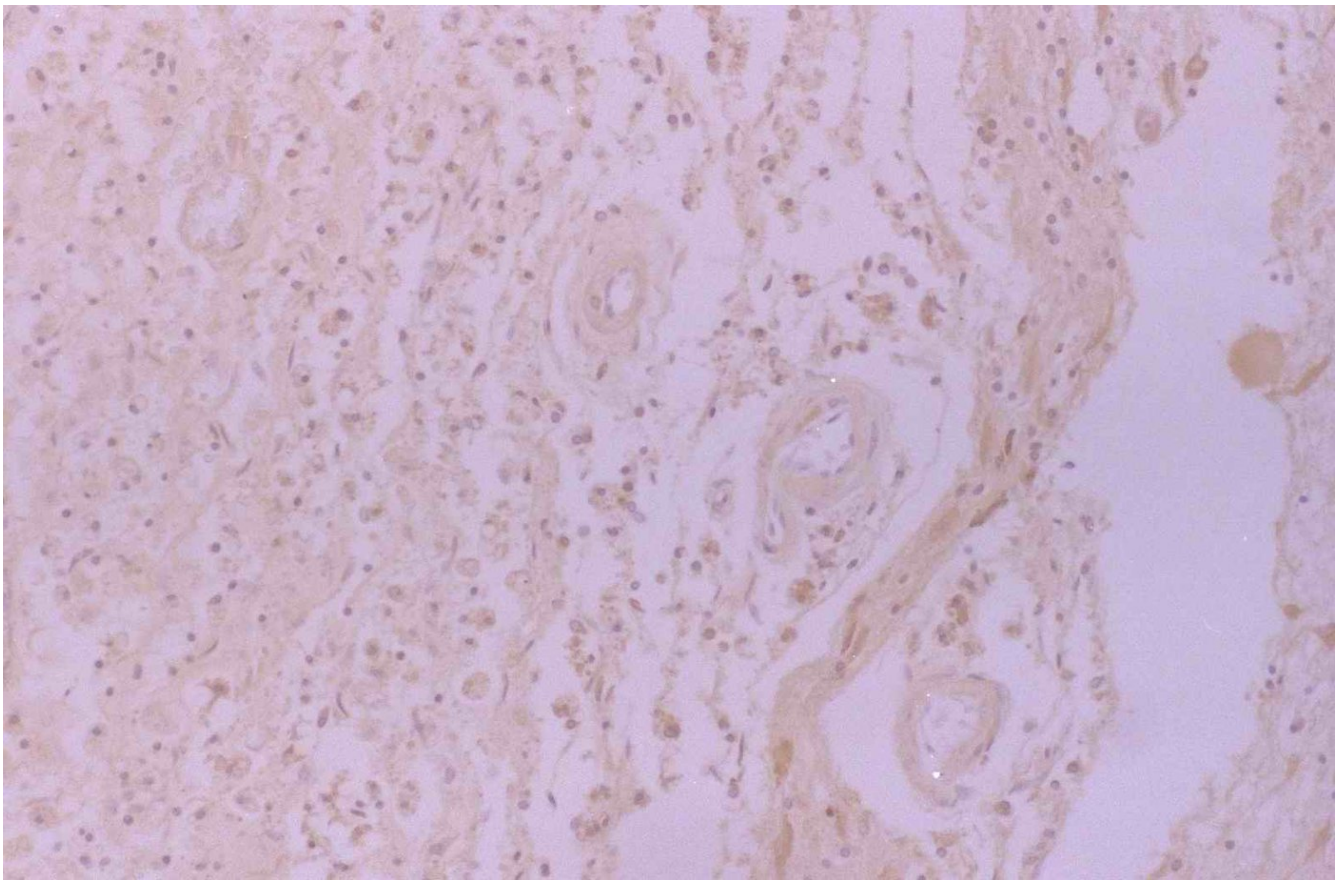

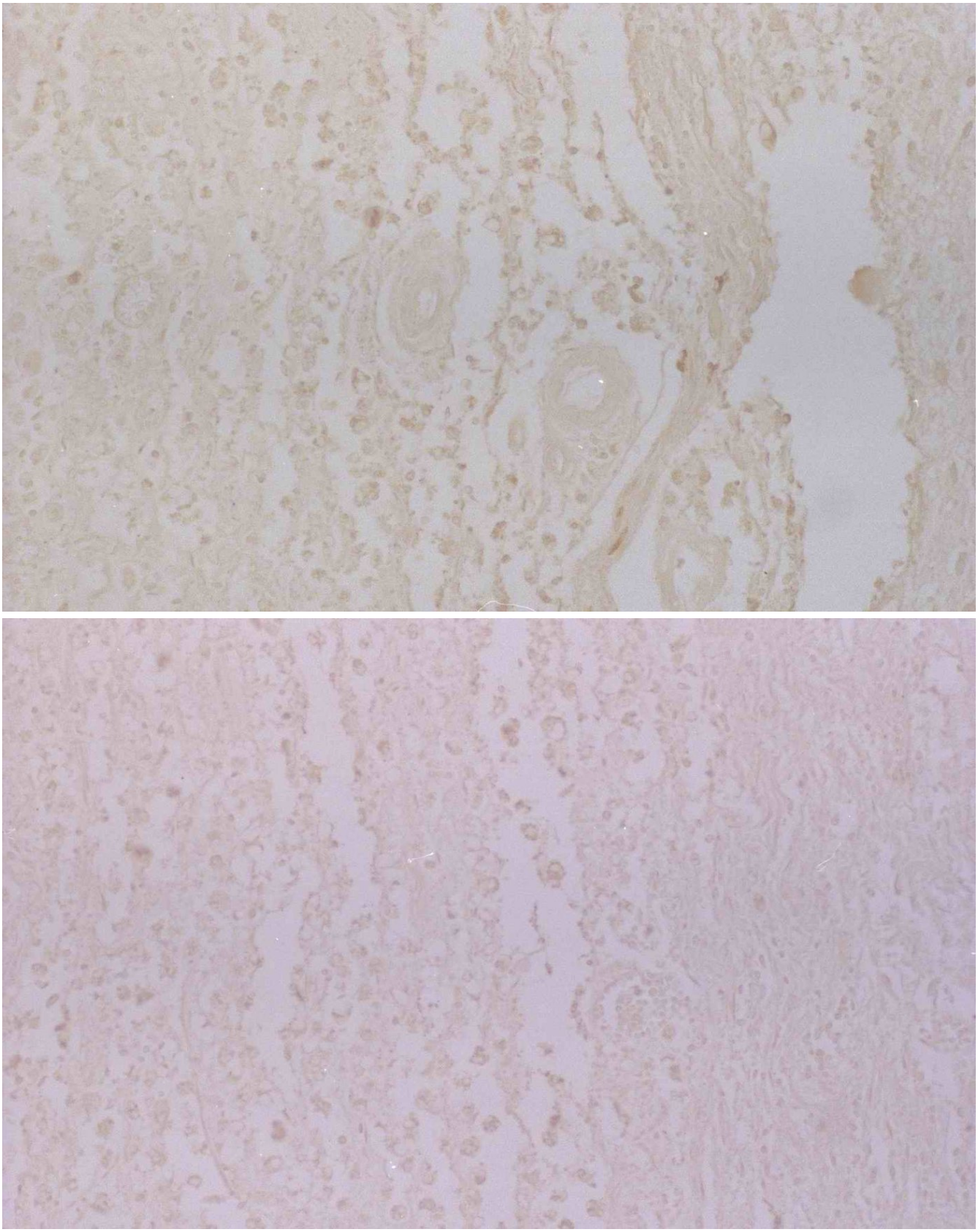

Figure 8. Old infract area of vassal ganglia from an individual (autopsy no. 0544). Macrophages were stained intensively by anti CB (8-A), moderately by anti-PGDS (8-B) and CC (8-C), and weakly by anti-PSA (8-D).

Conclusion

The results obtained in this study suggest that substances, such as protease (CB and PSA), protease inhibitor (CC) and PGDS, derived from cerebrospinal fluid are relevant each other to the degeneration process of necrotic brain tissue due to infarction, although true roles of these substances remain unclear, that is, whether they stimulate or protect degeneration of infarction tissue, and anti- CC is a useful tool to detect and decide the boundary of necrotic area in the old infarction of the brain.

Table 1. Summary of individuals with brain infarction.

Autopsy number	Age	Gender	Organ	Death after onset	Cause of death	Extent of Infarction
50880	77	M	cerebrum	Unknown	Cardiac death	Focal
50947	76	F	cerebrum	2 months	Cardiac death	Focal
50966	68	M	cerebrum		Brain contusion	Focal
0428	49	F	cerebrum	4 years	Hemorrhagic shock	Focal
0544	69	M	cerebrum	1 year	Asphyxia	Large(vegetative)
0636	81	F	cerebellum	5 years	Lung contusion	Focal
51500	52	M	cerebellum	unknown	Subdural hemorrhage	Focal
51550	49	M	cerebrum	unknown	AMI	Focal
0652	94	M	Cerebellum	unknown	Hemorrhagic shock	Focal

References

1. Leung-Tack, Tavera C, Gensac M.C, Martinez J, Colle A. Modulation of phagocytosis-associated respiratory burst by human cystatin c : role of the N-terminal tetrapeptide Lys-Prp-Pro-Arg. Exp Cell Res. 1990, 188; 16-22. PubMed (
2. Barrett A J, Fritz H, Grubb A, Isemura S, Jarvinen M, Katsunuma N, Machleid W, Muller-Esterl W, Sasaki M, Turk V., Nomenclature and classification of the protein homologous with the cysteine-proteinase inhibitor chicken cystatin. Biochem J.,1986 May 15;236(1):312. PubMed (
3. Palm DE, Knuckey NW, Primiano MJ, Spangenberger AG, Johason CE. Cystatin C, a protease inhibitor, in degenerating rat hippocampal neurons following transient forebrain ischemia.BrainRes.1995, 691, 1-8. PubMed (
4. Grubb A, Loefberg H., Human gamma-trace. Structure, function and clinical use of concentration measurements. Scand J Clin Lab Invest. Suppl 1985, 177; 7-13. PubMed (
5. Marks N, Berg MJ, Benuck M., Preferential action of rat brain cathepsin B as a peptidyl dipeptidase converting pro-opioid oligopeptides. Arch Biochem Biophys 1986, 249; 489-499. (
6. Taugner R, Buhrle CP, Nobiling R, Kirschke H., Coexistence of rennin and cathepsin B in epitheloid cell secretory granules. 1985, Histochemistry 83, 103-108 (

7. Yamashima T. Implication of cysteine proteases calpain, cathepsin and caspase in ischemic neuronal death of primates. Prog Neurobiol. 2000 Oct;62(3):273-95. PubMed (
8. Larrinaga G., Gil J., Meana J J., Ruiz F., Callado L F., Irazusta J., Aminopeptidase activity in the postmortem brain of human heroin addicts. Neurochem International. 2005, 46, 213-219. PubMed (
9. McDermott,JR., Mantle D., Lauffart B., Kidd AM., Purification and characterization of a neuropeptide-degrading aminopeptidase from human brain., J Neurochem. 1985, 45,752-9. PubMed (
10. Minnasch P., Yamamoto Y., Ohkubo I., Nishi K. Demonstration of puromycin-sensitive alanyl aminopeptidase in Alzheimer disease brain.. Leg Med (Tokyo) 5,Suppl s285-287, 2003. PubMed (
11. Kobayashi A., Takamure A., Takase I., Uemura C., Nakagawa T., Yamamoto Y., Yamasaki S., Morimoto A., Ikemoto K., Rand S, Spalthof H., Annuss B., Ohkubo I., Nishi K., Expression of prostaglandin D2 synthese in human cerebellum and medulla oblongata - An immunohistochemical examination. American J Biomedical Research. 1, 2006. [] (
12. Yamamoto Y., Li-H Y., Huang K., Ohkubo I., Nishi K., Isolation and characterization of an alanyl aminopeptidase from liver cytosol as a puromycin-sensitive enkephalin-degrading aminopeptidase. Biolo Chem., 379, 711-9, 1998. PubMed (
13. YamamotoY., Nakagawa T., Yamamoto A., Ohkubo I., Nishi K., Purification of prostaglandin D2 synthase from cerebrospinal fluid and its distribution in the organs. Jpn J Legal Med. 59,44, 2005. (in Japanese). (
14. Yamamoto Y., Nakaminami C., Nakagawa T., Yamamoto I., Tanegashima A., Ohkubo I., Nishi K., Purification of basophilic low molecule protein from human cerebrospinal fluid and its characteristics and distribution. Jpn J. Legal Med. 55, 57, 2004. (in Japanese). (
15. Ohkubo, I. Purification and characterization of cathepsin B from human brain. Forthcoming. (
16. Levy E., Sastre M., Kumar A., Gallo G., Piccardo P., Chetti F., Tagliavini F., Codeposition of cystatin C with amyloid-beta protein in the brain of Alzheimer's disease patients. J Neuropathol Exp Neurol, 60, 94-104, 2001. PubMed (
17. Olsson T., Nygren J., Hakansson K., Lundblad G., Grubb A., Smith ML., Wieloch T., Gene deletion of cystatin C aggravates brain damage following focal ischemia but mitigates the neuronal injury after global ischemia in the mouse. Nuroscience 128, 65-71, 2004. PubMed (
18. PalmDE., Knuckey NW., Primiano MJ., Spangenberger AG., Johanson CE., Cystatin C, a protease inhibitor, in degenerating rat hippocampal neurons of following transient forebrain ischemia. Brain Res, 691.1-8,1995. PubMed (
19. Sairanen T., Ristimaki A., Karjalainen-Lindsberg ML., Paetau A., Kaste M., Lindsberu PJ. Cyclooxygenase-2 is induced globally in infarcted human brain. Ann Neurol. 43, 738-47, 1998. PubMed (