ANIL AGGRAWAL'S
Internet Journal of Forensic Medicine and Toxicology
The world's first online journal devoted entirely to forensic medicine and toxicology · Published 1 January and 1 July

VOL. 6, NO. 1 · JANUARY – JUNE 2005
Downloaded from www.anilaggrawal.com · ISSN 0972-8074 (Online) · https://www.anilaggrawal.com/ij/vol_006_no_001/papers/paper001.html

Unusual Site of Snakebite: A Case Report

B. D. Gupta, O. Gambhir Singh

Professor & Head, Dept of Forensic Medicine, MP Shah Medical College, Jamnagar, Gujarat, India
Tutor, Dept of Forensic Medicine, MP Shah Medical College, Jamnagar, Gujarat, India
Contact: the corresponding author B. D. Gupta · bdgujn@yahoo.com

CITE THIS ARTICLE

Gupta BD, Singh OG. Unusual Site of Snakebite: A Case Report. *Anil Aggrawal's Internet Journal of Forensic Medicine and Toxicology* [serial online], 2005; Vol. 6, No. 1 (January – June 2005): []. Available from: https://www.anilaggrawal.com/ij/vol_006_no_001/papers/paper001.html

ABSTRACT

A case of snakebite is being presented in which the bite mark was located on the head of the victim. Bites over such sites could be missed easily while conducting postmortem examination. This paper highlights the importance of searching for fang marks from head to toe in alleged cases of snakebite. Hairy areas such as over the scalp should be shaved off and cleaned. The possibility of bite marks being present in unusual sites must always borne in mind.

Keywords: Snakebite, Fang marks

Medical Index Terms

Snakebite; Head; Victim; Autopsy; Edema; Ecchymosis; Scalp; Tissue Reaction; Rural Area; India; Human; Male; Case Report; Article

EMBASE Classifications

049 - Forensic Science Abstracts

The Case



Figure 1. Initial impressions - The doubtful site

On August 10, 2004, the body of a deceased male was sent for medicolegal postmortem examination with a history of snakebite, from a rural area near Jamnagar, Gujarat. On going through the inquest report it was learnt that the site of the alleged snakebite was somewhere on the back of the head. The incident had taken place earlier that day. On examining the body, there appeared to be no evidence of bitemark or any sort of injury externally. Since the head was covered with a thick growth of scalp hair, it was difficult to locate fang marks. There was no evidence of bleeding or swelling. Since there had been no eyewitnesses to the incident, it was thought that the information mentioned in the inquest report was speculative in nature. However, on the upper part of the back of the trunk in the midline there was a small discolored mark (Fig 1), which looked superficially like a bitemark, even though there was no evidence of vital reaction.

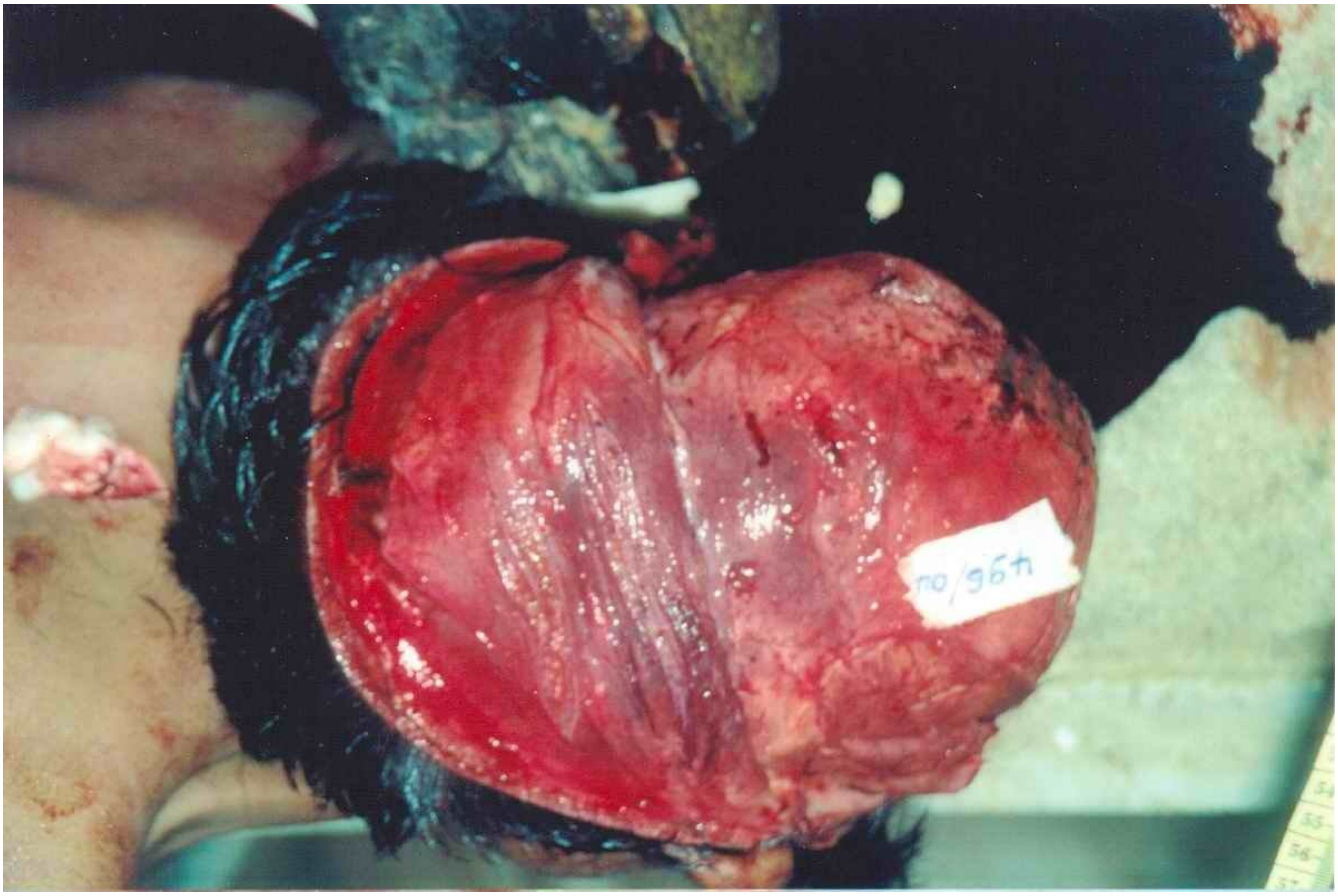

Figure 2. Ecchymosed and edematous scalp on reflection

On incising the scalp, there was evidence of ecchymosis and edema on the right inner aspect (Fig 2). This additional finding along with the information given by the police prompted us to re-examine the scalp externally. The suspected area was shaved, and to our surprise we located two clear-cut fang marks with their individually identifiable local tissue reaction (Fig 3).

Discussion

Snakebite is one of the common causes of death in rural and suburban areas of tropical countries such as India. About 52 different species of venomous snakes are encountered in India, and every year about 2 lakh cases of snakebite are reported, out of which 15,000 to 20,000 cases prove fatal[1,2].

The incidence of snakebite rises substantially in the monsoon season. The case being reported too occurred during this season. Conventional Indian textbooks do not discuss the common bitesites in great detail. Snakebite is not a common problem in the West, and hence discussion on snake envenomation is scarce even in Western books on toxicology. However, Wallace does mention common sites chosen by venomous snakes, and includes trunk and face as having been affected in a few cases[3].



Figure 3. Shaved scalp shows fang marks. Also seen is the doubtful site of snakebite of Fig 1 dissected. There is no evidence of vital reaction

Since many case of snakebite occur outdoors among farmers, it is understandable that a person while working in a field is more likely to get bitten on exposed or peripheral parts of the body. In one of the authors' own experience of over 27 years, this fact was very noticeable as almost all the cases of snakebite occurred on the limbs. This is also the basis for the precautions suggested to prevent snakebite, viz., the use of boots, thick trousers, and gloves to protect the limbs, while working outdoors[4].

In the present case, it was a mystery as to how the snake could access the head of the victim, until an examination of the scene of the incident, when the answer became apparent. We learnt that the victim was in the act of entering his hut when he was bitten. Fig 4 reveals that the hut was of a "*kuchha*" type (i.e., not made of cement or concrete), and had a big crater just above the door. It is likely that while entering his hut, the farmer may have disturbed the snake nestled in the crater, which then bit him on the head.



Figure 4. Hut of the deceased with crater over the door

Conclusion

This case is being reported here for two reasons;

1. The site of the bite is very unusual, and to our knowledge probably the first reported case in India.

2. Though the fang marks were two in number, they were so small and difficult to locate amidst thick scalp hair that they fit the description of concealed puncture wounds.

It is to be emphasized that if no bite marks are detected on exposed parts of the body in a case of alleged snakebite, it is advisable to look for them in uncommon sites also. It amounts to good practice if in every such case, hairy regions are examined closely, preferably after shaving the area.

References

1. Reddy KSN. The Essentials of Forensic Medicine and Toxicology. 22nd ed. Hyderabad: K Suguna Devi; 2003. p462.
2. Pillay VV. Comprehensive Medical Toxicology. Hyderabad: Paras Publishing; 2003. pp552, 60,69.
3. Polson CJ, Green MA, Lee MR, editors. Clinical Toxicology. 3rd ed. London: Pitman Books Limited; 1983. p584.
4. Wallace JF. Disorders caused by venoms, bites and stings. In Petersdorf RG, Adams RD, Braunwald E, Isselbacher KJ, Martin JB, Wilson JD, editors. Harrison's Principles of Internal Medicine. 10th ed. New York: McGraw Hill; 1983. p1242.