ANIL AGGRAWAL'S
Internet Journal of
Forensic Medicine and Toxicology
The world's first online journal devoted entirely to forensic medicine and toxicology · Published 1 January and 1 July

VOL. 5, NO. 2
Downloaded from www.anilaggrawal.com · ISSN 0972-8074 (Online) · https://www.anilaggrawal.com/ij/vol_005_no_002/reviews/tb/page001ex.html

Book Reviews: Technical Books Section

(Page 1 - Excerpts Section)

EXCERPTS

Neck Injuries, 1st Edition by S.M.A. Babar. Softcover, 246 x 170 mm.
Springer-Verlag, GmbH & Co.KG, Tiergartenstrasse 17, D-69121 Heidelberg, Germany. Publication date: 1999; 107 Illustrations. xiv + 142 pages, ISBN 1-85233-637-4. Price £49.50

Click cover to buy from Amazon



This book is an excellent attempt to present the vast topic of neck injuries in a compact and handy manner. ...", so conclude our expert reviewers. It indeed is. Full of references at the end of each chapter, the book would be sheer delight to researchers desirous of delving deeper into this fascinating area.

The board of editors decided to run some excerpts from this book, so the readers could get some idea, what this book contains. One of the most interesting (and informative) chapters in this book is

the one on injuries to the cervical spine and the spinal cord. Many interesting eponyms such as *Jefferson's fracture*, *Hangman's fracture* and *Clay shoveller's fracture* (also sometimes known as *Coal shoveler's fracture*) appear in this chapter. This is what Babar writes in this chapter (chapter 26; pages 99-101)...

Blunt injuries to the neck can cause vertebral disruptions resulting in damage to spinal cord. Such cord damage can range from minor bruising to transection. Therefore, symptomatology may range between neurogenic shock and paralysis. Ordinarily, the degree of violence has to be considerable, to injure the spinal cord but when the neck is unguarded (under anaesthesia, car accidents, whiplash injuries, etc.), seemingly trivial forces can disrupt the spinal cord!

Click here to read review of this book by Avneesh Gupta and Puneet Setia

---

Most such injuries occur in young people (males more often than females; average age of 25 years) and involve aggressive activities such as sport injuries, car accidents, falls and assaults.

A rough universal annual estimate of 10,000 new cases of acute spinal cord injuries is reasonable. Isolated cervical spine injuries are however uncommon. They usually occur nowadays, with road traffic accidents (RTAs), and head and limbs are often concomitantly involved. Although isolated spinal injuries are rare, their presence warrants a very aggressive early management, if major disability or loss of life is to avoided.

View this book on Amazon

Any cervical vertebra can be injured with violence. Interesting eponyms have been historically allocated to peculiar vertebral injuries.

"Jefferson's fracture" is a bilateral bursting fracture (Bursting fracture is any fracture that disperses multiple bone fragments, usually at or near the end of a bone - Mosby's Medical Dictionary) of anterior and posterior arches of C1 against the occipital condyles. An axial loading from the top of the skull can produce such an injury. The "hangman's fracture", encountered in judicial hanging and hyperextension injury, relates to fracture of the pedicles of C2 with subluxation (incomplete dislocation; a general hypermobility of a joint with actual displacement of the parts) of C2 on C3, resulting in spinal shock, transection or avulsion of the cord. Traditionally, a 1-2 metre drop with a noose around the neck results in an initial spinal shock and death from strangulation and asphyxia. A drop of more than 2 metres, almost always snaps vertebrae (most commonly the C2) resulting in cord avulsion. "Clay shoveller's fracture" is a form of fatigue fracture of spinous processes of lower cervical vertebrae (below C3) caused by direct trauma or muscular exertion in labourers.

In rheumatoid arthritis the apposed facets are fused due to spondylosis, ageing or demineralisation, and repeated stress during shovelling and so on, snaps up the facets or the pedicles producing a small fracture difficult to

identify with conventional views of X-rays of the cervical spine. MRI scans are more reliable for diagnosis.

Mechanism of Whiplash injuries. This figure appears on page 100 of this book

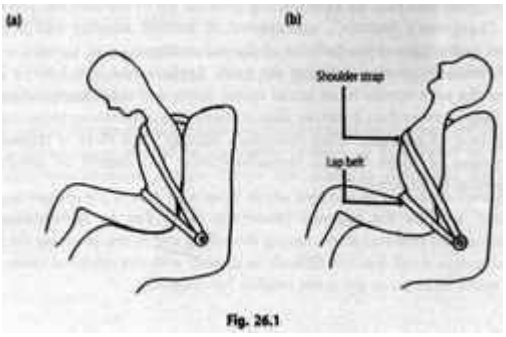

Odontoid fracture can occur from falls, blows to the skull, road accidents and sport injuries. These are divided into three types:

- *Type 1 is a fracture through the tip of the odontoid process.*
- *Type 2 is a fracture through the body of the process.*
- *Type 3 is a fracture through the base and the body of C2·*

Shallow water diving injuries can result in severe hyperflexion and dislocation of cervical spine at any level.

RTA deceleration can produce a whiplashing injury of the neck at various levels. As the car suddenly comes to a stop in an accident, the body continues to move forward. This deceleration is prevented by the activated inertia seat-belt that locks the shoulder strap and the lap belt. However, the restraining effects of the safety belt are confined to the trunk and to the pelvis. The neck continues to decelerate forwards in its upper part. Acute cervical flexion with stretching, is thus transiently produced (Fig. 26.l a). This is followed suddenly by the recoiling of the neck backwards by the protective reflexes, like the lash of a whip! (Fig. 26.l b).

A head rest can go a long way in preventing Whiplash injuries. This figure appears on page 101 of this book

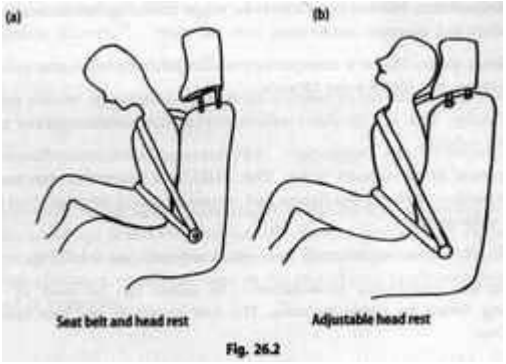

The force of the whiplash maneuver can transmit severe pressure to the atlantoaxial ligaments (the reflex recoil sends the head backward on a fixed thorax). The result may be a fracture of the odontoid process of the C2 with dislocation, resulting in crushing of the spinal cord. A whiplash is a

biphasic injury, when opposing forces work against each other. This is not merely a hyperextension injury of the cervical spine. The introduction of a fixed or adjustable headrest has prevented many injuries. Reflex hyperextension is prevented by the headrest during the whiplashing (Fig. 26.2).

Modern cars are fitted with air-bag systems for driver and front-seat passenger and these have dramatically reduced the incidence of whiplash injuries. Soon, "smart" air-bags which adjust to body size for children and to force of impact, are expected to be installed routinely.

Diving injuries or accidental falls on the head can result in the impaction of cervical spinal cord on itself. The lower cord can be directly crushed or the fractured pieces of bones can impale the cord from above, resulting in transection.

…Penetrating injuries of the cervical spinal cord are almost always caused by a high velocity missile. The bullet can track through to the pedicles or to the disc space. The secondary missile effect of the fragmented bone and dense tissue can easily cause an injury to the cord, possibly some distance away from the track itself. This is the main mechanism of the bullet injuries to the cord…

Penetrating injuries of the cervical spinal cord are almost always caused by a high velocity missile (rifle bullet from 10-20 metres or a pistol bullet from a closer range). The bullet can track through to the pedicles or to the disc space. The secondary missile effect of the fragmented bone and dense tissue (disc, ligaments) can easily cause an injury to the cord, possibly some distance away from the track itself. This is the main mechanism of the bullet injuries to the cord. The blast and the shockwave effects do not contribute much by way of cord damage. Cavitation effect also does not seem to cause much damage to the cord itself. Occasionally a bullet entering the neck from an anterolateral direction can ricochet against the transverse processes or pedicles and can come to rest against the spinal cord in the spinal canal, causing local compression to the cord at that level. An urgent decompression must be done with removal of bullet to salvage the cord.

The force of shotgun pellets is much too small to penetrate to the depth of the spinal cord but close range injuries (less than 5 metres) can cause destruction of the cord by a few pellets. This is almost always fatal.

Blast and explosion injuries tend to produce relatively greater damage to the middle and to the internal ear, Eustachian tubes and to hollow viscera, but spinal cord injury has also been reported. Much more numerous are shrapnel neck injuries, encountered with bomb explosions, resulting in penetrating injuries to the spinal cord.

When initial cervical spine injury occurs, some of the damage is probably reversible. It is this aspect which is often made worse with mishandling and

with bad transport. Transportation should be conducted in an organized way to minimize such injuries and to preserve intact tissue.

Babar then goes on to describe other injuries. I can not but end this section without mentioning that I always believed that *Clay Shovellers' fracture* is the fracture of the spinous process of the 7th Cervical or 1st dorsal vertebrae in the act of shovelling. I have a *Butterworth's medical dictionary*, and I checked up with this, and this is indeed the definition that the dictionary gives. Babar however describes the fracture in a slightly different way, as can be seen in the excerpts above.

Order *Neck Injuries* by Clicking here

Request a PDF file of this review by clicking here. (If your screen resolution can not be increased, or if printing this page is giving you problems like overlapping of graphics and/or tables etc, you can take a proper printout from a pdf file. You will need an Acrobat Reader though.)

Click here to read review of this book by Avneesh Gupta and Puneet Setia.

[Cumulative reviews of Software/Multimedia | Books on CD/Audio tapes] [contact us]