ANIL AGGRAWAL'S
Internet Journal of Forensic Medicine and Toxicology
The world's first online journal devoted entirely to forensic medicine and toxicology · Published 1 January and 1 July

VOL. 5, NO. 2 · JULY – DECEMBER 2004
Downloaded from www.anilaggrawal.com · ISSN 0972-8074 (Online) · https://www.anilaggrawal.com/ij/vol_005_no_002/papers/paper007.html

Prospects of Hanging Being Interpreted as Ligature Strangulation are Real (Twist in the tale by a scene examination)

Saurabh Sharma, S.K. Sharma

M-49, Old DLF Colony, Gurgaon (Haryana), India

Contact: Saurabh Sharma · sharmasaurabh_99@yahoo.com

CITE THIS ARTICLE

Sharma S, Sharma SK. Prospects of Hanging Being Interpreted as Ligature Strangulation are Real (Twist in the tale by a scene examination). *Anil Aggrawal's Internet Journal of Forensic Medicine and Toxicology* [serial online], 2004; Vol. 5, No. 2 (July – December 2004): [p. 21-24]. Available from: https://www.anilaggrawal.com/ij/vol_005_no_002/papers/paper007.html

ABSTRACT

A case report points to the uncomfortable fact that a suspicion of homicide entertained on the basis of findings of sharp weapon injury on the neck and mismatching evidence provided by the relatives was misleading. The relatives attributed death to a natural cause. Medical reports (both treatment and the autopsy report) showed that the deceased had suffered a nick to his neck. There was also a mark on the neck that resembled a ligature mark. The eyewitness account appeared suspicious and led the investigators to think of homicide as a possibility. While the debate on whether the relatives concealed the theory of hanging from others out of compulsion or fear raged on, what remained irrefutable was that it was a suicidal hanging. It was thus possible to miss diagnosis of hanging on autopsy.

Keywords: Artifacts in hanging, suicidal hanging, postmortem injury, social aspects of hanging, death-investigation, scene-examination, suicide appearing as homicide

Introduction

Many of those involved in death investigation may not agree with the view that the "history of hanging" is an important criterion for making an autopsy diagnosis of hanging. In today's investigation, where one is free to float theories, hypothesis -- confirmed and unconfirmed, sorting out suicidal and homicidal manner of death is not easy. There has been contention over the death of a young married man. He died in his own house in the presence of his family. The closest of the relatives present in the house had immediately arranged cardio-pulmonary resuscitation (CPR).

Incomplete and unverified information placed before the autopsy doctor prevented the desired autopsy outcome.

The deceased underwent emergency management in a nursing home. Those doctors who had attended him before declaring him dead had observed blood on the front of his banyan. (Fig. 1) An unexplained, tiny, incised wound was present on the left side/front of the neck. (Fig. 2) Those who did autopsy had noticed sub-conjunctival hemorrhages in both the eyes (Fig. 3), and an unexplained almost horizontal, non-grooved, pressure abrasion on the middle front of his neck. (Fig. 4) According to the family members of the deceased, this was a natural death. The incised wound and the abrasion on the neck were the creations of the doctors during their efforts of resuscitation. Doctors, who had attended and provided CPR, in response to an emergency telephonic call by his family members, however denied the same.



Figure 1



Figure 2

To the majority and to the police the projected story of natural death appeared doubtful. On the basis of the injuries on the neck police considered the death to be homicidal. According to them there was no mechanism of natural death to account for these injuries. Death was due to ligature strangulation.

On autopsy there was nothing suggestive of hanging, manual or ligature strangulation. The neck was not elongated. The mark was localized on the middle front of the neck with slight extension towards the left side. It was not grooved. Sub-conjunctival hemorrhages noticed in both the eyes (Fig. 3), the ligature mark and bright red extravasation of blood underneath the mark made the autopsy doctor opine that the death was due to asphyxia consequent upon mechanical pressure applied on the front and left side of the neck. The incised wound was a superficial nick and could not have caused death in the ordinary course of nature.



Figure 3

The only information that the autopsy doctor had until the completion of the autopsy was that the deceased reportedly fainted and fell on the ground in the bathroom. Subsequently his wife and the other relatives telephoned for medical assistance. Police sealed the bathroom. They also booked the death under the suitable section of causing murder. None of the family members attributed the death to any unnatural mechanism. The homicidal theory surprisingly did not have the support of the wife, or even the closest relatives. There were reportedly no eyewitnesses. Death investigators though suspicious of homicide thus were at the crossroad.



Figure 4

Discussion

The shape of the true story became visible after a fortnight, when the family members came out with a version of events different from that at the time of the autopsy. The deceased was seen hanging in the bathroom by a saree from the ceiling fan, was the story that emerged now. It was also disclosed that scissors (Fig. 5) had to be used to cut the ligature material around the neck. Getting the victim down from the fan was the priority of the relatives. When they were unable to

remove the noose manually, they cut it off. During this process the scissors used could have caused the injury on the neck. (Fig. 6). This led to a change in the perception of the entire story.



Figure 5

The new story of suicidal hanging, confirmed by the wife of the deceased, added a totally new dimension to initial theory of homicide. Why no one had ever said, least of all the family members themselves, that the deceased was seen hanging was a mystery. It is probably this part of the story that led to complexities of the matter at the autopsy from where the homicidal suspicion took off. Autopsy observations in it were not typical of hanging. Had they revealed about death by hanging, either to the treating doctors or to those who did police inquest or even to the autopsy doctor, things would have been different.

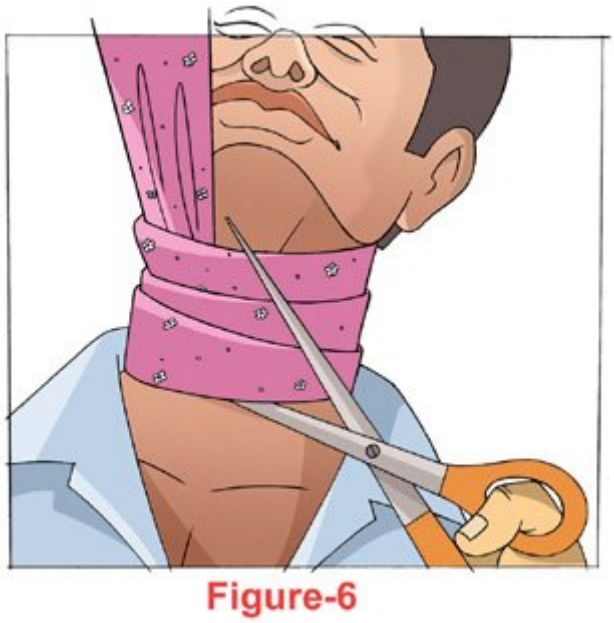

Figure 6

Case thus initially suspected to be that of homicide was found to be of suicidal hanging. The question arises that if the wife and other relatives knew about the hanging, then why did they not share the information with the treating doctors and the police? Was it that the relatives did not wish to spoil the prestige of the family? Or, did they not wish to tell the police anything which could lead to the inconvenience of an investigation into the reasons for the hanging?

Accepting the modification made in autopsy impression, police blamed the doctors for making a mistake and misguiding them. They said that the doctors first put them on the homicidal line of investigation, and then changed their opinion to suicide. Statements such as the one made by the police could put the autopsy doctor in an embarrassing situation. In fact it was the doctors ill-informed perception -- that police could furnish no explanation after examining the scene of crime, that led to their opinion of mechanical asphyxia. In seeking autopsy's help, the death investigators should not lose sight of the doctor's concern in finding out cause and manner of death. The autopsy doctor expects that the police would also view the problem of cause of death from the doctor's perspective. Just passing on the body without meaningful information in the inquest papers was misleading. Had police retrieved the true story of the circumstances surrounding the death, the results would have been different. They failed to realize that inadequate information would lead to an autopsy opinion of mechanical asphyxia.

The autopsy had its own limitations. Observation of ligature mark was no way suggestive of hanging. It was atypical and one could correlate it with that of hanging only after knowing that the body was hung. Moreover presence of incised wound on the neck rendered the situation of the type that it could have been elicited only after the perusal of the scene and facts relating to the occurrence. No definitive opinion about hanging could be given on the bases of only asphyxial signs coupled with confusing ligature mark. The duration of hanging was for about 5-10 minutes (victim was noticed few minutes after the occurrence). The ligature material was soft and there were two broad turns, almost covering the entire neck tightly. The portion of sari seen encircled and tied around the neck could produce the mark. The unsuccessful attempt to release the noose and the

urgency to remove it by cutting brought the use of scissors. The use of the scissors inadvertently caused the superficial nick to the neck.

Conclusion

Suicidal hanging can be misinterpreted as ligature strangulation. In a death with pressure abrasion restricted to the lower front of the neck, the blood soiled front of banyan (Fig. 1) and an unexplained, fresh bleeding, tiny, incised wound on the left side front of the neck (Fig. 2) a high index of suspicion for homicidal death should be raised. While no single test is perfectly accurate, the combination of a correct history and physical examination can aid in making a prompt, accurate diagnosis. In a case where the diagnosis remains uncertain, analysis of the situation at the scene after knowing the correct version of the circumstances can be helpful. In this case a member of an affluent family remained endangered for being remanded and jailed on charges of murdering his younger brother. The family initially concealed the actual story for the fear of damaging family prestige. Later on when they made up their mind to come out with the actual story many disbelieved them.

The story of hanging from bathroom fan emerged many days after the death. It was a bathroom having a platform with a washbasin fitted in it. A shaving kit along with two scissors (Fig. 5) were the main items that lay scattered on the platform. Access from this platform to the ceiling fan was possible. Two pieces of a saree, which is a 6-metre cloth and is the Indian women's usual wear, were produced as the ligature material. Cutting open the tight noose by the use of one of these scissors, resulted in two pieces of that saree. The police, however, remained unconvinced by the clues. Police described it as a frame-up and a concocted story.

The new facts observed by the forensic experts convinced the police that the death followed hanging, and that the small mark on the neck and the wound resulted as the family members now said. After examination of the scene forensic experts opined that the dead body had been a victim of hanging.