ANIL AGGRAWAL'S
Internet Journal of Forensic Medicine and Toxicology
The world's first online journal devoted entirely to forensic medicine and toxicology · Published 1 January and 1 July

VOL. 5, NO. 1 · JANUARY – JUNE 2004
Downloaded from www.anilaggrawal.com · ISSN 0972-8074 (Online) · https://www.anilaggrawal.com/ij/vol_005_no_001/papers/paper009.html

# Conscript Carrasco: A Peacetime Casualty

Adriana Oliva[1], Julio A. Ravioli[2]

[1]Chief of the Laboratorio de Entomologia forense, Museo argentino de Ciencias naturales, Av. A. Gallardo 470, C1405DJR, Buenos Aires, Argentina
[2]Titular Professor of Legal Medicine, Faculty of Medical Science, University of Buenos Aires, Former Medical Examiner of the National Judiciary Power, Argentina
Contact: Adriana Oliva · aoliva@macn.gov.ar

CITE THIS ARTICLE
Oliva A, Ravioli JA. Conscript Carrasco: A Peacetime Casualty. *Anil Aggrawal's Internet Journal of Forensic Medicine and Toxicology* [serial online], 2004; Vol. 5, No. 1 (January – June 2004): [p. 45-49]. Available from: https://www.anilaggrawal.com/ij/vol_005_no_001/papers/paper009.html

ABSTRACT

A young man under compulsory conscription was killed in Zapala, in the southwest of Argentina. An attempt to cover up his death was prevented by medical evidence of brutal battering and by entomological evidence of a 20-30 day post-mortem interval, which implied concealement of the body. Insect samples showed a single well-developed "wave" of the greenbottle *Phaenicia sericata*, consisting in mature larvae, a dead pupa and two empty puparia; this placed the death no later than 16 days before the finding of the body, but most probably 25-30 days before it.

Since neither younger larvae of the same species nor larvae of other species of corpse-frequenting fly were found, it was thought that the body had been hidden in a dark place, after a few hours in the light (allowing oviposition by greenbottles). Coleoptera associated with butyric fermentation (*Dermestes* sp., *Necrobia rufipes*) confirmed the dating. A yellowjacket wasp (*Vespula germanica*) suggested that the remains had been taken outdoors a little before being found. A single Histerid beetle *Saprinus patagonicus* provided a first record of this species in a forensic case.

**Keywords:** Forensic entomology, Calliphoridae, Dermestidae, Necrophilous Coleoptera, Post-mortem Interval, Patagonian fauna

## Introduction

The use of insects associated with corpses to determine the post-mortem interval has been attempted by some legal medicine experts in Argentina. However, because these professionals were not themselves entomologists, and because they never published their results, forensic entomology was not advanced in any way from such information as might be found in European books [1, 2]

until the year 1993. It was then that the authors of this paper began an interdisciplinary collaboration. The entomological treatment was based at first on bibliography [2, 3], until direct information was afforded through experiments and a gradual accumulation of autopsy data.

In April 1994, a case came to public notice through the media. Compulsory military service was still active at the time, and on the $6_{th}$ April a young conscript had been found dead on the barracks grounds near the town of Zapala, province of Neuquen, in the southwest of Argentina (photo 1, 2, 3). The authorities in charge claimed he had deserted just one month before, and suggested murder by person or persons unknown, who had thrown the body inside the grounds. A first post-mortem was performed at Zapala, not at the judicial Morgue but within the barracks premises. However, enough questions were raised about such a procedure, and a second autopsy was demanded.

The body was sent to the Morgue (Morgue judicial) at Buenos Aires, where insect material was collected from the body and clothes. The X-ray studies performed during the autopsy revealed grievous premortem battering and traumatic luxation of the sixth, seventh and eight costochondral joints. Furthermore, the first autopsy indicated an hemothorax of 1,500 ml. The entomological evidence showed a considerable post-mortem interval, not consistent at all with the story given out by the local Army authorities, which had been accepted by the Provincial prosecutor.

One very obvious problem was the lack of information about development times for Argentina at the time. As a matter of fact, since the town of Zapala is sited very little to the North of parallel 39°S, extrapolation of development times in Europe would have been quite adequate, making allowance for the very dry climate of the Patagonian steppe, which causes a large circadial temperature fluctuation. As it was, times had to be estimated with great caution.

## Materials and methods

### Medical aspects

The corpse belonged to a 19-20 year old male, of mixed Amerindian and Caucasian descent, with a height of 163 cm and a weight of about 53 kg. (This agreed with the personal data of 19-year-old Omar Octavio Carrasco. His drafting health file listed a weight of 57 kg and a height of 163 cm).

The body was in a state of partial putrefaction and partial mummification (Photo 4, 5). Both eyeballs were putrefact, the left one dislodged from the orbit due to the action of maggots. The corpse showed traces of the previous autopsy. The left side of the face, neck, shoulder and upper thorax exhibited an increase in volume with relation to the right sides. This was not due to bleeding or bruising, as it was demonstrated by making many incisions into the swollen left-side parts. Therefore, the swelling was interpreted as the result of positional post-mortem discoloration. The location of this discoloration contradicted the position in which the corpse was found (Photograph 3).

In view of the dislodgement of the left eyeball, the facial soft tissues were removed entirely and X-rays performed to verify the presence of possible trauma; however, no such trauma was found. The X-rays of the ribs revealed luxation of the sixth, seventh and eighth chondrocostal joints.

Live maggots were observed both on the corpse and the clothes, as well as within the coffin (photo 5, 6); also a live wasp was recovered from the clothes. Routine toxicological, biochemical and histopathological tests were performed.

### Entomological aspects

Label “larvae [from] clothes”: 26 Larvae III of the greenbottle *Phaenicia sericata* (Diptera: Calliphoridae).

Label “clothes 2”: 6 adults of the skin beetle *Dermestes* sp. One adult of the ham beetle *Necrobia rufipes* (Coleoptera: Cleridae) One adult *Saprinus patagonicus* (Coleoptera: Histeridae). One pupa of a Calliphorid fly (presumably *P. sericata*), puparium well preserved but contents decayed. One adult yellowjacket wasp *Vespula germanica* (Hymenoptera: Vespidae). The beetles were macerated and had a strong odour of decay, showing they had been placed in the tightly closed container when still alive. The wasp was contorted showing it had died of asphixia, also inside the container.

• Label “Bugs [from] shoes”: One adult of the skin beetle *Dermestes* sp.

• Label: “Maggots external”: 7 mature larvae of the greenbottle *P. sericata*.

• Label: “Maggots internal”: a mass of macerated larvae; the best preserved of these are identical with the precedent.

• Label: “A-2”: empty puparia of *P. sericata*. A 3 mm larva of *Dermestes* sp. had begun gnawing them, but this insect probably had hatched from the egg in the lapse between autopsies.

## Results

### Medical

Aetiology and mechanisms of death: the finding of luxation chondrocostal joints on the right side, together with an hemothorax of 1,500 ml suggested very strongly, in the absence of any other findings, that Carrasco had suffered severe battering with un unspecified blunt instrument, causing internal bleeding which determined death.

For a person weighting 56 kg (estimated blood volume 5,000 ml), an hemothorax of 1,500 ml represents a loss of blood volume dangerous to life, and which certainly would cause death unless immediate expert medical assistance was supplied.

### Entomological

The greenbottle oviposits on recent corpses. It is true that the eggs are laid as a rule in the eyes and nose, but when the larvae are ready to pupate they spread over the body before abandoning it to bury themselves in the earth (under natural conditions). We had no reason to believe that the sample came from an abnormal oviposition, since the larvae were all of similar size and fully grown.

The finding of a pupa and empty puparia show that some individuals had completed their development. Also, the autopsy photographs show the work of maggots in the left eye socket (photo 4), which would be the prefered oviposition site for the earliest period after death. Neither *P. sericata* larvae younger than those described, nor larvae of other species were found.



***Fig. 1.*** *The lying of the land. Barracks buildings in the middle distance. Typical Patagonian steppe in the foreground; mountains in the background.*



***Fig. 2.*** *The dumped body.*



***Fig. 3.*** *A closer view of the body, showing post-mortem lividities not connsistent with the declivity of the terrain.*

The presence of *Dermestes* sp. and *Necrobia rufipes* indicates a beginning of butyric fermentation at least in the limbs. Unfortunately, there is no clearcut medical evidence as to the shortest post-mortem interval at which this stage begins. The presence of *S. patagonicus* is less conclusive, since this species preys on maggots of any size, and therefore cannot be associated with one given stage of decay.



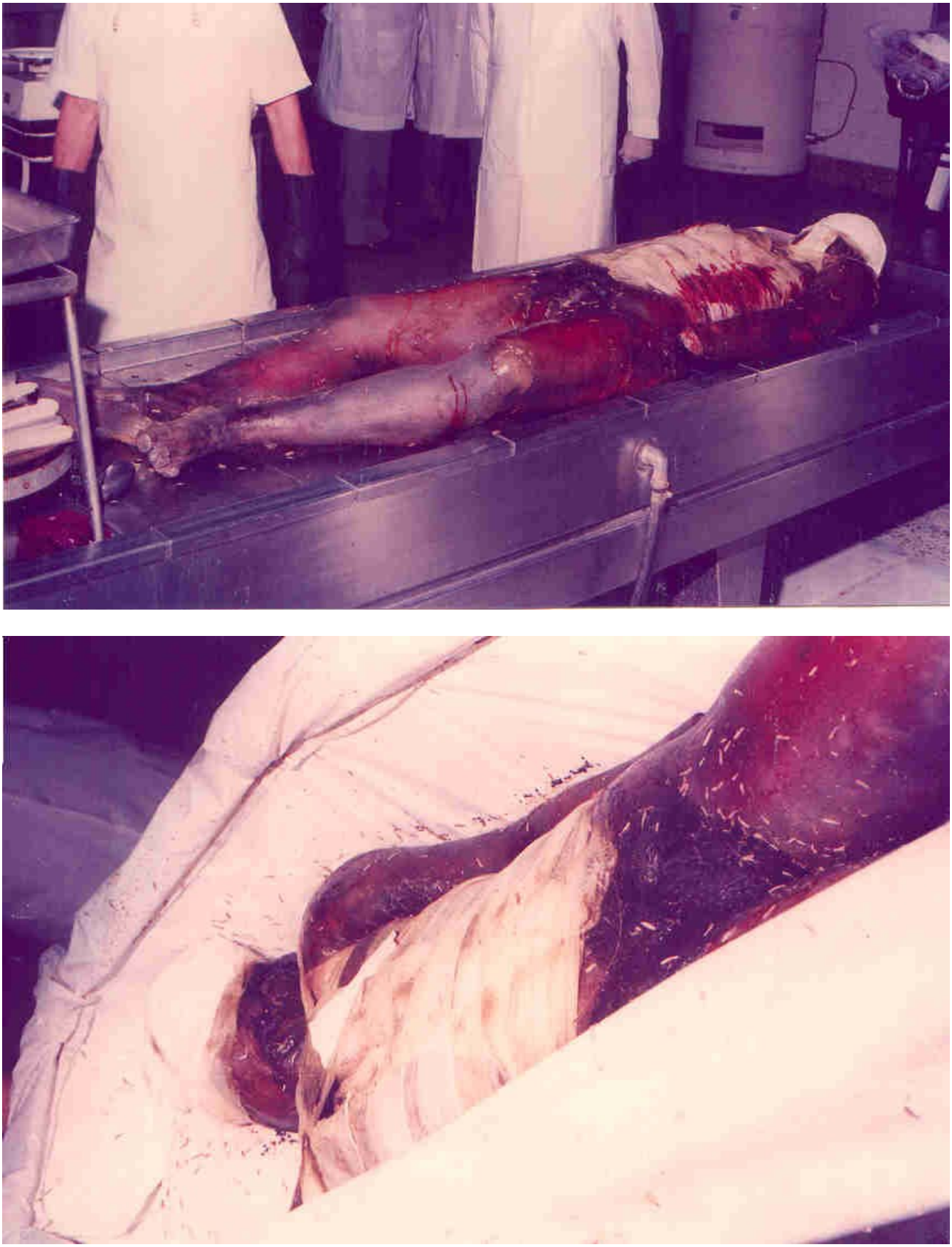

***Fig. 4-6.*** *Autopsy: view of the face, showing the work of maggots in the left eye socket (above); body partly mummified, partly putrified, note migrating maggots (middle and bottom)*

## Discussion

One or more normal ovipositions by *P. sericata* show that the corpse was exposed to daylight for a few hours at least, although it is just possible that the victim was not dead at the time of oviposition. This does not affect the case, as he would have had to be very close to passing away, and therefore the victim, if not of murder, of what Argentinian law describes as extremely grievous bodily injury. The fact that adults had begun to emerge from the puparia indicates the lapse of, at the very least, ten days, although more probably 25-30 days.

On the base of data which gave fourteen and a half days for total preimaginal development at a constant temperature of 22 °C [3], a first estimation was made of 16 days minimum. This was because the medium temperatures for March at 39S were estimated to have been a few degrees below 22 °C. On the other hand, the presence of *Dermestes* and *Necrobia* beetles indicated the beginning of butyric fermentation and pointed to a longer interval.




***Fig. 7:*** *Map of Argentina. Province of Neuquen in yellow. The cities of Buenos Aires (capital of the country), Neuquen (capital of the province) and Zapala are marked.*

One factor with which we were not conversant at the time of the trial was the effect of wide daily temperature variation on the development rate of dipteran larvae. When the first author was giving evidence, a temperature sheet was presented in court, showing that the maximal temperatures had been very high indeed for the month of March, above 30 °C, while the minimal had descended below 5 °C, cold enough to stop insect activities.

Since at the time the author had no reliable information on the effect of such wide circadial fluctuations on the development rate of larva, it was considered more prudent to broaden the range and consider ten days as a minimum. Later on, some evidence came at hand [4] that this environmental factor produces longer development times, which supports the longer PMI estimate.

At the moment, literature in common use [2, 3] mantained that *P. sericata* oviposits on corpses only when they are in direct sunlight. It is widely known that this concept has been challenged [5]. In any case, the corpse must have been exposed to daylight, either in open air or through a window. This means that there was a period of time in which the corpse was left in a place where it was not concealed, and that later it was moved (as said) to a dark place. This time, however, may have been as brief as half an hour; even a few minutes may be enough for oviposition by *P. sericata*, and a single female, if left undisturbed, may have laid hundreds of eggs. The high number of maggots suggests rather collective oviposition by several females, but there is no conclusive evidence either way.

Some experimenting made in the city of Neuquen with domestic pig as a model produced a sample of *P. sericata* adults and pupae (that is, a sample slightly more advanced than the one in question) after 31 days of decomposition in a laboratory [6].

An interesting case of a body six weeks indoors has been described from Cologne, Germany [7]. Here, a lighted lamp had been left near the body. The left eye, further from the light, had been consumed by larvae of *P. sericata*, but at the moment of the finding there was a mass of larvae in the right eye-socket. This is explained on the grounds that, through general dryingout of the remains, the eye closest to the lamp had become the only feeding material for maggots, so that the youngest of these had to go there in spite of their aversion to light.

The body of Omar Carrasco, after (probably) four weeks, had larvae of *P. sericata* in the left eye-socket, which must have been nearer the ground judging by the post-mortem discoloration. The lower limbs had entered butyric fermentation and showed no feeding by insects. Had the corpse remained hidden for a couple of weeks more, there can be little doubt that the limbs would have begun to dry out.

In the case of Carrasco, however, no younger larvae were remarked, and it appears likely that there were none, because the body was hidden in a dark place and flies no longer had access to it. The younger larvae which switched to the right eye in the case from Germany must have come from later ovipositions, which can be explained by the presence of the light, moderately strong, but very close to the body. Oviposition of *P. sericata* in artificial light has been recorded before [5].

## Conclusion

Both medical and entomological findings showed that the death of Omar Octavio Carrasco had occurred more than a fortnight prior to the “official” finding of his body; that the said body had been concealed in conditions pointing to the participation of several persons, and therefore to collusion.

The pressure of public opinion, fed in part by indignation at this case, brought about the supression of compulsory military service in Argentina.

## References


1. P. Mégnin, La faune des cadavres. Application de l´entomologie a la medicine legale, Encyclopedie scientifique des Aides-Memoire, Masson, Paris Gauthier-Villars, 1894.
2. M. Leclercq, Entomologie et Medecine legale. Datation de la Mort. Collection de Medecine Legale et de Toxicologie Medicale, n° 108, Masson, Paris, 1978.
3. K.V.G. Smith, A Manual of Forensic Entomology. The Trustees of the British Museum (Natural History), London and Cornell University Press Ithaca, 1986.
4. Z. Erzinclioglu, Blowflies. Naturalist´s Handbooks, Vol. 23. The Richmond publishing Co., 1996.
5. B. Greenberg, Nocturnal oviposition of blow flies (Diptera: Calliphoridae). Journal of Medical Entomology 27(5): 807-810, 1990.
6. A. Oliva, unpublished data.
7. M. Benecke, Rein einseitiges Auftreten von Schmeissfliegenmaden im Gesicht einer Faulleiche. (Unilateral occurence of blow flies in one eye socket of a deceased person.) Archiv für Kriminologie 208: 182185 (2001).