ANIL AGGRAWAL'S
Internet Journal of Forensic Medicine and Toxicology
The world's first online journal devoted entirely to forensic medicine and toxicology · Published 1 January and 1 July

VOL. 2, NO. 2
Downloaded from www.anilaggrawal.com · ISSN 0972-8074 (Online) · https://www.anilaggrawal.com/ij/vol_002_no_002/reviews/ar/page001.html

Animated Reviews

OTHER REVIEWS IN THIS ISSUE
[Technical Books Section] Pages: |1| 2| 3| 4| 5| 6| 7| 8| 9| 10| 11| 12| 13| 14| 15| 16| 17| 18| 19| 20| 21| 22| 23|
[Popular Books Section] Pages: |1| 2| 3| 4| 5| 6| 7| 8| 9|

[Animated Reviews] Pages: |1| [Software/Multimedia] Pages: |1|2|

REVIEWS IN THE PREVIOUS ISSUE | NEXT ISSUE

Forensic Emergency Medicine *by* Jonathan S. Olshaker, M. Christie Jackson and William S. Smock. Hardbound 7" x 10"
Lippincott Williams & Wilkins, (A Wolters Kluwer Company), 530 Walnut Street, Philadelphia, PA 19106-3621, USA; xvi + 299 Pages, 147 Illustrations, 41 in full color, 20 tables: ISBN 0-7817-3144-5: Hardback edition, May 2001: Price $99.00 (£ 75.00)

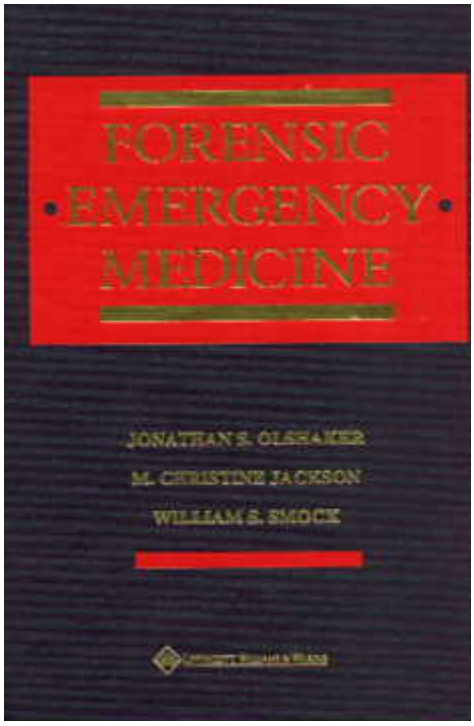

*****

These pictures are just a few of very high quality pictures appearing in this book. Can you identify these pictures? (N.B. These pictures might take some time to load, but the wait should be worth it. To stop the pictures temporarily, please bring the cursor over the pictures. To make them move again, remove the cursor from over the pictures. For answers, see the blue box below and to the right.)

*****



FORENSIC PHYSICIAN IN AN EMERGENCY SETTING

Till about a quarter of a century back, the subject of forensic emergency medicine was not much talked about. This term has gained currency mainly during the last decade, and now *Lippincott Williams & Wilkins* has come out with the first ever book fully devoted to this subject.

A full listing of the Contents of *Forensic Emergency Medicine*

CONTENTS

1. Perpetrators
2. The victims of violence
3. Interviewing techniques
4. Forensic Emergency Medicine
5. Forensic Examination of victims and Perpetrators of Sexual assault
6. Sexual abuse and sexual assault of adolescents
7. Child abuse/Assault - General
8. Elder Abuse
9. Treating survivors of Intimate partner abuse: Forensic Identification and documentation
10. Sexual assault and the Criminal Justice System
11. Testifying
12. Law enforcement
13. Forensic Photography in the Emergency Department

Animated Quiz
(Forensic Emergency Medicine)
ANSWERS

Figure 1: (Forceful expansion of the skin overlying the right temple resulted in a muzzle contusion from the barrel of a 9-mm semi-automatic handgun (figure 4-9B of the book).

Figure 2: "Tattooing" is the result of partially burned or unburnt gunpowder impacting skin. The "tattoos" are punctate abrasions and associated with an intermediate-range gunshot wound. Tattooing has been seen with wounds as close as 1 cm and as far away as 1 m (figure 4-12A of the book).

Figure 3: This patient stated that he was shot with a .22 caliber handgun at a distance of 12 in. His cheek exhibited punctate abrasions or "tattooing' associated with intermediate-range gunshot wounds. (figure 4-12B of the book).

Figure 4: Forehead "tattooing" from an intermediate-range gunshot wound. The patient reported he was shot with a .38 caliber revolver from a distance of 18 in. (figure 4-12C of the book).

Figure 5: Immersion or "dunk" burn caused by dipping foot in hot liquid. Note the clear delineation of burned and normal skin along with uniform degree of burn (here a second-degree burn) throughout the burn distribution. (figure 7-4A of the book).

Figure 6: Immersion burn caused by dipping infant in hot liquid. (figure 7-4B of the book).

Figure 7: Note where skin folds protected underlying tissue from serious burn. (figure 7-4C of the book).

Figure 8: Figures 8, 9, 10 and 11 are from a series of photographs which illustrates how photographs can be used to demonstrate mechanism of injuries. In this photograph the victim has obvious facial trauma to her left eyelid, left lateral nose, and mouth. The left lateral nose contusion was caused by the nosepiece of her glasses being forcefully pushed into her nose from a

punch injury to left eye. The patient's glasses absorbed much of the punch force and were broken (not pictured). Hence, the actual trauma to her left eye was limited to left upper eye lid. A second punch produced the mouth trauma.

Figure 9: The force of the punch caused the upper teeth to leave patterned contusion, abrasion and minor laceration trauma to oral mucosa.

Figure 10: A few of the victim's upper teeth are shown to demonstrate the source of the trauma.

Figure 11: The victim has a patterned puncture wound to the lower oral mucosa that corresponds to the teeth shown in figure 10.

Figure 12: Multiple, patterned, fingertip-like contusions to the left upper arm.

Figure 13: Multiple, patterned, punch-like contusions to the left upper arm.

Figure 14: Patterned, defensive, posture-like contusions to ulnar surface of the left arm.

Figure 15: Patterned, hidden, punch-like contusions to the upper abdomen and lower anterior chest.

Figure 16: Patterned, foot kick/stomp-like contusion to the right, superior lateral thigh pushing blood outward from the point of impact and patterned, foot kick/stomp-like contusion to the right inferior lateral thigh.

Forensic Medicine, as we all know is the application of medical knowledge for the purpose of administration of law and justice, but what exactly is Emergency Forensic Medicine? It is seen that in Emergency rooms, physicians and surgeons frequently encounter cases with potentially serious medico legal implications, without them ever realizing it. Consider for example the simple case of a young girl who has been sexually ravished, and her private parts are bleeding profusely. Since her profuse bleeding is imminently dangerous to her life, quite obviously she is brought to the emergency department. How exactly are the doctors going to approach this patient? Is their main thrust on saving the life of the patient, or is it also on proper documentation of injuries, collection of trace evidence, a detailed history to properly identify the culprit and so on. Well, the experience has shown that the doctors are largely ignorant of medico-legal issues, and are quite content with just treating the patient. In our hypothetical case for instance, the doctor may miss the simple precaution of keeping a vaginal swab, or may be looking for alien hair in the region of the pubes. Quite possibly, the doctor may forget (or ignore) documenting the injuries properly in his report. All these acts of omission can actually hamper the law enforcement agencies to press their case home. In other words, the doctor might inadvertently be helping the criminal by not paying attention to these details. A proper training of emergency doctors in medicolegal issues can go a long way in preventing such unsavory situations. And this is what Emergency Forensic Medicine is all about: performing the essential tasks of recognition, evaluation, treatment, proper documentation, trace evidence collection, appropriate referrals (e.g. to child and adult protective services, social workers, sexual assault nurse examiners, police forensic technicians and so on) and perhaps even giving much needed psychological support to the patient.

Patterned, fingernail-like scratch abrasions to right lateral neck from strangulation. The forensic emergency physician would do well to document these injuries in detail.



William Smock defines *Forensic Emergency Medicine* in chapter 4. It is the application of forensic medical knowledge and appropriate techniques to living patients in the emergency department. Daniel J. Sheridan in his chapter *Treating Survivors of Intimate Partner Abuse: Forensic Identification and Documentation* tells us that frequently health care providers misuse common forensic medical definitions. A common injury seen in Emergency settings is the patterned injury (as shown on the left). These must be properly labelled and documented. A wrong labelling or failure to document such injuries may cause miscarriage of justice.

An interesting example of proper use of the knowledge of *Forensic Emergency Medicine* is given in chapter 4. A twenty year old Black man once presented himself at a trauma center with a perforating gunshot wound to the left shoulder. He insisted that he had been shot by his adversary from a distance of about 30 feet. When the police came to the Emergency Department, he implored them to apprehend his adversary. The police would have probably done so, but the treating physician saw soot particles around the entry wound as well as also on the patient's shirt. Since the doctor was trained in Emergency Forensic Medicine, he confronted the patient with this information. All forensic personnel know that soot *can not* gather around the wound, if the gun was at a distance of 30 feet. Faced with this evidence, the person retracted his statement, and confessed that he had inflicted the wounds himself to frame his adversary.

The author stresses here that normally the emergency physician would have been happy to clean and debride the wound for "better management", and this would have resulted in disaster for the implicated man. For the only evidence in his favor would have been lost. Evidently emergency physicians must be trained in relevant forensic issues.

This problem was realized almost a decade earlier. The first postgraduate training program for emergency physicians dealing with clinical forensic medicine was a 2-day seminar in Chicago in 1990. It was sponsored by the Illinois Chapter of the American College of Emergency Physicians. This program was however suspended after its first year. Another course - an annual postgraduate clinical forensic medicine training seminar - was subsequently established in Louisville in 1994 by the Kentucky Chapter of the American College of Emergency Physicians. This program continued through 1998.

Bite marks on the breasts can be very valuable pieces of forensic evidence

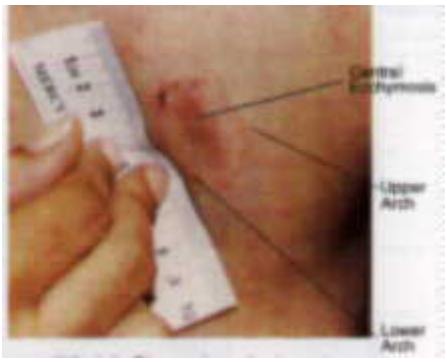

As this book tells us, the knowledge of Forensic Emergency Medicine can be fruitfully used in a vast variety of different settings - in cases of child abuse, elder abuse and in sexual trauma. Cases of bite marks on the breast were - till now - not seen by the emergency physicians with a view to gathering forensic evidence. A forensic physician trained in Forensic Emergency Medicine, views these wounds now with a different angle. His main aim is not only to treat and manage the injury, but also to properly document it. In documenting the bite mark, the site, size, shape, color and type of injury are included (e.g. contusion with ecchymosis, abrasion, laceration, incision, avulsion, petechial lesion). Findings such as smooth skin or indentation of the skin by the teeth are noted. It also helps to know that many times bruising develops later. So if despite history of being bitten, the physician can not see any obvious injury, he must wait for some time for possible bruising to develop.

A number of useful techniques are described in the book, which the emergency physician can fruitfully use in his practice. One which I found very interesting was the use of 1% aqueous solution of Toluidine Blue to document injuries during a sexual assault. This technique was developed by Lauber and Souma in early 1980s. Toluidine Blue is a nuclear stain. Normal vulval skin does not contain nuclei and therefore does not bind the dye. However after sexual trauma, disruption of normal vulval skin occurs and deeper layers are exposed. These contain nuclei and do bind the dye. The result is that one can see stained areas indicating that trauma has occurred. The technique of applying this dye is simple. It is applied to the posterior fourchette or rectal area with a cotton-tipped applicator and let dry. After some minutes, the dye is removed with lubricating gel and a 4x4 gauge. The dye is not to be applied to mucosal surfaces. The accompanying photographs can tell the reader the difference this dye makes in properly documenting these injuries. The dye is not systematically absorbed and is thus completely safe. It can be used even in pregnant females for the same reason.

The use of Toluidine Blue dye in Documenting microlacerations caused by Sexual assault. *Left*: injuries to the vulvar area as seen with the naked eye before the application of Toluidine Blue. *Right*: injuries to the vulvar area as seen after application of Toluidine Blue Dye.





Investigators have compared the incidence of genital microlacerations detected in sexual assault victims with gross visualizations alone versus that with the addition of toluidine blue dye in the same patients. The detection of injuries increased significantly - from 4% to about 58% - with toluidine blue dye testing. This single fact tells volumes about the benefits which can be reaped with the proper application of appropriate forensic techniques in emergency departments.

The book is full of such methods and techniques, and the reader would do well to read all the techniques for himself. This book is richly illustrated with a number of Black and White and color illustrations. This book should be read by all Emergency physicians, clinical forensic medicine experts, pediatricians and geriatricians. Law enforcement authorities may find this book of use too. Fully recommended to all these personnel.

Order this Book by clicking here.