ANIL AGGRAWAL'S
Internet Journal of Forensic Medicine and Toxicology
The world's first online journal devoted entirely to forensic medicine and toxicology · Published 1 January and 1 July

VOL. 2, NO. 2 · JULY – DECEMBER 2001
Downloaded from www.anilaggrawal.com · ISSN 0972-8074 (Online) · https://www.anilaggrawal.com/ij/vol_002_no_002/papers/paper005.html

A Case Of Strangulation Fabricated As Hanging

B.L. Sirohiwal, P.K. Paliwal, Bharat Bhushan, D.R. Yadav

Associate Professor, Department of Forensic Medicine, Pt. B.D. Sharma PGIMS, Rohtak, Haryana, India
Senior Resident, Department of Forensic Medicine, Pt. B.D. Sharma PGIMS, Rohtak, Haryana, India
Professor & Head, Department of Forensic Medicine, Pt. B.D. Sharma PGIMS, Rohtak, Haryana, India

CITE THIS ARTICLE

Sirohiwal BL, Paliwal PK, Bharat Bhushan, Yadav DR. A Case Of Strangulation Fabricated As Hanging. *Anil Aggrawal's Internet Journal of Forensic Medicine and Toxicology* [serial online], 2001; Vol. 2, No. 2 (July – December 2001): []. Available from: https://www.anilaggrawal.com/ij/vol_002_no_002/papers/paper005.html

ABSTRACT

A young adult male was found hanging from a ceiling. The ligature mark around the neck was seen to be placed transversely, and was placed quite low on the neck. This is usually seen in stragulation. Keeping in view this fact, as well as the fact that there were associated injuries on the body; the cause of death was given as strangulation. Subsequent to this, a criminal case was registered against the suspects. Investigating agencies, instead of trying to investigate the matter further, were adamant to label it as a case of hanging. The photographs and the circumstantial evidence clearly indicated that the body was hanged by someone else after strangulation, a rare phenomenon of strangulation made to look like hanging.

Keywords: Ligature mark, strangulation, fabricated hanging, homicidal hanging


1.

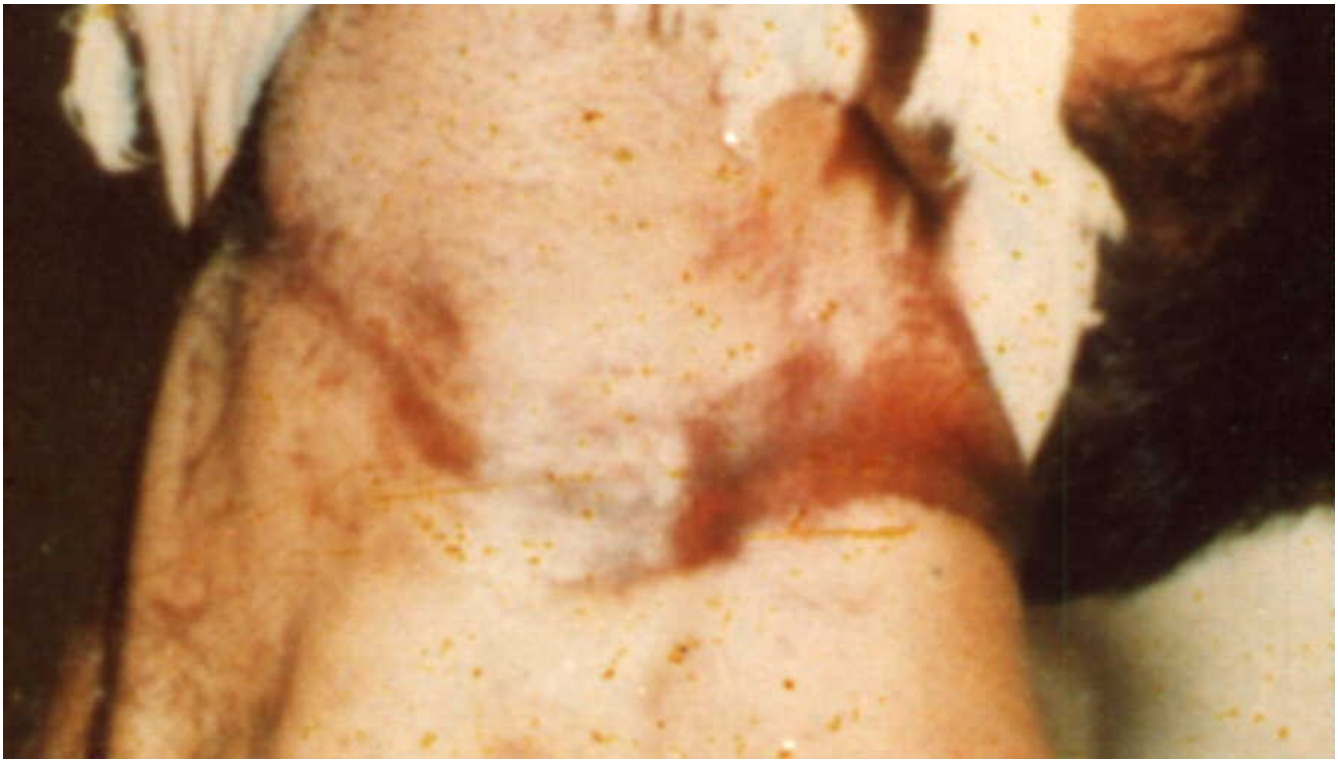

Figure 1: Photograph of the scene of crime (left). Details of ligature mark (right). Click on images to enlarge

Brief History

A 35 year old, average built male, married for 9-10 years, having two children, working in a shoe company and also maintaining a dairy farm, was found hanging from the ceiling in his own house (we will call him X for latter reference). His co-worker used to visit the dairy farm frequently along with one of his friends. This caused X to suspect his wife of infidelity.

On the night of incidence, the wife of the deceased X alleged that she was given some pills by her husband as a result of which she felt very sleepy and slept off along with children on the floor in the side room adjacent to the bed room. She also stated that when she got up in the early hours of morning to have water from the kitchen, she found her husband hanging from the ceiling in the bedroom.

Postmortem examination


2.



Figure 2: Photograph of the scene of crime (left). Details of ligature mark (right). Click on images to enlarge

The body was received for postmortem examination without the ligature material around the neck. The face was congested, and tongue was bitten. A horizontal ligature mark below the thyroid cartilage was found. It was continuous around the neck, reddish in colour and had echymotic edges. On dissection, the subcutaneous tissues were found to be ecchoymosed. Neck muscles showed signs of trauma. The tracheal cartilaginous rings were fractured. The trachea was congested and contained blood stained froth. Multiple abrasions and contusions were present on chin, left axilla, both arms and abdomen suggesting struggle.

DISCUSSION

Differentiating between hanging and strangulation is an age old problem. Much depends on observations made by the investigating officer. An exhaustive examination of the scene of crime, ligature material, placement of ligature mark over the neck and other associated findings go a long way in deciding the issue. Usually in strangulation, the ligature mark is transversely placed in the lower aspect of neck below the level of thyroid cartilage in strangulation whereas in hanging it is obliquely placed in the upper aspect of neck. [1,2,3,4,5,6]


3.

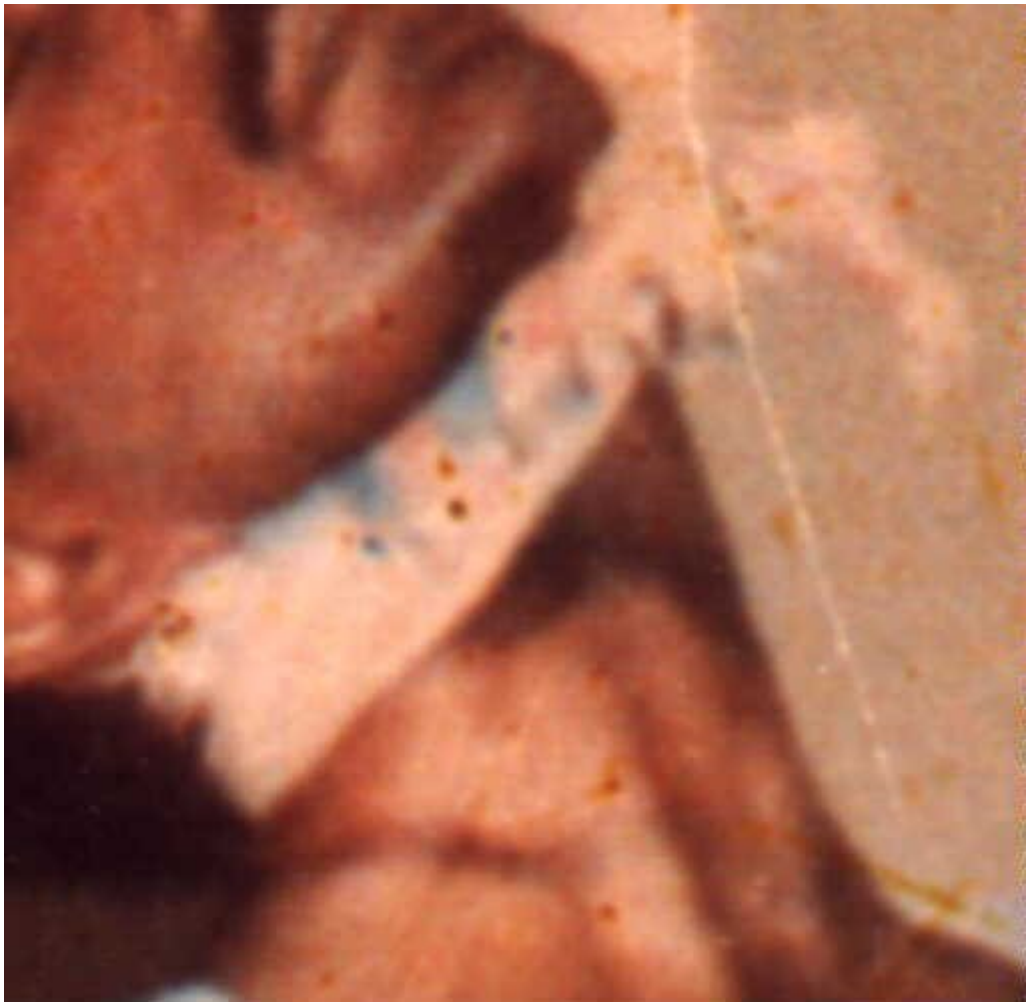

Figure 3: Photograph of the scene of crime (left). Details of ligature mark (right). Click on images to enlarge

The present case was received for postmortem examination without the ligature material and the photographs. Though the photographs of the scene of incidence were taken earlier but were not made available at the time of postmortem examination for review. During the postmortem examination, a horizontally placed grooved ligature mark was found below the thyroid cartilage, which was continuous around the neck. It was reddish in colour having echymotic edges. Associated multiple abrasions were present on body parts like chin, left axilla, both arms and abdomen suggesting struggle. Considering these facts, strangulation was opined as the cause of death. The strangulation made to look like hanging was further supported by reviewing the photographs [figures 1 to 3] subsequently. They not only revealed the nature of ligature material, but made it possible to co-relate the position of ligature material with the position of ligature mark. Furthermore, the ligature mark has clearly been produced by some strong, firm, thin material, while the ligature material appearing in the photographs is a bed sheet, which is broad and soft.

This is an interesting case, where a careful study of the ligature material, ligature mark, and their comparative study made it possible to conclude positively that it was a case of strangulation fabricated as hanging. Circumstantial evidences should also be taken into consideration to label a case either as of hanging or of strangulation. In the present case, the circumstantial evidence goes in favour of strangulation made to look like hanging. The room was open. The marital relationship

between the husband and wife were strained. Finally, there was no suicide note at the scene of crime.

CONCULSION

From the above-mentioned facts it is evident and clear that it is a rare case of strangulation fabricated as hanging.

References

1. Modi N.J. Medical Jurisprudence and Toxicology edited by Subrahanayam B.V., Butterworths India, 22nd ed. 1999. pages 254, 263
2. Spitz W.U., Fisher R.S.; Medico legal Investigation of death - Guidelines for the application of pathology to Crime Investigation. Charles C.Thomas Publication U.S.A. 1977 page 270
3. Gordon I. Shapiro H.A., and Berson S.D. Forensic Medicine - A guide to Principles. Churchill Livingstone New York. 3rd ed. 1988. pages 108, 112.
4. Mant A.K. Taylor's Principles and Practice of Medical Jurisprudence Churchill livingstone New York 13th ed.1984, pages 306, 313.
5. Francis E.C. Grawohl's Legal Medicine British John Wright & Sons Ltd. 3rd ed. 1976, page 332.
6. Bernard Knight. Forensic pathology, London ; Edward Arnold, 1990 ; pages 345-350, 353-355.