ANIL AGGRAWAL'S
Internet Journal of Forensic Medicine and Toxicology
The world's first online journal devoted entirely to forensic medicine and toxicology · Published 1 January and 1 July

VOL. 2, NO. 1 · JANUARY – JUNE 2001
Downloaded from www.anilaggrawal.com · ISSN 0972-8074 (Online) · https://www.anilaggrawal.com/ij/vol_002_no_001/papers/paper006.html

Bullet embolism following firearm injury - A case report

Sunil Kumar G.A., Agnihotri A.K., Bhardwaj D.N., Dogra T.D.

Junior Resident, Department of Forensic Medicine & Toxicology, All India Institute of Medical Sciences, Ansari Nagar, New Delhi-110029, India
Senior Resident, Department of Forensic Medicine & Toxicology, All India Institute of Medical Sciences, Ansari Nagar, New Delhi-110029, India
Associate Professor, Department of Forensic Medicine & Toxicology, All India Institute of Medical Sciences, Ansari Nagar, New Delhi-110029, India
Professor & Head, Department of Forensic Medicine & Toxicology, All India Institute of Medical Sciences, Ansari Nagar, New Delhi-110029, India

CITE THIS ARTICLE

Sunil Kumar GA, Agnihotri AK, Bhardwaj DN, Dogra TD. Bullet embolism following firearm injury - A case report. *Anil Aggrawal's Internet Journal of Forensic Medicine and Toxicology* [serial online], 2001; Vol. 2, No. 1 (January – June 2001): []. Available from: https://www.anilaggrawal.com/ij/vol_002_no_001/papers/paper006.html

ABSTRACT

Abstract (English)

Firearm injury is one of the leading causes of violent morbidity and mortality in our country, because of the increase in both the presence and usages of illegal guns in recent years. Bullet remobilization through the arterial or venous system, although unusual, often causes confusion and difficulties in diagnosis. This paper reports a case of a migrating intravascular bullet embolus, wherein a handgun missile perforated through the wall of the internal jugular vein and was transported to the right atrium by the flow of the blood. The bullet was eventually recovered to establish the identity of the responsible firearm. The implications of a bullet embolism through vessels for forensic experts are discussed briefly.

Abstract (French)

Les dommages d'arme à feu sont un des causes principales de la morbidité et de la mortalité violentes dans notre pays, en raison de l'augmentation de la présence et des utilisations des pistolets illégaux ces dernières années. La remobilisation de balle par le système artériel ou veineux, bien que peu commune, occasionne souvent la confusion et les difficultés dans le diagnostic. Cet article enregistre un cas d'un embole intravascular de balle de passer, où un missile

de handgun perforé par le mur de la veine jugulaire interne et a été transporté à l'oreillette droite par l'écoulement du sang. La balle a été par la suite récupérée pour établir l'identité de l'arme à feu responsable. Les implications d'un embolisme de balle par des navires pour les experts légaux sont discutées brièvement.

Click here to go to full French translation.

Keywords: Bullet Embolism, firearm injury, venous remobilization

Introduction

Firearm deaths are a major public crime hazard and have been increasing over the past several decades. Each firearm wound is a type of punctured lacerated wound, with a wound entrance progressing deep inside, making a track of the bullet and sometimes an exit wound. Bullet embolism is one of the rarest complications following a firearm injury, which often creates confusion and difficulty in finding the bullet.

In this paper, we have described a case of handgun injury with the embolism of a bullet from the left internal jugular vein to the right atrium. The victim initially survived for about twenty minutes, but was when she was brought to the hospital, she was already dead.

Case Report

A 30 year old woman, was shot in the home by her husband because he suspected that she was not faithful to him. The weapon used was a handgun (country made i.e. locally manufactured). There was a firearm entry wound of 2 cm x 1 cm size, with tattooing all around the left side of the posterior chest wall, at the level of the 4th intercostal space, and 12 cm from the midline. The distance between the gun muzzle and the victim was about two feet i.e. within the range of tattooing. The bullet went through skin, subcutaneous tissue, muscles, both the lobes of the left lung and finally penetrated the apex of the lung, and perforated the anterolateral wall of the left internal jugular vein in the neck. After that, the bullet passed through the venous circulation and then lodged in the right atrium (the whole track shown in Fig. 1).

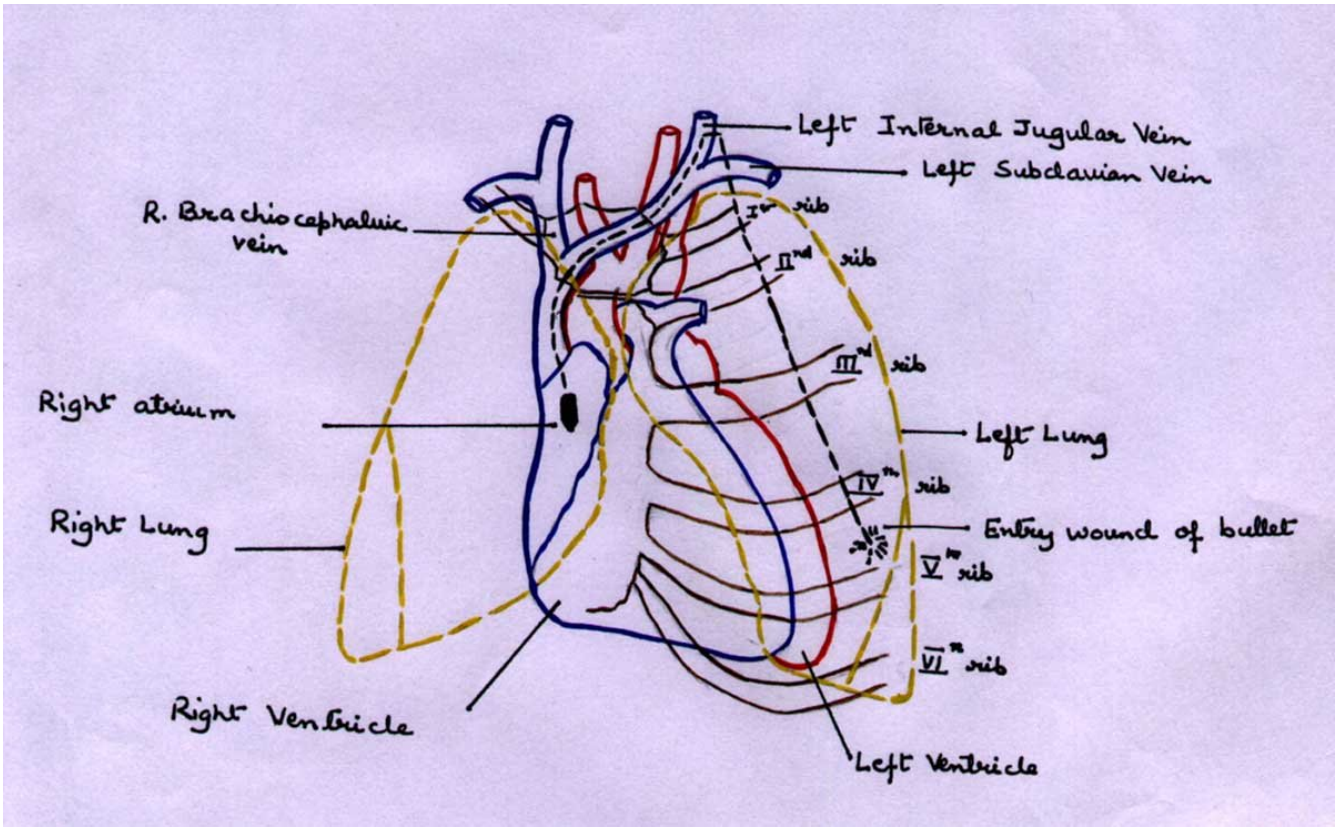

Figure 1: track of the bullet

The veins showed intimal tears throughout the track. The neck showed diffuse hematoma over the left side, and the left lung was found to be collapsed. The pleural cavity contained about 1350 ml of blood. The cause of death was given as hemorrhagic shock due to a firearm injury. The clothings, blood in gauze piece, and the recovered bullet were preserved, sealed and handed over to I.O. (investigating officer i.e. police) along with sample of seal for further examination of bullet by ballistic expert. The dimensions of bullet were measured as 2.7cm x 0.8 cm with deformed tip.

DISCUSSION

Most authors agree that embolisation of a bullet is an uncommon and rare event showing an incidence of about 0.3% among vascular injuries[1,2]. Bullet emboli are usually associated with small caliber, low-velocity missiles (e.g. 0.22 caliber) or airgun pellets[3,4]. Bullet embolism should be suspected if the victim sustained a firearm injury, does not show an exit wound, and no missile is found in the area of direct trauma. In these cases, a whole body X-ray should be performed before autopsy, as the bullet may have traveled with the flow of the blood, and lodged in a different location. As in our case, the bullet, after perforating the internal jugular vein of the left side, traveled through the venous circulation and lodged in the right atrium. In such situations, the use of X-ray is an invaluable time saver. However, in one of our cases we have utilized metal detector for detecting the location of bullet[5]. The majority of bullet emboli involve the arterial system, and missiles embolise predominantly in the lower extremities, and less frequently in the upper extremities and neck vessels[6,7]. Michelassi et al[7] enumerated a total of 53 bullet embolisms in the venous side of the circulation. The site of the bullet entrance was located in the inferior venacava in 55.9%, in the superior venacava in 20.6%, and in the heart or the pulmonary artery in 23.5%. Most of the venous emboli moved to the pulmonary arteries; 26.9% lodged in the heart, mostly trapped in the tricuspid valve. In our case the bullet was recovered from the right atrium trapped

by the tricuspid valve. Patel et al[8] presented a case in which a 0.38 caliber bullet was removed from the right atrium after sustaining injury to inferior venacava. However, in our case, 0.32 caliber bullet recovered also from right atrium.

CONCLUSION

The case gives the message that there should be an appropriate body area X-ray, before autopsy in every case of firearm injury without exit wound. This helps in easy recovery of the bullet, as well as saving our invaluable time. It also avoids any unnecessary mutilation of the body. After recovery, the bullet should be measured properly, weighed and some identification mark should also be made at the base. The X-ray plate also acts as corroborated evidence.

References

1. Harken DE and Zoll PM : Foreign bodies in and in relation to the thoracic blood vessels and heart III. Indications for the removal of intra-cardiac foreign bodies and the behavior of the heart during manipulation. *Am. Heart J.* 32 (1946) pp 1-19
2. Rich NM, Collins GJ, Anderson RT, Kozloff L, Ricotta JJ : Missile emboli, *J. Trauma* 18 (1978) 236-39.
3. DiMaio VJM and Dimaio DJ : Bullet embolism; Six cases and review of literature. *J. Forensic Sci.* 17 (1972) 394-98.
4. Scllier K : Schusscoaffen and Shusswir Kungen I, Second ed. Schmidt Romhild, Lubeck, 1982 pp 303-318.
5. Bhardwaj DN, Dogra TD, Sharma RK. Use of metal detector in postmortem examination. *Jornal of Forensic Medicine and Toxicology, India*. 8 (1991) 19-20.
6. DiMaio VJM : Gunshot wounds, Elsevier, New York, Amsterdom, Oxford 1985 pp 220-222.
7. Michelassi F, Pietrabissa A, Ferrari M, Mosca F, Vargirh T, Moosa HH : Bullet Emboli to the systemic and venous circulation, *Surgery* 107 (1990) 239-45.
8. Patel KR, Cortes LE, Semel L, Sharma PV, Clauss RH : Bullet Embolism. *J. Cardiovasc. Surg*. 30 (1989) 584-590.