ANIL AGGRAWAL'S
Internet Journal of Forensic Medicine and Toxicology
The world's first online journal devoted entirely to forensic medicine and toxicology · Published 1 January and 1 July

VOL. 2, NO. 1
Downloaded from www.anilaggrawal.com · ISSN 0972-8074 (Online) · https://www.anilaggrawal.com/ij/vol_002_no_001/br002_001/page003.html

Book Reviews: Technical Books Section



OTHER REVIEWS IN THIS ISSUE
[Technical Books Section] Pages: |1| 2| 3| 4| 5| 6| 7|
[Popular Books Section] Pages: |1| 2| 3| 4| 5| 6|

REVIEWS IN THE PREVIOUS ISSUE | NEXT ISSUE

Editor's recommendation. This book is recommended by the editor.

A SINE QUA NON FOR PATHOLOGISTS

Post Mortem Technique Handbook, 1st Edition, 2001 *by* Michael T. Sheaff and Deborah J. Hopster Springer-Verlag, GmbH & Co.KG, Tiergartenstrasse 17, D-69121 Heidelberg, Germany. 56 Figures. XII, 308 pages, ISBN 1-85233-132-1. Hardcover $89.00.

When Professor Allan Usher invited me to his excellent Medicolegal Center in Sheffield (way back in 1990), one of the first things I noticed there was a plaque in the mortuary giving a famous dictum by the Italian Anatomist and Pathologist Giovanni Battista Morgagni (1682-1771). It said something like this, "Those who have dissected or inspected many bodies have at least learnt to doubt; while others who are ignorant of anatomy and do not take the trouble to attend it are in no doubt at all." This left a deep impression in my mind (This by the way is an important quote now in my little book of Forensic quotes). More than anything else, this single quote underlines the need to do a detailed postmortem in every case.

Click Cover to buy from Amazon

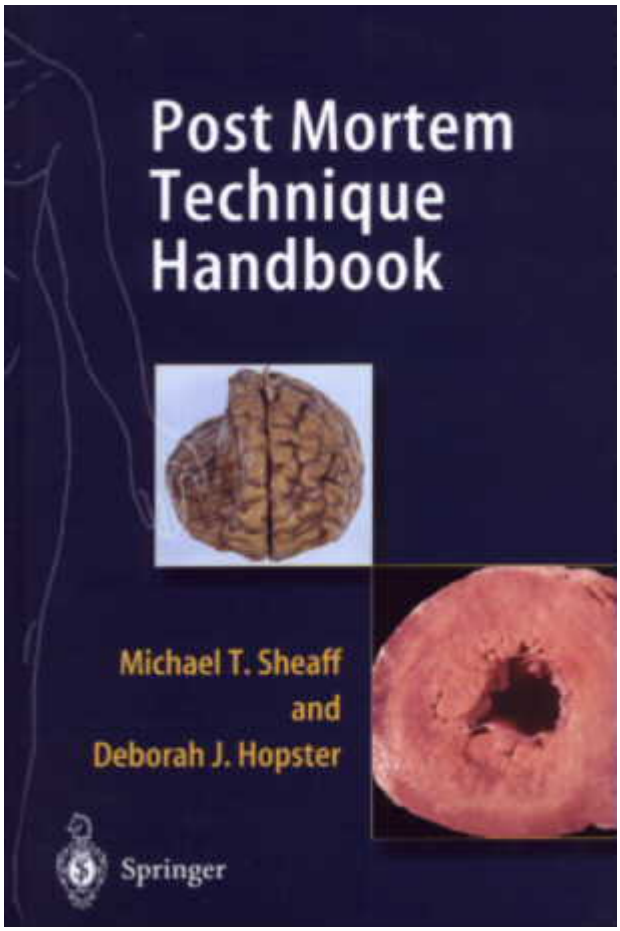

I have always loved doing post-mortems (and thus books on post-mortem techniques). This is in fact one of the major reasons, why I chose this branch for specialization. For the last twenty five years, I have grown on a liberal dose of Otto Saphir's *Autopsy Diagnosis and Technic*, Jürgen Ludwig's *Current Methods of Autopsy Practice* and Pryce and Ross's *Post Mortem Appearances*, and had come to believe that these are the ultimate books on Post-mortem appearances and techniques (I still have in my possession extensive hand-written notes from each of these books as none of these books is in print now). Till the book under review arrived by post one Saturday evening. I got to see it after I returned home from a whirlwind lecture tour. I got curious as books on post-mortem techniques have always intrigued me. As I thumbed through the pages and looked at the contents, I kept getting one surprise after the other. It was not long before I decided this book was a major improvement on all the books I had read till now.

View this book on Amazon

The book is divided in 14 chapters, the first four of which are general in nature. The first chapter tells you about the various legal systems prevalent in various regions, such as coroner system, procurator fiscal system, medical examiner system and so on. There are large sections devoted to consent, health and safety, general aspects/rules of mortuary practice and so on. Infection is the major risk and we are told how to avoid these risks. Pathogens are divided in four categories - Category 1 (such as environmental pathogens, which are most unlikely to cause disease), Category 2 (Such as *Escherischiae coli*), Category 3 (such as Mycobacterium tuberculosis and HIV) and Category 4 (such as agents causing viral hemorrhagic fevers). Steps to handle each of these categories are provided in great detail, with instructions that Category 4 cases must only be done when strictly indicated, and then too in a specialized unit. Useful advice is given at several places. For instance

what do you do, if there is any doubt about any potential risks associated with a perceived hazard? Well, the pathologist should have no hesitation in obtaining advice from other health care workers such as laboratory safety representative, officer or manager.

We have always wondered about how best to handle HIV positive bodies. This chapter tells us that although HIV may remain viable in a dead body for up to 20 hours, there is a relatively less chance to get infected even with penetrating injuries like needle pricks. In fact pathologists are encouraged to conduct postmortems on HIV positive cases in order to document clinicopathologic follow-up and drug efficacy and toxicity.

Perhaps the key feature of this book are the sections on "Special Techniques", which are scattered throughout the book. Many of the special techniques would come as a surprise to you. Most are illustrated with diagrams. For instance, the diagram on the right tells you how to remove the sella turcica "en bloc", especially when you are examining the pituitary gland when a large tumor is present.

How to remove the sella turcica "en bloc"

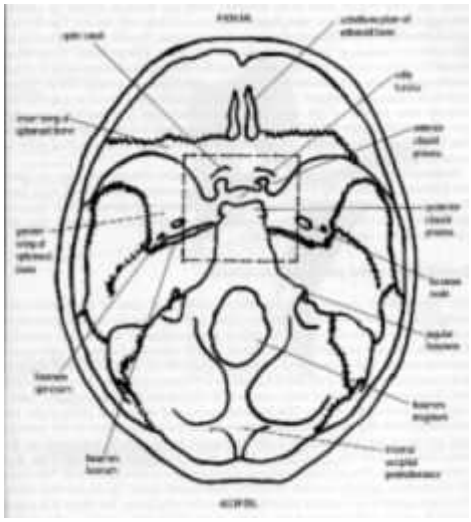

Evisceration techniques and block dissection are described in chapters 2-4, and these really interested me very much. Look up Ludwig, and you will find that it just mentions names such as Rokitansky method, Virchow's method, Letulle's method and Ghon's method. Only a cursory description is given for each method. In Edinburgh (where I imbibed most of my post-mortem techniques), Letulle's technique is followed, and in Maulana Azad Medical College, where I currently teach, Ghon's method is the norm, so I am quite familiar with these two techniques. But I have always wondered what the other two techniques must be like. Unfortunately looking up Ludwig did not help me much. It simply tells us that in one you take out the organs one by one, while in the other you do an in-situ dissection. Details of the techniques are not given. I must confess that for the first time in my life, I had the chance to read a detailed description of Virchow's and Rokitansky technique in this book. The techniques are described in so much detail and so graphically, that if you hold this book in front of you, and start dissecting, quite probably you won't need a teacher. Virchow's technique is described in six pages (from pages 60-65), and Rokitansky in another five (pages 65-69). Since you take out organs one by one in Virchow's technique and do an in-situ dissection in Rokitansky, I had come to believe that these are quite inferior techniques, but after reading the details I discovered how much promise even these so called old-fashioned techniques hold. One of these days, I intend taking this book to my mortuary and attempt dissection by these two "new" techniques. Further on, the book gives complicated techniques, such as how to

examine the middle ear. We have always examined the middle ear by breaking open the petrous temporal, but we are told that we can take out the whole block of bone containing middle and inner ears, decalcify it and then examine it at leisure. The full technique in detail is given.

A diagram of the three tissue blocks to examine the conduction system. Arrows indicate the direction of serial slicing

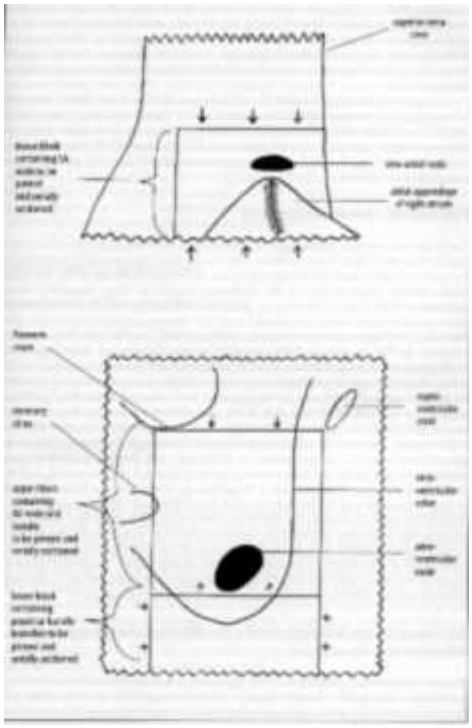

Chapters 5 to 12 were most interesting. They deal with different organ systems (see the contents list at the lower left; and click to enlarge to be able to read the contents). Although these chapters are full of information from beginning to end, the portions that interested me most were the so-called "Special techniques". I was amazed to see some techniques in this book which are rarely mentioned otherwise. For instance I do not know of any book other than Ludwig, that tells us that a nephron or glomerulus can actually be dissected out using a series of sieves. This book does that (on page 149). For the curious, you first macerate the kidney tissue with concentrated Hydrochloric acid, or better still with collagenase and then dissect out the nephrons with a dissecting needle under a binocular dissecting microscope. It is a tough technique and requires lot of experience. To separate the glomeruli free of Bowman's capsules - a procedure often needed for the preparation of antigens - you need to pass the tissue through a series of sieves - 80-mesh stainless steel sieve, 120-mesh wire cloth and 200-mesh sieve. Glomeruli are retained by the 200-mesh sieve. Incidentally the total weight of all the glomeruli collected from one kidney is around 10 mg!

Special techniques related to cardiovascular system that interested me most were examination of heart following coronary artery bypass grafting (CABG), following cardiac pacing, following cardiac transplantation, and examination of conduction system (see figure on the left). These techniques have been described in technical papers, but are generally hard to find in any book. The authors do a commendable job assimilating a lot of such information in book form.

Take the postmortem examination of heart after cardiac pacing for instance. With the increase in the use of cardiac pacemakers, we are likely to encounter more and more dead bodies with pacemakers, and the pathologist must know how best to examine the heart in such cases. Functioning of cardiac pacing may be an associated medicolegal issue, and if the examination is not

done properly, results can be disastrous. Post-mortem radiography is essential in such cases, and these radiographs must be compared with the pre-mortem radiographs. Site of the electrode, the course of the wire and the site of the pacemaker must be noted. Presence or absence of infection is assessed. Many more steps are given, not the least interesting of which is that the pacemaker device should be sent for expert electrical analysis. After you read them, they all sound logical steps, but knowing them beforehand is definitely going to be an advantage.

How do you take microbiological samples in cases of suspected endocarditis. This chapter tells you how. The surface of the relevant chamber is seared with a heated blade and a sterile scalpel and forceps used to open the chamber and obtain the sample. This technique minimizes the risk of contamination which is usually a problem when culturing post mortem tissue.

A paper mounted slice of lung prepared following the Gough-Wentworth technique. This is particularly useful for demonstrating interstitial and obstructive pulmonary disease



We all know how to dissect the lung airways and blood vessels, but how do you inflate the lungs? This technique is described in chapter 6 (among many other interesting techniques). Inflation is necessary to examine lung parenchyma so that an accurate assessment of interstitial disease can be made. Several methods are described. One is the pressure system, in which you use hydrostatic pressure (by keeping a container at a height of about a foot) to instill formaldehyde in the lungs. Second is the Pump system, in which you use a pump and the third is the Formaline vapor method, in which you first plug the main bronchus with a rubber stopper and then pass formaldehyde gas through a needle pierced through it. And how do you prepare formaldehyde gas? The books tells you how. Just fill a large container with 40% formaldehyde solution and bubble air through it! (*This, by the way, is mentioned in Ludwig too, but should be interesting to those who don't have access to this out-of-print book*)

An illustrative table showing causes of direct maternal deaths. This is one of the several illustrative tables appearing in this book (Click to enlarge in a different window)

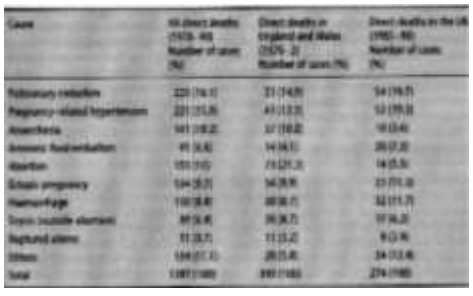

This is all very well, but what do you do when you encounter cases with abundant luminal contents (such as pulmonary oedema or consolidation)? Simple. Just use a pulmonary vessel instead of the bronchus. This allows intraluminal material to be retained in the specimen too!

The chapter goes on to tell more. How do you produce lung slices? How do you produce Gough-Wentworth slices? (see figure above on the left) And what use are they anyway? How do you do diatom test in drowning (this is of special interest to forensic pathologists)? I could go on and on, but perhaps you would like to read the details yourself in the book.

Suppose you encounter a case of Coeliac disease and need to preserve the mucosa of the gastrointestinal tract. What do you do? Problems related to gastrointestinal system pathology are tackled in the next chapter (Chapter 7). For the problem just mentioned we are advised to tie the small bowel both at the duodenal-jejunal junction as well as terminal ileum just proximal to ileocaecal valve. And then introduce formalin in this loop until the bowel is just distended. This is left for several hours and then the mucosa examined. For best results, do this procedure within six hours of death.

Special techniques for liver are also interesting. Take an example. How do you demonstrate hepatic iron in cases such as haemochromatosis? Well, do this. Take a thin slice of liver about 3-4 mm thick and place it in 1-5% potassium ferrocyanide for approximately five minutes. Then transfer the slice to a 2% solution of hydrochloric acid for a further five minutes and then wash in running water for upto 12 hours. Iron is demonstrated by the tissue turning blue due to Perl's Prussian Blue reaction.

Have a look at the contents of the book (Click to enlarge in a different window)

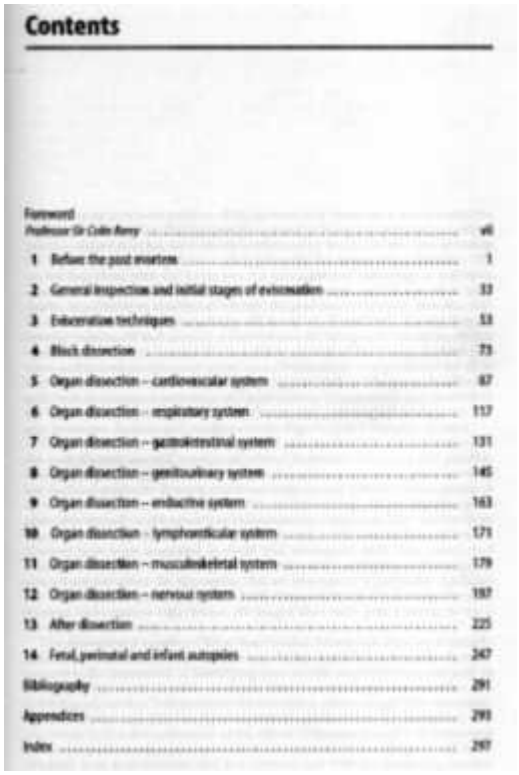

Contents

Foreword
Professor Sir Colin Berry vii
1 Before the post mortem 1
2 General inspection and initial stages of evisceration 33
3 Evisceration techniques 53
4 Block dissection 73
5 Organ dissection – cardiovascular system 87
6 Organ dissection – respiratory system 117
7 Organ dissection – gastrointestinal system 131
8 Organ dissection – genitourinary system 145
9 Organ dissection – endocrine system 163
10 Organ dissection – lymphoreticular system 171
11 Organ dissection – musculoskeletal system 179
12 Organ dissection – nervous system 197
13 After dissection 225
14 Fetal, perinatal and infant autopsies 247
Bibliography 291
Appendices 293
Index 297

There are more such techniques in this chapter. How do you sample hepatic tissue? How do you demonstrate hepatic amyloid? How do you do postmortem hepatic radiography, and why in the first place you need it? And last but not the least, how do you examine liver if it is a case of liver transplantation.

Several other highly interesting techniques (these are hard to find otherwise) are given in this chapter. Among these are radiography of the pancreas and salivary glands, isolation and examination of salivary glands, and demonstration of oesophageal webs, rings and varices. We are told how to fix the coeliac block, how to fix the stomach as a whole and how to do postmortem

angiography of the stomach and mesentery. And how do you demonstrate fat necrosis? Bathe the relevant tissue in concentrated copper acetate solution in an incubator for 24 hours and the tissue must turn blue-green.

Chapter 8 deals with genitourinary system. It is here that I learnt we can actually dissect out a glomerulus or a nephron. But just sample some of the other techniques that this chapter gives us. How do you do the radiography of the urinary tract? How to do renal angiography, and why would you need them in the first place? How do you demonstrate renal amyloid? How do you sample renal tissue for chemical analysis? And how do you examine a transplanted kidney? These and several other interesting issues are detailed in this chapter. I was quite intrigued by the description of the examination of transplanted kidney, as this is something I have never done (I certainly don't remember any, if I have). The transplanted kidney is found located within the pelvis "plumbed into" the iliac vessels. We must examine all anastomoses -either vascular or ureteric-, and check for any intraluminal obstructions. Particular things to look out for are infection, rejection and recurrence of glomerulus or other disease in the new kidney. Another complication which has recently come to light is post-transplant lymphproliferative disorders. This is related to stimulation of lymphoid cells by Epstein-Barr virus. This may manifest as lymphadenopathy, and we must watch out for this.

A neat scheme to show fracture of the ribs

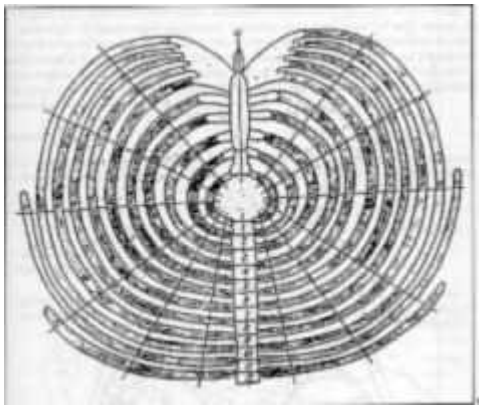

How do you examine a "frozen" pelvis? How do you examine the penile urethra? And for that matter, how do you examine female urethra? How do you do lower tract urinary tract urography? And how do you go about doing post-mortems in maternal deaths? This chapter tells you not just about these, but several other additional things. One interesting table regarding causes of direct maternal deaths is reproduced above and to the right for the benefit of the reader. This is just one of the several highly illustrative tables in this book.

Chapter 9 on endocrine system interested me very much, as this is full of little known techniques. How do you examine the pituitary gland when a large tumor is present? You remove sella turcica "en bloc" (see the second figure from the top. It is on the right side). How to examine the thyroid and parathyroid glands when an infiltrative tumor is present and finally how do you examine paraganglionic system? I found this latter part very intriguing. Extra-adrenal paraganglionic system is divided into three groups: branchiomeric, intravagal and aortosympathetic. I have never given much attention to these structures during my long career and it was interesting to know they must be examined in certain cases. For instance, a significant increase in weight of carotid body indicates chronic hypoxia. And what is the normal weight of a single carotid body? Stumped? Well, this book tells us it is 10 mg (range 2-30 mg)!

These two photographs from the book illustrate how metal guides can be used to section the brain neatly. The book is full of such technqiues

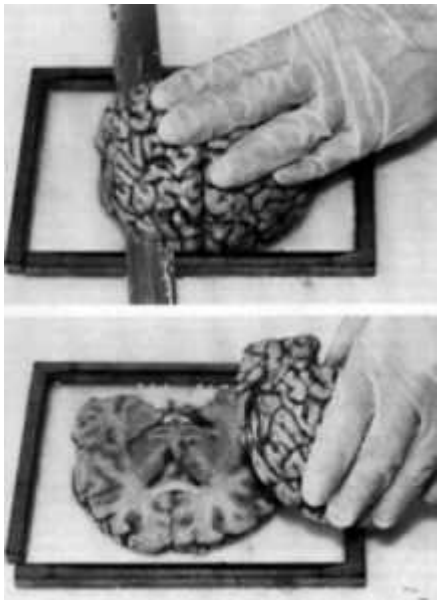

Chapter 10 deals with the examination of lymphoreticular system. It gives us special techniques for lymph nodes such as dissection of nodal disease with perinodal infiltration, how to make lymph node imprints and how to conduct microbiological tests. Special techniques for spleen include microbiology of the spleen and fixing the spleen as a whole. To fix the spleen as a whole, you inject a fixative through the splenic artery at moderate pressure while the splenic vein is clamped. For examining bone marrow, we can resort to three main sites - femur (which is the usual practice), vertebral bodies and rarely sternum. Details are given of the technique to decalcify tissues for bone marrow histology. One of the most common techniques to do this is to immerse the specimen in 5-10% solution of formic acid, and quite interestingly we might have to take serial radiographs to see if the decalcification is complete! But what I liked most in this chapter is the technique to identify thoracic duct. This structure has consistently stumped me, and I have only rarely spotted it. So I was quite keen to read about this technique (I had never seen the technique anywhere else). After I read it, I found it was actually quite a simple fare. All you have to do is lift the left lung forward, transect intercostal arteries in the lower part of the mediastinum, pull the aorta to the right to expose the retroaortic adipose tissue and lo! you get the thoracic duct. Sounds fairly straightforward, and I intend to try it out next time I enter my mortuary.

This diagram illustrates the course of the skin incision to remove the femur



Chapter 11 deals with musculoskeletal system, and among other things we are told, how to remove the femur (see the figure on the right). Among the special techniques we are told how to deal with

fractures, and especially how to document them. One of the figures we have reproduced above shows how to document fractures of the ribs.

How to cut the vertebra when taking out the spinal cord

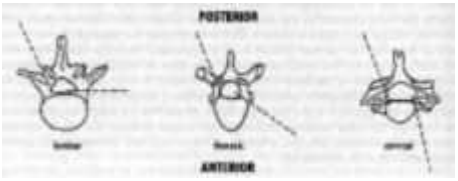

Chapter 12 deals with the nervous system. Many new and interesting techniques are introduced in this chapter too. An interesting technique is how to use metal guides to slice the cerebrum neatly (see figure above on the left). In the section on removal of spinal cord, we are told how the cuts have to be made in the vertebrae. While the angle of cut remains constant in the posterior approach, it increases from an acute angle (at the cervical region) to almost a right angle (at the lumbar region). A quite illustrative diagram explains the cuts (we have reproduced it on the left for the benefit of the reader).

I am tempted to go on and on. But however much I describe this book, I can not do full justice to it. The best course is of course to acquire a copy and read it from first to the last page - as I have done. If you are a practicing pathologist, you will find life different after reading this book. I certainly have learnt a lot from this book, and certainly my life is going to be different. I can now do so many more new things, that I was simply unaware of till now. The book is chock-full of information on post-mortem techniques. It is available for $89.00, but if it were available for twice that price, I would buy it any day.

Order *Post Mortem Technique Handbook* at a discount through this online journal by Clicking here

Order other books on autopsy from amazon at a discount through this online journal by Clicking here

Request a PDF file of this review by clicking here. (If your screen resolution can not be increased, or if printing this page is giving you problems like overlapping of graphics and/or tables etc, you can take a proper printout from a pdf file. You will need an Acrobat Reader though.)